

Effectiveness of Allogeneic Bone Block Grafts in Maxillary Ridge Reconstruction: A Systematic Review

Sophie Bauer^{1*}, Felix Becker¹, Julia Hartmann¹, Marie Hartmann¹

¹Department of Periodontology and Oral Implantology, School of Medicine and Dentistry, Erasmus University Rotterdam, Rotterdam, Switzerland.

*E-mail ✉ sbauerbiofilm@outlook.com

Received: 05 May 2023; Revised: 28 September 2023; Accepted: 28 September 2023

ABSTRACT

The purpose of this systematic review was to assess the efficiency of allogeneic bone block grafts for maxillary alveolar ridge reconstruction. An electronic literature search was conducted using the PubMed, Cochrane Library, and Google Scholar databases. In addition, manual searching was done. Randomized controlled trials (RCTs) and prospective clinical trials (non-RCTs) up to December 2022, presenting the outcomes of allogeneic bone blocks in maxillary alveolar ridge reconstruction, were identified. The rate of resorption, survival rate of implants, and formation of new bone following ridge augmentation were the outcome parameters. The quality assessment of the studies included was done using Joanna Briggs Institute Critical Appraisal Tool. A total of 13 studies that matched the inclusion criteria were included. The average rate of bone resorption ranged from 0.2 to 29.2 mm, with an implant survival rate of 96.87% across the included investigations. On an average, 25.83 mm (18.6–33/mm) of new mature compact osseous tissue was discovered, including viable osteocytes in close contact with the remnant cancellous bone. According to the results of the current systematic review, using allogeneic bone block graft for reconstruction of atrophic maxillae appears to be an effective and reliable bone substitute for reconstruction of atrophic maxillae.

Keywords: Allogeneic bone block grafts, Maxillary alveolar ridge, Reconstruction, Systematic review

How to Cite This Article: Bauer S, Becker F, Hartmann J, Hartmann M. Effectiveness of Allogeneic Bone Block Grafts in Maxillary Ridge Reconstruction: A Systematic Review. *J Orthod Periodontal Biomater Res.* 2023;3(2):48-61. <https://doi.org/10.51847/0Xm3HLNjom>

Introduction

Ridge augmentation is a common procedure used for reconstructing atrophic alveolar ridges, and it has been used in clinical practice for more than 50 years. It is a surgical procedure aiming to add volume to the receding alveolar bone. The selection of graft for reconstruction is highly dependent on a number of factors such as age, amount and type of available bone, and location of the jaw defect. Ideally, grafting material for ridge augmentation should possess easy handling characteristics, should be biocompatible allowing proper fusion of the graft, and provide an osteoconductive scaffold for osteogenic cells so as to facilitate remodeling [1]. The atrophic alveolar ridge in the maxillary region presents a greater challenge because it lacks a natural cavity to retain the particulate grafting material, as observed in the sinuses [2]. Alveolar bone resorption might be vertical or horizontal, or can be a combination of both deficiencies. According to reports, the loss of the width of the alveolar ridge is 43% greater than the loss of height clinically. Due to variations in bone density, placement of implants in the maxilla becomes more critical than the mandible because of the greater chances of failure of implants, which is further complicated by the respective prosthetic challenges [3]. As a result, the graft must be strong and rigid enough to be fixed in the recipient site, as well as be three dimensionally stable enough to bear muscle pressures. As a result, if the needed augmentation exceeds 3 mm in width or height, a block graft in the anterior maxilla is indicated [4]. With

regard to the aforementioned criteria, bone block allografts have been shown to be preferable over other grafting materials.

In 1880, a Scottish surgeon successfully repaired a 4-year-old boy's diseased humerus using a graft derived from the tibia of a youngster with rickets, performing the first regenerative treatment using bone allograft [5]. For bone grafting procedures, the allogenic bone block grafts use bone tissue obtained from a donor of the same species but not the recipients. Allografts encourage bone formation by including osteoinductive growth factors and osteoconduction [6]. The allogenic bone tissue is typically obtained from cadavers, and undergoes a series of processing steps to minimize the risk of immune rejection and infection. This method provides various advantages over standard autogenous bone grafting, including less morbidity at the donor site, lower surgical time, and availability of large quantities of bone tissue [7]. However, using allogenic bone block grafts has also raised concerns about immune reactions, infectious disease transmission, and suboptimal integration of the graft with the host tissue. Thus, there are stringent sterilization and decontamination standards for these materials. To minimize risks, donors are thoroughly screened and graft materials are treated progressively [8].

A bone block allograft is made up of cancellous or corticocancellous bone that has been removed from a cadaver through harvesting, processed and then placed at the recipient site in the patient's body. Fresh-frozen bone, freeze-dried bone, demineralized freeze-dried bone, and deproteinized bone allografts are the four forms of allografts discussed. The phrases demineralized freeze-dried bone allografts (FDBA) and FDBA are widely used. To boost the potential for osteoinduction, the graft is demineralized with hydrochloric acid to facilitate easier access to growth hormones like bone morphogenetic proteins.

To our knowledge, there is limited evidence gathered and analyzed to determine the efficacy of allogenic block grafts in the augmentation of atrophic maxilla. The present systematic review aimed to evaluate the efficacy of allogenic block grafts in the reconstruction of atrophic maxillary alveolar ridges by means of clinical and histological findings.

Materials and Methods

The investigation question was designed as per the laid down guidelines for systematic review and was: "Do patients exhibiting atrophic maxillary ridges indicated for placement of dental implants, when subjected to bone augmentation using allogenic block graft, exhibit any difference in outcomes about new bone formation, resorption rate, and implant survival?"

One of the investigators (AP) searched various databases, including MEDLINE, EMBASE, the Cochrane Central Register of Controlled Trials, and the Cochrane Oral Health Group Trials Register, for all the papers written in the English language. The investigation question was followed. The Preferred Reporting Items for Systematic Review and Meta-Analysis statement and guidelines[9] and the "*Cochrane Handbook for Systematic Reviews of Interventions*." [10] were adhered to report this Systematic Review. The protocol was registered with "PROSPERO, the International Prospective Register of Systematic Reviews."

To make sure that all research papers including an allogenic block graft for maxillary alveolar ridge reconstruction were included, the following search terms were selected in conjunction and independently: ("allogenic bone block graft" [MeSH Terms] OR "block allograft" OR "block graft" [All fields]) AND ("maxillary ridge reconstruction" [All fields] OR "maxillary alveolar ridge reconstruction" [All fields] OR "maxillary alveolar ridge augmentation" [All fields] OR "maxillary ridge augmentation" [All fields]) AND ("randomized clinical trial" [All fields] OR "randomized controlled trial" [All fields] OR "prospective clinical trial" [All Fields] AND "histological study" [All Fields] OR "histomorphometric study" [All Fields] OR "histomorphometrical investigation" [All Fields]).

Certain articles were discovered by manual searching, and bibliographies of these papers were established. Three reviewers (AP, RK, and AK) independently assessed the publications, using titles and abstracts as inclusion and exclusion criteria. Full-text papers were also downloaded and examined to identify research with potential relevance. In addition, thorough text evaluation was considered for articles with ambiguous results. Cross-reference lists of selected trials and studies that met the inclusion criteria were thoroughly reviewed. Any disagreements with the study were settled by the fourth reviewer (VL).

Based on the following inclusion criteria, relevant studies were selected:

Scientific papers in the English language, prospective human clinical trials, no history of systemic disorders, and human studies with no limits on the number of patients involved. Studies that were published till December 2022 and reporting data on outcomes of allogenic bone block grafting on the atrophic maxillary alveolar ridge,

histological findings, and survival rates. The primary outcome variable considered was the resorption rate. The secondary outcome variables were implant survival rate, number of failed implants, number of failed blocks, and amount of new bone formation.

Studies with <6 months follow-up period, literature reviews, narrative reviews, case series, books, reports, letters to the editor, animal studies, studies with incomplete data, research populations, or study duration that did not meet the eligibility criteria were omitted.

Two examiners (AP, RK) extracted data separately for inclusion and scrutinized the same. The relevant information was collated and summarized as follows: author and year of the study, sample size, mean age, kind of allogenic block grafting, parameters such as reduction in bone volume/resorption rate, implant survival rate, block graft survival, newly formed bone, block graft complications evaluated after a minimum period of at least 6 months follow-up were considered.

The quality assessment of individual studies was conducted by two reviewers (AP and AK). The Joanna Briggs Institute Critical Appraisal Tool (JBI) Tool [11, 12] was used for the Quality Assessment of the included studies [2, 13-24]. Of the two randomized controlled trials (RCTs) [13, 14] included in the review, one study was of high quality and the other was of moderate quality. Of the 11 quasi-experimental studies included in the review,[2, 15-24] three studies were of high quality and the remaining eight were of moderate quality (Table 1 and Figures 1, 2).

Table 1: Quality assessment of the included studies using joanna briggs institute (JBI) tool

For Randomised Controlled Trials															
Study	Was true randomization used for assignment of participants to treatment Was allocation to treatment groups concealed? Were treatment groups similar at the baseline? Were participants blind to treatment assignment? Were those delivering treatment blind to treatment assignment? Were outcomes assessors blind to treatment assignment? Were treatment groups treated identically other than the intervention of interest? Was follow up complete and if not, were differences between groups in terms of their follow up adequately described and analyzed? Were participants analyzed in the groups to which they were randomized? Were outcomes measured in the same way for treatment groups? Were outcomes measured in a reliable way? Was appropriate statistical analysis used? Was the trial design appropriate, and any deviations from the standard RCT design (individual randomization, parallel groups) accounted for in the conduct and analysis of the trial?												Score	Quality assessment	
Deluiz D et al. 2017[13]	Yes	No	Yes	Unclear	Unclear	Unclear	Yes	Yes	Yes	Yes	Yes	Yes	Yes	9/13=0.69	Moderate
G F Tresguerres F et al. 2019[14]	Yes	No	Yes	Yes	Unclear	Unclear	Yes	Yes	Yes	Yes	Yes	Yes	Yes	10/13=0.77	High
For Quasi experimental studies															

Study	Is it clear in the study what is the “ cause” and what is the “ effect” (i.e. there is no confusion about which variable comes first)?		Was there a control group?	Were participants included in any comparisons similar?	Were the participants included in any comparisons receiving similar treatment/care, other than the exposure or intervention of interest?	Were there multiple measurements of the outcome, both pre and post the intervention/exposure?	Were the outcomes of participants included in any comparisons measured in the same way?	Were outcomes measured in a reliable way?	Was follow-up complete and if not, were differences between groups in terms of their follow-up adequately described and analyzed?	Was appropriate statistical analysis used?	Score	Quality assessment
Contar CM <i>et al.</i> 2009[2]	Yes	No	No	NA	Unclear	NA	Yes	Yes	No	5/9=0.55	Moderate	
Barone A <i>et al.</i> 2009[15]	Yes	No	No	NA	Unclear	NA	Yes	Yes	No	5/9=0.55	Moderate	
Chaushu G <i>et al.</i> 2009[16]	Yes	No	No	NA	Unclear	NA	Yes	Yes	No	5/9=0.55	Moderate	
Chaushu G <i>et al.</i> 2010[17]	Yes	No	No	NA	Unclear	NA	Yes	Yes	Yes	6/9=0.67	Moderate	
Nissan J <i>et al.</i> 2011[18]	Yes	No	No	NA	Unclear	NA	Yes	Yes	No	5/9=0.55	Moderate	
Acocella <i>et al.</i> 2012[19]	Yes	No	No	NA	Unclear	NA	Yes	Yes	Yes	6/9=0.67	Moderate	
Krasny M <i>et al.</i> 2015[20]	Yes	No	Yes	Yes	Yes	Yes	Yes	Yes	No	7/9=0.78	High	
Deluiz D <i>et al.</i> 2016[21]	Yes	No	No	NA	Unclear	NA	Yes	Yes	Yes	6/9=0.67	Moderate	
Ahmadi RS <i>et al.</i> 2017[22]	Yes	No	Yes	Yes	Yes	Yes	Yes	Yes	Yes	8/9=0.89	High	
Lorenz J <i>et al.</i> 2018[23]	Yes	No	No	NA	Unclear	NA	Yes	Yes	Yes	6/9=0.67	Moderate	
Krasny K <i>et al.</i> 2018[24]	Yes	No	Yes	Yes	Yes	Yes	Yes	Yes	No	7/9=0.78	High	

NA – Not available

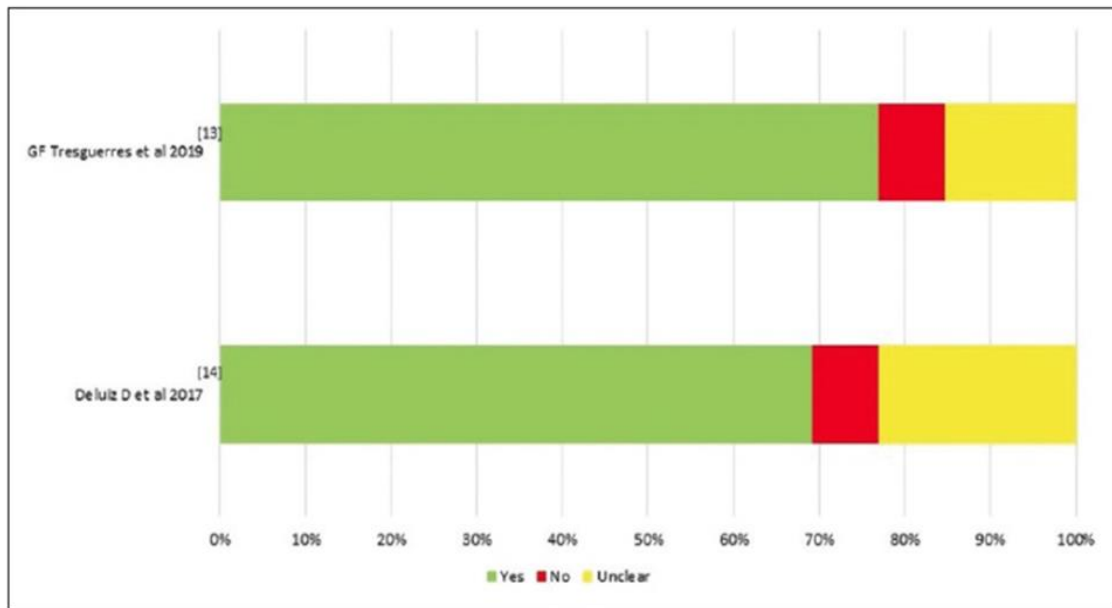


Figure 1: Quality assessment of the randomized controlled trials using Joanna Briggs Institute tool

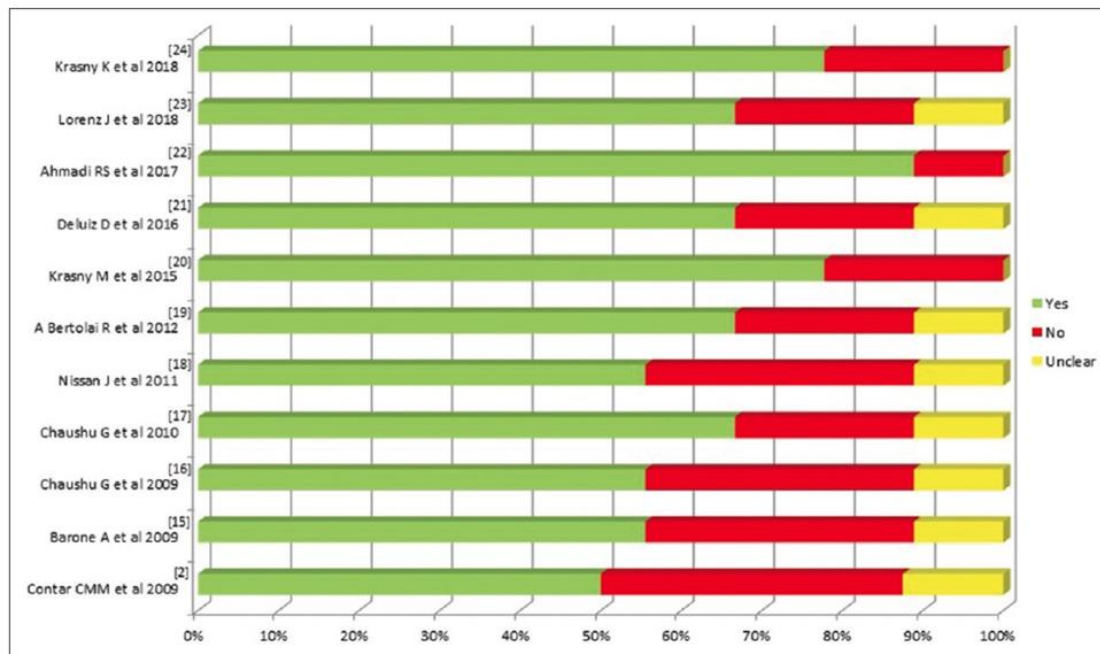


Figure 2: Quality assessment of the quasi-experimental studies using Joanna Briggs Institute tool [12]

Results and Discussion

Following this analysis, 13 studies were finally included in this review (**Figure 3**). The current systematic review was executed to analyze the outcomes of allogeneic bone block grafting on the survival of implants and new bone formation. The screening process was undertaken in three steps that included title screening first, then the abstracts, and finally, the complete text was screened for inclusion in the review. The characteristics of the studies included in the systematic review are presented in the tables.

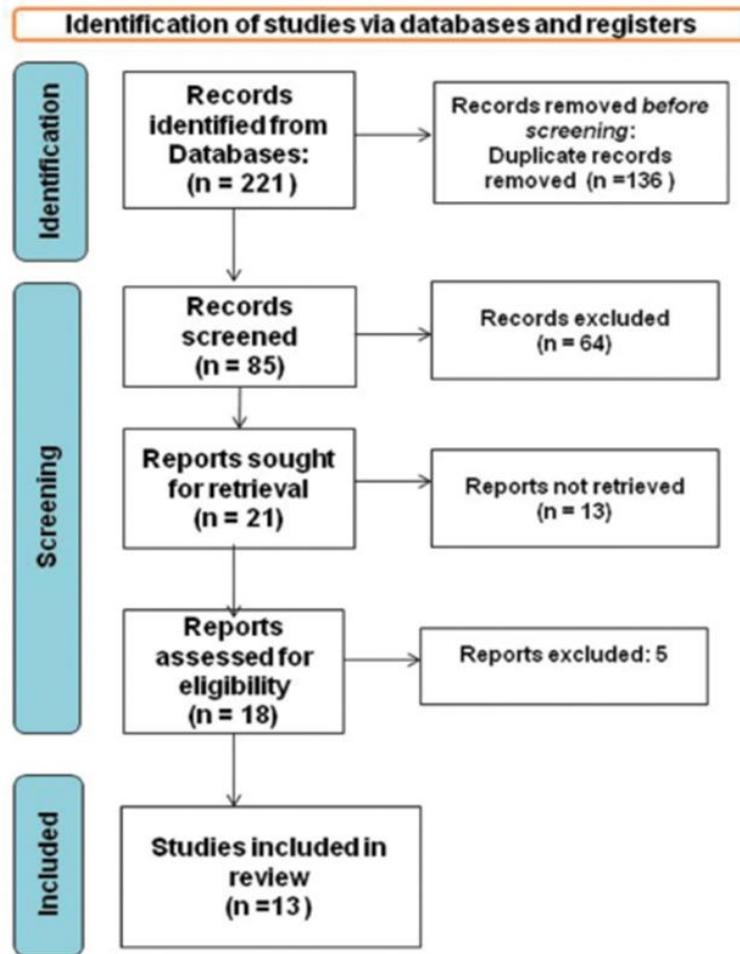


Figure 3: Identification and screening of included studies according to Preferred Reporting Items for Systematic Reviews and Meta-Analyses: Flow diagram. n - number

Table 2 demonstrates the 13 studies [2, 13-24] that were included based on the predefined inclusion criteria. All studies compared and assessed the outcomes of block grafting on the survival and bone formation around the implants. With respect to publication year, the studies ranged from 2009 to 2019. It can be observed that there exists a literature gap in the reporting of long-term result studies on block grafting, indicating that longitudinal evidence is still sparse. Regarding study design, seven studies were of nonrandomized design, while another six studies were randomized controlled clinical trials.

Table 2: Details of the studies included in the systematic review

Study Id/ Ref. No.)	Title	Authors name	Year of publication	Study design
2	Maxillary ridge augmentation with fresh-frozen bone allografts	Contar <i>et al.</i> [2]	2009	Non-RCT
13	Incorporation and remodeling of bone block allografts in the maxillary	Deluiz <i>et al.</i> [13]	2016	RCT
14	reconstruction: A randomized clinical trial Clinical and radiographic outcomes of allogenic block grafts for maxillary lateral	Tresguerres	2019	RCT
15	ridge augmentation: A randomized clinical trial Deep-Frozen Allogenic Onlay Bone Grafts for Reconstruction of atrophic	<i>et al.</i> [14] Barone <i>et al.</i> [15]	2009	Non-RCT
16	maxillary alveolar ridges: A preliminary study The use of cancellous block allograft for sinus floor augmentation with	Chaushu <i>et al.</i> [16]	2009	Non- RCT

17	simultaneous implant placement in the posterior atrophic maxilla Histomorphometric analysis after maxillary sinus floor augmentation using	Chaushu <i>et al.</i> [17]	2010	Non- RCT
18	cancellous bone–block allograft Cancellous bone block allografts for the augmentation of the anterior atrophic	Nissan <i>et al.</i> [18]	2011	Non- RCT
19	maxilla Maxillary alveolar ridge reconstruction with monocortical fresh-frozen bone	Acocella <i>et al.</i> [19]	2012	Choice
20	blocks: A clinical, histological and histomorphometric study Long-term outcomes of the use of allogenic, radiation sterilized bone blocks in	Krasny <i>et al.</i> [20]	2015	randomizati on Non-RCT
21	reconstruction of the atrophied alveolar ridge in the maxilla and mandible Fresh-frozen bone allografts in maxillary alveolar augmentation: Analysis of	Deluiz <i>et al.</i> [21]	2016	Non- RCT
22	complications, adverse outcomes, and implant survival Clinical and Histomorphometric assessment of lateral alveolar ridge	Ahmadi <i>et al.</i> [22]	2017	Non-RCT
23	augmentation using a corticocancellous freeze-dried allograft bone block Allogenic bone block for challenging augmentation—A clinical, histological, and	Lorenz <i>et al.</i> [23]	2018	Non- RCT
24	histomorphometrical investigation of tissue reaction and new bone formation Allogenic bone block volume preservation in ridge augmentation for implants	Krasny <i>et al.</i> [24]	2018	Non RCT

RCT – Randomised controlled trial.

Different bone grafts were employed across the papers that were included in this review. To mention, they were fresh-frozen bone graft, deep-frozen allogenic bone graft, cancellous allograft, monocortical fresh-frozen bone, allogenic bone, radiation sterilized bone, and corticocancellous freeze-dried allograft. In these studies, all the block allografts were utilized in the maxilla with the indication for augmentation of the atrophic maxillary ridge in either the anterior or posterior region.

Table 3 represents study characteristics with respect to sample and intervention. The total sample size across the included studies was 448, ranging from 10 cases to 117 cases. Majority of the cases were operated on the maxilla, with only a few being on the mandible. The grafts across the studies were grafted on 594 sites, with the least reported to be 24 in a study and the highest being 141 sites. With respect to ridge augmentation, seven studies reported details on whether the augmentation was vertical or horizontal, among which the majority were done for horizontal ridge augmentation. In the included studies, 1244 implants were implanted in the maxilla and mandibular regions, and all patients were followed for 6–96 months to measure implant survival and new bone growth.

Table 3: Details of the study participants and intervention of the included studies

Study Id/Ref. No.	Authors name	No. of patients	Maxilla	No. of sites grafted/no. of blocks grafted	Alveolar ridge augmentation (Horizontal/Vertical/ Both)	No. of implants	Follow-up (months)
2	Contar <i>et al.</i> [2]	15	Maxilla	34	NR	51	24-35

13	Deluiz <i>et al.</i> [13]	66 patients (52 female and 14 male)	Maxilla	113	NR	305	12
14	Tresguerres <i>et al.</i> [14]	117 (79 females and 38 males)	NR	141 (92 maxilla and 18 mandible)	88 Horizontal, 7 Vertical and 26 both	183	6 to 96 months
15	Barone <i>et al.</i> [15]	13 patients (3 male and 10 female)	Anterior maxilla (13) & posterior maxilla (9)	24	5 vertical and 19 horizontal	38	6
16	Chaushu <i>et al.</i> [16]	28 (13 females and 15 males)	Posterior maxilla	NR	Vertical	72	27 months (11-44)
17	Chaushu <i>et al.</i> [17]	31 (16 female and 15 male)	Posterior maxilla	NR	Vertical	76	9
18	Nissan <i>et al.</i> [18]	31 (20 females and 11 males)	Anterior Maxilla	46	42 horizontal, 27 vertical (9% vertical, 40% horizontal and 51% both)	63	6-59
19	Acocella <i>et al.</i> [19]	16 (11 males and 5 females)	Maxilla	18	NR	34	18-30
20	Krasny <i>et al.</i> [20]	21 (15 females and 6 males)	19 maxilla and 7 mandible	26	NR	33	28-50 (39)
21	Deluiz <i>et al.</i> [21]	58 (15 males and 43 females)	22 posterior maxilla, 19 anterior maxilla, and 17 full-arch	92	NR	268	16
22	Ahmadi <i>et al.</i> [22]	10 (3 female, 7 male);	NR	NR	Horizontal	NR	12-18
23	Lorenz <i>et al.</i> [23]	14 (9 female and 5 male)	NR	14	4 horizontal and	28	6
24	Krasny <i>et al.</i> [24]	28 (14 each)	NR	37 c and 49 cc	NR	93 [39 c and 53 cc]	24

NR- Not reported in the study

Table 4 summarizes the outcomes of allogeneic block graft in the atrophic maxilla in the trials considered for this review. The success outcomes of the block graft were reported in the form of resorption rate, implant survival rate, number of failed implants, number of failed blocks, and amount of new bone formation. However, not all the studies reported on all these parameters, but care was taken to include the studies that reported on more than two of the above parameters.

Table 4: Details regarding the outcomes, post block grafting in the included studies

Study Id/Ref. No.	Authors name	Resorption rate	Implant survival rate in %	No. of failed implants	No. of failed blocks	New bone formation
-------------------	--------------	-----------------	----------------------------	------------------------	----------------------	--------------------

2	Contar <i>et al.</i> [2]	NR	94.4	0.0	NR	Mature compact osseous tissue surrounded by marrow spaces. Viable bone was observed as well as newly formed bone
13	Deluiz <i>et al.</i> [13]	The mean resorption rate in Group 1 (13.98%± 65.59) was significantly lower than Group 2	94.6	16	NR	incorporated with the grafted areas. NR
14	Tresguerres <i>et al.</i> [14]	(31.52%±66.31). 20.06±1.43mm	98.4	96.70%	NR	NR
15	Barone <i>et al.</i> [15]	NR	94.74	2	2	NR
16	Chaushu <i>et al.</i> [16]	NR	94.4	4	NR	NR
17	Chaushu <i>et al.</i> [17]	NR	94.7	4	NR	Newly formed vital bone, residual cancellous bone–block allograft, and connective tissue were observed in all augmented sinuses. The residual cancellous bone–block allograft was identified by the presence of empty lacunae and separation lines. Newly formed bone that contained viable osteocytes

						demonstrated intimate contact with the residual cancellous bone. NR
18	Nissan <i>et al.</i> [18]	Mean buccal bone resorption was 0-1mm, mean 0.5±0.5 mm at implant placement, and 0.2±0.2 mm at second-stage surgery.	98%	NR	2	NR
19	Acocella <i>et al.</i> [19]	11.45±8.37	100	0	NR	NR
20	Krasny <i>et al.</i> [20]	NR	NR	NR	NR	NR
21	Deluiz <i>et al.</i> [21]	NR	NR	NR	NR	NR
22	Ahmadi <i>et al.</i> [22]	1.62±0.75mm at 2mm from the crest and -1.95±0.55mm at 5mm	NR	NR	NR	33.0±11.35
23	Lorenz <i>et al.</i> [23]	from crest NR	NR	NR	NR	18.65±12.20
24	Krasny <i>et al.</i> [24]	Higher bone resorption rate was found with cancellous bone grafts (29.2% ± 2.6) compared with corticocancellous grafts. 0.2±0.45 mm (range 0-2.2) at 1 year and 0.5±0.8 mm (range 0-3.1) at 2 years. While in the cancellous group was 0.3±0.65 (range 0-2.6) at 1 year and 0.7±1.0 mm (range 0-3.4) at 2 years.	100	NR	NR	NR

NR- Not reported in the study

Primary outcome variable analysis

Resorption rate or decrease in bone volume after placement of the block graft was reported in five studies, [13-14, 18-19, 22, 24] with the resorption rate in the average range of 0.2–29.2 mm across the various studies that were included. A study by Nissan *et al.* reported buccal bone resorption in the range of 0–1 mm, wherein 0.5 ± 0.5 mm of resorption occurred after the placement of implants and 0.2 ± 0.2 mm after second-stage surgery [18]. A greater bone resorption rate was reported in a study by Krasny *et al.* where the authors reported a resorption rate of 0.2 ± 0.45 mm in the corticocancellous graft and 0.3 ± 0.65 mm in the cancellous grafts at the end of 1 year. The rate increased to 0.5 ± 0.8 mm and 0.7 ± 1.0 mm at 2 years for corticocancellous grafts and cancellous grafts, respectively [24]. Deluiz *et al.* reported a resorption rate in percentage ranging from 13.98% to 31.52% in the two groups included in the study, [13] while Acocella *et al.* reported a mean rate of resorption of 11.45% ± 8.37% [19].

Secondary outcome variable analysis

The implant survival rate after block grafting was reported in nine studies. On an average, the implant survival rate across the studies was 96.87%, with the lowest survival rate of 94.4% and the highest of 100%, while 26 implants failed in all included studies. Only in two studies the implants survived without any complications [19,24] These studies used monocortical fresh-frozen bone blocks and allogeneic bone blocks for the reconstruction of the maxilla. Overall, all the studies reported a good implant survival rate of more than 90%. The failure of the block was also reported across two studies, which were presented as one of the reasons for implant failure. A total of four block grafts failed in two studies [15,18]

Only four studies out of all the studies included reported the details regarding the formation and the characteristics of new bone. The formation of new bone across the studies was around 25.83 mm, ranging from 18.65 mm to 33 mm [22,23] Contar *et al.* in 2009 reported that histological analysis of grafted sites shows mature and dense

osseous tissue formation surrounded by marrow spaces. The viable bone was observed as well as newly formed bone incorporated with the grafted areas was presented radiographically [2]. Another study by Chashu *et al.* reported that there was the presence of vital bone, cancellous bone block allograft residue, and connective tissues in the maxillary sinuses that were augmented with block graft [17]. Further, histological analysis revealed that the new bone contained viable osteocytes and was present in close contact with the residual cancellous bone.

Allogenic bone block grafts are utilized in maxillary alveolar ridge repair to increase the quantity of bone tissue available for implant placement while also improving the stability and longevity of dental implants [19]. The maxillary alveolar ridge has lesser bone density, which is needed to obtain primary implant stability [25]. As there is an absence of a natural scaffold in the anterior maxillary region to contain the particulate graft, the graft must have adequate strength and rigidity to anchor at the recipient site and stability to endure the muscular forces [12]. Moreover, occlusal loading by the final prosthesis without precise biomechanics can contribute to biological or mechanical difficulties [26]. Forces exerted along the axis of the implant are disseminated around it, leading to considerable load on the peripheral supporting bone, particularly in the molar-premolar area. For the anterior maxillary region, significant stresses are applied in the transverse direction, leading to an increase in bending momentum, which may be detrimental to the implant as well as the supporting tissues [27]. Therefore, maxillary ridge augmentation is comparatively challenging to augment compared to the mandibular ridge.

The allogenic bone tissue is typically obtained from cadavers, and undergoes a series of processing steps to minimize the risk of immune rejection and infection. This approach has several benefits over traditional grafting with autogenous bone, like reduced morbidity at the donor site, lower surgical time, and availability of large quantities of bone tissue [7]. However, bone allografts need to be checked for antigenicity. Some studies have discussed the long-term results of the use of fresh-frozen allografts. In a long-span study of 30 years, Virolainen *et al.* found no considerable allergic responses, graft rejection, and unpredicted antibodies following the bone augmentation with an allograft [28]. Histology and evaluation of immune response did not reveal any evidence of antigenic reactions to the fresh frozen allograft used in the rehabilitation of major bony defects [29]. Along with the rate of resorption, Nissan *et al.* reported the gain in bone dimensions obtained following augmentation [18]. Allogenic block grafts led to vertical bone gain of 2 ± 0.5 mm (0–3 mm) and horizontal bone gain of 5 ± 0.5 mm (4–6 mm) after implant insertion. This can confirm that allogenic bone blocks continue to remain constant and stable throughout the study period.

The most noteworthy point was the evaluation of the variety of block allografts used alone without combination for alveolar ridge reconstruction in the maxilla, in conjunction with histologic or histomorphometric analysis of the approach. Acocella *et al.* through histologic examination, reported a large number of empty osteocyte lacunae and nonvital bone around the freshly formed bone following a 9-month healing period [19]. Contar *et al.* described a lamellar configuration with osteocytes scattered in lacunae around Haversian canals [2]. Moreover, in the center of the block bone graft, osteocytes were seen along with a large number of vacant lacunae. Spin-Neto *et al.* discovered large dimensions of necrotic bone and empty lacunae with no osteoclastic activity in the allogenic bone block, as well as blood vessels infiltrating the material's haversian canals with no direct contact between remodeled and transplanted bone [30].

The creeping substitution mechanism appears to be different in cancellous and cortical bone. Integration of the cancellous graft is a rapid process due to its fast revascularization. The invading blood vessels carry osteoprogenitor cells that can differentiate into osteoblasts, leading to the formation of new bone around the necrotic trabeculae. Cortical graft integration occurs slowly because of its impenetrable design. Following osteoclast expansion of Haversian and Volkmann's canals, vascular tissue must invade them, limiting blood vessel penetration towards these preexisting channels; the initial vessels do not enter through the graft until 1 week later. The full revascularization process might take months and is typically incomplete. Finally, osteoblasts are transferred to the widened canal spaces, where they produce new bone. The process of integration of corticocancellous grafts incorporates the features of these two components [31].

Lumetti *et al.* found comparable differences between allogenic and autogenous blocks. An adequate density of the acquired bone tissue in the region of allograft was achieved; thus, this approach could provide an alternative to autografts [32]. The cancellous layer allows for close contact with the original bone, and its compressibility boosts the graft's density, resulting in more effective osteoconduction and vascularization. In addition, the cortical layer provides adequate resistance to pressures impacting the face skeleton and acts as a dense barrier against resorption during the early stages of recovery. Thus, the combination of these two layers enhances graft integration while shielding it from fast resorption throughout the healing process. Kloss *et al.* [7] conducted a study to

compare three-dimensional alterations following the use of autogenous versus allogeneic onlay grafts for augmentation of alveolar ridge defects and found that the vertical and horizontal dimensions did not significantly differ between autogenous and allogeneic bone grafts at any time point. In addition, there were no statistically significant differences in graft remodeling rates between autogenous and allogeneic onlay grafts. In addition, da Costa *et al.* used allogeneic block graft in freeze-dried and fresh-frozen forms, and found that fresh-frozen forms were better with respect to bone regeneration [33].

In summary, this comprehensive analysis demonstrated that independent of subtype, allogeneic bone block grafts are a viable option in augmenting the atrophic maxilla despite the high heterogeneity found among these studies. Although it appears that the rate of resorption, survival, and problems related to allogeneic bone blocks were tolerable, the investigations were lacking in standardization. Additionally, it is still not evident which type of allogeneic block graft offers the most reliable bone gain and host-bone interaction due to the heterogeneity in study designs. Despite positive results for allogeneic bone blocks in terms of the integration between the bone blocks and implants, new bone formation, survival rate, and related comorbidities, there are insufficient high-quality trials to draw very reliable conclusions. Many unknowns must be clarified in future studies. Extensive randomized clinical research comparing the long-term fate of allogeneic bone block grafts should be planned from a clinical standpoint. Limitations of this systematic review were that when analyzing the results, different methods of evaluation used in the trials were not standardized, and there were obvious intrinsic discrepancies in the clinical settings investigated. Despite the thorough methodology employed for finding each article, it is possible that some gray literature was overlooked. Due to a limited number of high-quality RCTs, certain prospective clinical trials were also considered for this systematic review to broaden the inclusion criteria, which may be considered a limitation. Considering all the outcome parameters, it is evident that the allogeneic bone block grafting procedures contribute substantially toward the survival of implants with evident new bone formation, and thus, this technique is of great importance in implant dentistry for patients with atrophic maxilla.

Conclusion

Within the confines of the current systematic review, it can be concluded that allogeneic bone block grafts exhibit promising results for maxillary alveolar ridge reconstruction. High survival rates, low rates of complication, and the longevity of dental implants in these grafted sites make it a good option for augmenting severely atrophic alveolar ridges.

Acknowledgments: None

Conflict of interest: None

Financial support: None

Ethics statement: None

References

1. Aslan E, Gultekin A, Karabuda C, Mortellaro C, Olgac V, Mijiritsky E. Clinical, histological, and histomorphometric evaluation of demineralized freeze-dried cortical block allografts for alveolar ridge augmentation. *J Craniofac Surg.* 2016;27(5):1181–6.
2. Contar CM, Sarot JR, Bordini JJ, Galvão GH, Nicolau GV, Machado MA. Maxillary ridge augmentation with fresh-frozen bone allografts. *J Oral Maxillofac Surg.* 2009;67(6):1280–5.
3. Schropp L, Wenzel A, Kostopoulos L, Karring T. Bone healing and soft tissue contour changes following single-tooth extraction: A clinical and radiographic 12-month prospective study. *Int J Periodontics Restorative Dent.* 2003;23(4):313–23.
4. Moy P, Palacci P. Minor bone augmentation procedures. In: Palacci P, Ericsson I, editors. *Esthetic Implant Dentistry: Soft and Hard Tissue Management.* Hanover Park, IL: Quintessence Publishing Co, Inc.; 2001. p. 137–58.
5. de Boer HH. The history of bone grafts. *Clin Orthop Relat Res.* 1988;226:292–8.

6. Nissan J, Marilena V, Gross O, Mardinger O, Chaushu G. Histomorphometric analysis following augmentation of the posterior mandible using cancellous bone block allograft. *J Biomed Mater Res A*. 2011;97(2):509–13.
7. Kloss FR, Offermanns V, Kloss-Brandstätter A. Comparison of allogeneic and autogenous bone grafts for augmentation of alveolar ridge defects—a 12-month retrospective radiographic evaluation. *Clin Oral Implants Res*. 2018;29(11):1163–75.
8. Mellonig JT. Donor selection, testing, and inactivation of the HIV virus in freeze-dried bone allografts. *Pract Periodontics Aesthet Dent*. 1995;7(1):13–22.
9. Page MJ, McKenzie JE, Bossuyt PM, Boutron I, Hoffmann TC, Mulrow CD, et al. The PRISMA 2020 statement: An updated guideline for reporting systematic reviews. *BMJ*. 2021;372:n71.
10. Higgins JP, Altman DG, Sterne JAC. Assessing risk of bias in included studies (Chapter 8). In: Higgins JP, Green S, editors. *Cochrane Handbook for Systematic Reviews of Interventions*. Version 5.1.0. The Cochrane Collaboration; 2011.
11. Barker TH, Stone JC, Sears K, Klugar M, Tufanaru C, Leonardi-Bee J, et al. The revised JBI critical appraisal tool for the assessment of risk of bias for randomized controlled trials. *JBI Evid Synth*. 2023;21(10):494–506.
12. Barker TH, Habibi N, Aromataris E, Stone JC, Leonardi-Bee J, Sears K, et al. The revised JBI critical appraisal tool for the assessment of risk of bias for quasi-experimental studies. *JBI Evid Synth*. 2024;22(4):378–88.
13. Deluiz D, Santos Oliveira L, Ramôa Pires F, Reiner T, Armada L, Nunes MA, et al. Incorporation and remodeling of bone block allografts in the maxillary reconstruction: A randomized clinical trial. *Clin Implant Dent Relat Res*. 2017;19(2):180–94.
14. Tresguerres FG, Cortes AR, Hernandez Vallejo G, Cabrejos-Azama J, Tamimi F, Torres J. Clinical and radiographic outcomes of allogeneic block grafts for maxillary lateral ridge augmentation: A randomized clinical trial. *Clin Implant Dent Relat Res*. 2019;21(6):1087–98.
15. Barone A, Varanini P, Orlando B, Tonelli P, Covani U. Deep-frozen allogeneic onlay bone grafts for reconstruction of atrophic maxillary alveolar ridges: A preliminary study. *J Oral Maxillofac Surg*. 2009;67(6):1300–6.
16. Chaushu G, Mardinger O, Calderon S, Moses O, Nissan J. The use of cancellous block allograft for sinus floor augmentation with simultaneous implant placement in the posterior atrophic maxilla. *J Periodontol*. 2009;80(3):422–8.
17. Chaushu G, Vered M, Mardinger O, Nissan J. Histomorphometric analysis after maxillary sinus floor augmentation using cancellous bone-block allograft. *J Periodontol*. 2010;81(8):1147–52.
18. Nissan J, Mardinger O, Calderon S, Romanos GE, Chaushu G. Cancellous bone block allografts for the augmentation of the anterior atrophic maxilla. *Clin Implant Dent Relat Res*. 2011;13(2):104–11.
19. Acocella A, Bertolai R, Ellis E 3rd, Nissan J, Sacco R. Maxillary alveolar ridge reconstruction with monocortical fresh-frozen bone blocks: A clinical, histological and histomorphometric study. *J Craniomaxillofac Surg*. 2012;40(6):525–33.
20. Krasny M, Krasny K, Fiedor P, Zadurska M, Kamiński A. Long-term outcomes of the use of allogeneic, radiation-sterilised bone blocks in reconstruction of the atrophied alveolar ridge in the maxilla and mandible. *Cell Tissue Bank*. 2015;16(4):631–8.
21. Deluiz D, Oliveira L, Fletcher P, Pires FR, Nunes MA, Tinoco EM. Fresh-frozen bone allografts in maxillary alveolar augmentation: Analysis of complications, adverse outcomes, and implant survival. *J Periodontol*. 2016;87(11):1261–7.
22. Ahmadi RS, Sayar F, Rakhshan V, Iranpour B, Jahanbani J, Toumaj A, et al. Clinical and histomorphometric assessment of lateral alveolar ridge augmentation using a corticocancellous freeze-dried allograft bone block. *J Oral Implantol*. 2017;43(3):202–10.
23. Lorenz J, Kubesch A, Al-Maawi S, Schwarz F, Sader RA, Schlee M, et al. Allogeneic bone block for challenging augmentation—a clinical, histological, and histomorphometrical investigation of tissue reaction and new bone formation. *Clin Oral Investig*. 2018;22(8):3159–69.
24. Krasny K, Krasny M, Wojtowicz A, Kaminski A. Allogeneic bone block volume preservation in ridge augmentation for implants. *Int J Periodontics Restorative Dent*. 2018;38(3):355–60.

25. Misch CE, Goodacre CJ, Finley JM, Misch CM, Marinbach M, Dabrowsky T, et al. Consensus conference panel report: Crown-height space guidelines for implant dentistry—part 1. *Implant Dent.* 2005;14(3):312–8.
26. Rangert B, Krogh PH, Langer B, Van Roekel N. Bending overload and implant fracture: A retrospective clinical analysis. *Int J Oral Maxillofac Implants.* 1995;10(3):326–34.
27. Rangert B, Jemt T, Jörneus L. Forces and moments on Brånemark implants. *Int J Oral Maxillofac Implants.* 1989;4(3):241–7.
28. Virolainen P, Heikkilä J, Hirn M, Aro HT, Aho AJ. 30 years of bone banking at Turku bone bank. *Cell Tissue Bank.* 2003;4(1):43–8.
29. Aho AJ, Eskola J, Ekfors T, Manner I, Kouri T, Hollmen T. Immune responses and clinical outcome of massive human osteoarticular allografts. *Clin Orthop Relat Res.* 1998;346:196–206.
30. Spin-Neto R, Landazuri Del Barrio RA, Pereira LA, Marcantonio RA, Marcantonio E, Marcantonio EJr. Clinical similarities and histological diversity comparing fresh frozen onlay bone blocks allografts and autografts in human maxillary reconstruction. *Clin Implant Dent Relat Res.* 2013;15(4):490–7.
31. Albrektsson T. Repair of bone grafts. A vital microscopic and histological investigation in the rabbit. *Scand J Plast Reconstr Surg.* 1980;14(1):1–12.
32. Lumetti S, Consolo U, Galli C, Multinu A, Piersanti L, Bellini P, et al. Fresh-frozen bone blocks for horizontal ridge augmentation in the upper maxilla: 6-month outcomes of a randomized controlled trial. *Clin Implant Dent Relat Res.* 2014;16(1):116–23.
33. da Costa CE, Pelegri AA, Fagundes DJ, Simoes Mde J, Taha MO. Use of corticocancellous allogeneic bone blocks impregnated with bone marrow aspirate: A clinical, tomographic, and histomorphometric study. *Gen Dent.* 2011;59(4):e200–5.