

A Rare Case of Maxillary Ameloblastoma with Pulmonary Metastasis

Karpal Singh Sohal^{1*}, Salvatory M. Mlaga², Edda A. Vuhahula³

¹Departments of Oral and Maxillofacial Surgery, Muhimbili University of Health and Allied Sciences, Dar es Salaam, Tanzania.

²Department of Pathology, Hubert Kairuki Memorial University, Dar es Salaam, Tanzania.

³Department of Pathology, Muhimbili University of Health and Allied Sciences, Dar es Salaam, Tanzania.

*E-mail ✉ karpal@live.com

Received: 07 January 2021; Revised: 10 March 2021; Accepted: 19 March 2021

ABSTRACT

Low-grade odontogenic epithelial neoplasms, known as ameloblastomas, account for approximately 10% of odontogenic tumors and 1% of all oral malignancies. In rare cases, these tumors may spread to distant locations; if this occurs, they are called metastatic ameloblastomas. This article describes a case of an unusual type of maxillary ameloblastoma with lung metastasis and the challenges of managing it in resource-limited settings. In 2018, a 24-year-old African man presented with a significant swelling on the right side of his face that had persisted for two years. The patient stated that the swelling began in 2016 as a painless nodule around the right cheek and that it grew steadily over time, ultimately leading to a noticeable facial deformity. The swelling spread over the entire right side of the face within a year or so, and it began to hurt. The pain was mild, and it was confined. Metastatic ameloblastoma is a rare tumor that has a slow clinical progression. Metastasis is hard to anticipate, even if the initial lesion is surgically repaired. Since there is no established technique to prevent or identify metastatic ameloblastoma, individuals with ameloblastoma that are detected even years after original resection must have close and ongoing follow-up.

Keywords: Lungs, Maxilla, Metastatic ameloblastoma, Odontogenic tumors

How to Cite This Article: Sohal KS, Mlaga SM, Vuhahula EA. A Rare Case of Maxillary Ameloblastoma with Pulmonary Metastasis. Asian J Curr Res Clin Cancer. 2021;1(1):10-6. <https://doi.org/10.51847/aFMGGECmsY>

Introduction

Low-grade odontogenic epithelial neoplasms, known as ameloblastomas, make up around 10% of odontogenic tumors and 1% of all oral malignancies [1]. About 20% of the maxilla is involved, and they typically appear in the mandible [2, 3]. These tumors are thought to be benign and develop slowly, but they are aggressive locally and have a high chance of recurring if left untreated [1-4]. In rare cases, these tumors may spread to other locations, a condition known as distant metastasis [3], which is linked to many recurrences after surgery and a longer tumor lifespan [2]. Metastatic ameloblastoma is the term used to describe ameloblastoma that has spread from its histologically benign appearance [5]. The World Health Organization (WHO) reclassified metastatic ameloblastoma as a benign ameloblastoma subtype in 2017 after it had previously been classed as a malignant odontogenic tumor in 2005 [6].

Because metastatic ameloblastoma is uncommon, managing it can be difficult [7]. Chemotherapy and radiation therapy, surgical resection, and close monitoring are the available treatment options [8]. While surgery is usually the preferred treatment for resectable metastatic lesions, radiation and/or chemotherapy may be utilized for inoperable patients; however, the outcomes are uncertain and unsatisfactory [7, 9, 10].

The difficulties of diagnosing and treating such instances in underdeveloped nations are discussed here, along with a very uncommon case of maxillary ameloblastoma that had spread to the lungs.

Case report

A 24-year-old male African patient came to our facility in December 2018 complaining of swelling on the right side of his face that had been there for approximately two years. The patient stated that the swelling began in 2016 as a painless nodule around the right cheek and that it grew steadily over time, ultimately leading to a noticeable facial deformity. The swelling spread over the entire right side of the face within a year or so, and it began to hurt. The pain was mild, and it was confined. The swelling spread to the right eye by the middle of 2018, pushing it outward and upward, although no vision loss occurred. This was followed by an outward spread of the swelling surrounding the right cheek, which eventually developed an ulcer and began to bleed. Additionally, the patient stated that he was hospitalized at our hospital in 2012 because of edema on the right side of his upper jaw, which was surgically relieved.

The patient's clinical examination showed a young guy who seemed pale, slightly emaciated, and ill. He had a good awareness of his surroundings. A large, irregular exophytic lump measuring around 23 by 14 cm on the right side of the face caused the patient to present with facial asymmetry upon local inspection. The skin on top had an ulcerated patch and was glossy and hyperemic. Additionally, there were obvious surgical scars from earlier procedures. The eyesight remained intact despite the superior and outward displacement of the right eye. The right nostril was obstructed, and the nose was shifted to the left. The skin that was overstretched and unable to be folded had a normal temperature. The swelling was firm, attached to the underlying tissues, and slightly sensitive. At its bottom boundary, there was an oval-shaped outgrowth or extension of the edema that was heavily bleeding and ulcerated (**Figures 1a and 1b**).

The whole right side of the upper jaw was occupied by the lesion intraorally, and it extended only a few millimeters across the midline to the left side of the palate. The oval-shaped lesion had an overlying mucosa that was otherwise hyperemic. These clinical results led to the tentative diagnosis of ameloblastic fibrosarcoma.

The patient's workup comprised tissue histological examination, radiographic investigations, and hematological tests. The result of the total blood count was normal; however, his hemoglobin levels were low (7.1 g/dl). The results of the liver and kidney function tests were within acceptable limits. A computed tomography (CT) scan of the head and neck area and a chest X-ray were part of the initial radiological studies. A large, diverse lesion that undermined the cortical plate and extended to the anterior cerebral fossa was visible on the CT scan pictures (**Figures 2a and 2b**). Lung metastatic characteristics were visible on the chest X-ray (**Figure 3a**). Follicle ameloblastoma was identified as the lesion caused by wedge biopsy (**Figures 4a and 4b**). They tracked the biopsy findings of the previously operated lesion, which likewise showed evidence of follicular ameloblastoma. A group of oral and maxillofacial surgeons asked for a second tissue sample because of its clinically aggressive character. This biopsy was examined by a group of various pathologists, and the results were comparable (**Figure 5**). Ki67 immunohistochemistry showed an aggressive tumor with 60%–80% reactivity in neoplastic cells. After a CT scan of the chest (**Figure 3b**), a fine-needle aspiration cytology of the lung mass was carried out under CT guidance. Additionally, the aspirate findings were suggestive of ameloblastoma (**Figure 6**). This led to the ultimate diagnosis of metastatic ameloblastoma.

The patient was scheduled for palliative chemoradiotherapy in February 2019 after being submitted to the tumor board because of the original lesion's unresectability. The patient was referred to us in April 2019 after experiencing extensive bleeding throughout the oral cavity following three cycles of chemotherapy and radiation. A hematological examination indicated pancytopenia. He got four units of whole blood and was sent to the cancer institute for additional treatment. The patient was examined again in early 2020, and the ovalish outgrowth/extension of the edema at its bottom border had greatly decreased.

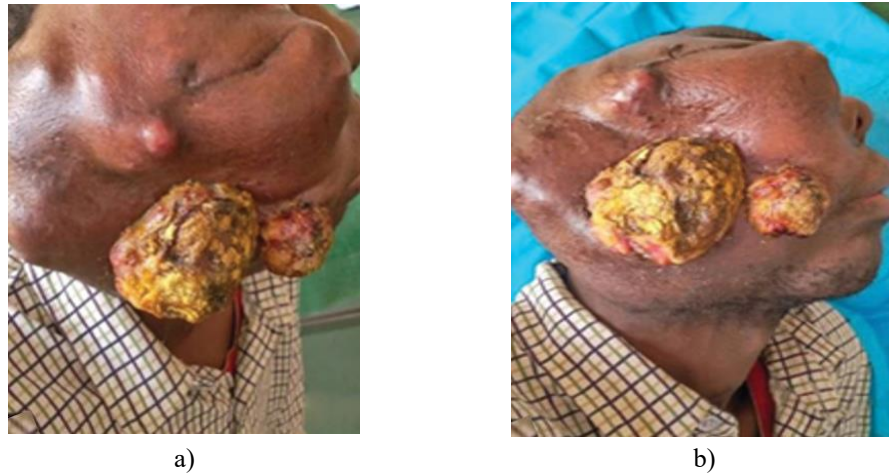


Figure 1. a and b) Clinical presentation of the patient showing a massive irregular exophytic mass on the right side of the face; there is an ulcerated ovalish outgrowth/extension of the swelling at its lower border and the right eye is displaced superiorly and outwards.

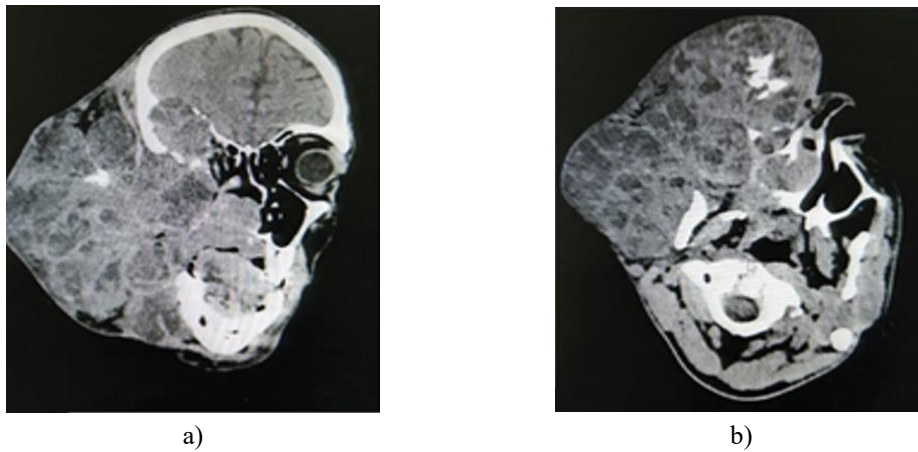


Figure 2. Computed tomography scan appearance of the maxillary lesion;

a) A coronal computed tomography scan demonstrates a heterogeneous soft-tissue mass, originating from the maxilla, involving the right maxillary sinus and the orbital roof, and extending into the cranial fossa, b) Axial computed tomography scan showing a huge heterogeneous soft-tissue mass eroding the walls of the maxillary sinus and displacing the nasal septum to the left.

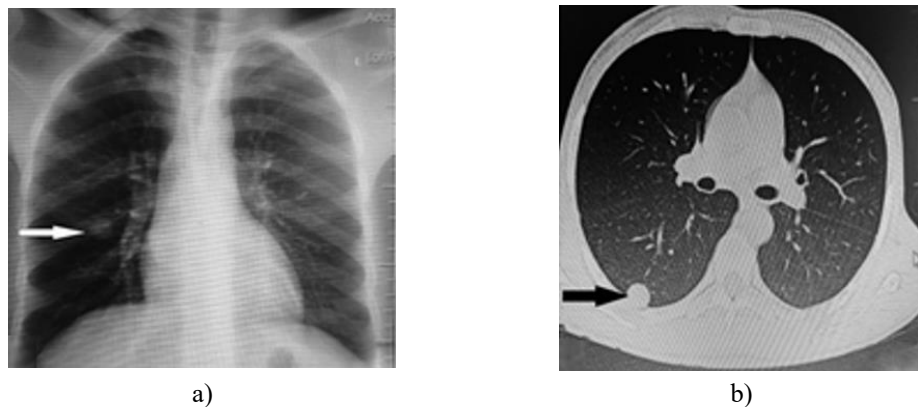


Figure 3. Chest X-ray and computed tomography scan of the metastatic lesions; a) X-ray showing a solitary nodular opacity in the middle zone of the right lung (white arrow), b) Computed tomography showing a soft-tissue mass in the posterior aspect of the right lung presenting as a nodule (black arrow).

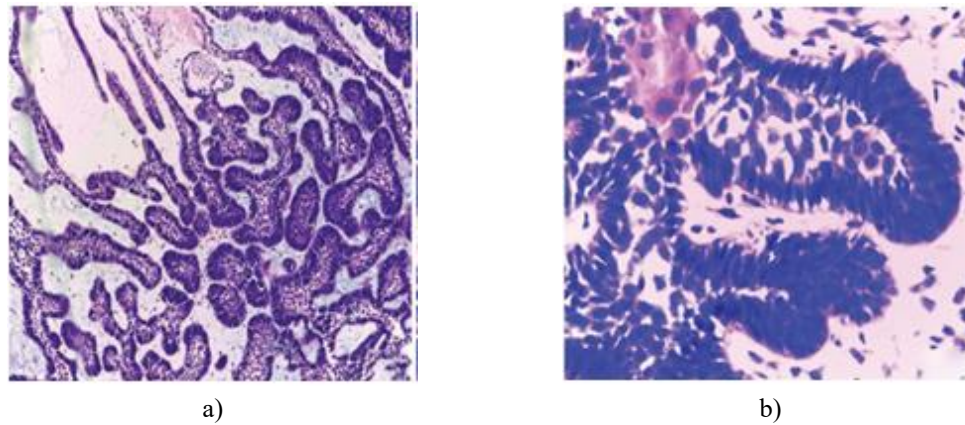


Figure 4. Histopathological images (H and E) of the maxillary lesion; a) Islands of odontogenic epithelium with peripheral palisading and stellate reticulum at the center ($\times 10$), b) Foci of abnormal mitoses in both the peripheral palisading cells and the central stellate reticulum ($\times 40$).

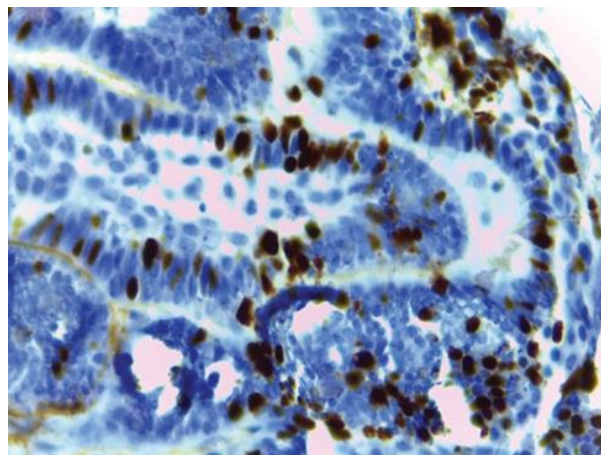


Figure 5. Immunohistochemistry staining of the maxillary lesion: Ki67- positive staining with the labeling index reaching 60%–80% reactivity in neoplastic cells.

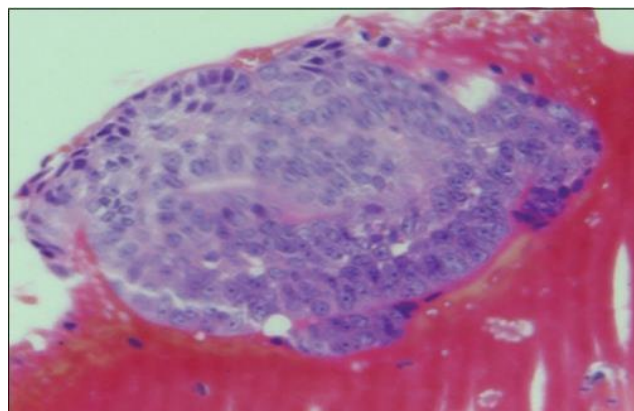


Figure 6. Histocytological images (H and E) of the lung mass showing cellular smear with clusters of odontogenic epithelium characterized by peripheral palisading and loose pale nuclei at the center.

Results and Discussion

A lesion that spreads to a different organ but has benign histology in both the main and metastatic tissues is called metastatic ameloblastoma [11]. It is a rare phenomenon that makes up around 2% of instances of ameloblastoma [12]. The lungs, cervical lymph nodes, diaphragm, liver, brain, and bone are among the often reported metastases [5]. The most frequent location of metastasis is the lung, and the mandible is the main site in around 80% of cases

[4]. The case described here is uncommon because the maxilla was the main location in addition to the fact that the ameloblastoma was metastatic.

It is unknown how a lesion that seems to be histologically benign might extend to a distant organ [13]. Aspiration of tumor cells from the original oral lesion and hematogenous and lymphatic pathways are hypothesized mechanisms of metastatic dissemination [4, 13, 14]. During surgery, tumor implantation is another potential way for metastases to occur [8]. It is impossible to rule out direct lung tumor cell implantation and aspiration from the endotracheal tube during the prior operation (hemimaxillectomy) in the instance described.

The age range for metastatic ameloblastoma is 5 to 94 years old [13, 15]. The age group most impacted, though, appears to be the third decade of life [8, 10, 12, 16, 17]. The interval between the initial tumor's diagnosis and its metastases might range from 0 to 15 years [15]. The patient in the case study acquired metastases at the age of 24 after presenting with a primary tumor at the age of 17 years. This is within the same time frame as what has been reported in the literature.

In contrast to the case described by Rabo *et al.* [8], in which the patient had acute, piercing, non-radiating, and intermittent upper back pains, our patient exhibited no symptoms or indicators that would arouse suspicions of lung metastases. We came to the preliminary working diagnosis of ameloblastic fibrosarcoma as a result of this and the tumor's clinical-radiological characteristics. In addition to pain, paresthesia, dysesthesia, and ulcers, face swelling is a typical symptom of ameloblastic fibrosarcoma [18, 19]. It manifests radiologically as a multilocular or unilocular radiolucent mass with an ill-defined boundary. With a propensity to spread to nearby soft tissues, the base of the skull, and intracranial and orbital tissues, it often results in the cortical bone's gross growth and/or erosion [18, 19].

A chest X-ray and CT scan were a part of the further workup since the tumor's clinical-radiological behavior did not fit the histological diagnosis of ameloblastoma. These tests resulted in the discovery of a lesion on the chest that raised the possibility of metastases, which cytology subsequently verified. The diagnosis of metastatic ameloblastoma is often made nearly always after metastasis has taken place, rather than before [14]. One of the issues in controlling these lesions is the difficulty in predicting which cases will spread and which won't.

Several markers exhibit high positivity in metastatic ameloblastoma, but histopathologically, it is challenging to distinguish between metastatic and nonmetastatic ameloblastoma [4-21]. Extracellular signal-regulated kinase five and KRSA are immunohistochemical markers that are significantly positive in ameloblastoma but not in metastatic ameloblastoma. On the other hand, the N-terminus-truncated p73 isoform ($\Delta Np73$) has been shown in 100% of metastatic ameloblastomas [21]. However, in the cases that have been documented thus far, these investigations were unable to be conducted for a variety of reasons, including the cost of obtaining the necessary reagents and their unavailability. Although Ki67 immunohistochemistry was performed, it does not explicitly identify metastatic ameloblastoma; rather, it identifies local invasiveness and recurrences of the tumor, which affects the prognosis [22, 23].

Because so few cases of metastasizing ameloblastoma have been recorded, there is no gold standard for treatment [20]. While the significance of chemotherapy and radiation is still unclear, radical surgery continues to be the cornerstone of treatment [10, 20]. Adjuvant and adjuvant radiation have occasionally been effectively used in conjunction with surgery [10]. Although radiotherapy is mainly used for palliative care due to its uncertain response, it has been suggested for inoperable metastatic deposits [8]. Since the tumor had already spread to the skull in the example described here, surgery was not an option. Instead, palliative chemoradiotherapy was used, which had some notable advantages because the tumor's size did shrink. Since there was no surgery, the prognosis was anticipated to be bad since, according to reports, the median survival is 6 years with sufficient resection and radiation therapy, compared to 2 years without resection [17].

Routine yearly chest X-rays may be useful in evaluating patients with ameloblastomas [24], but in our situation, this was not possible because the patient did not attend follow-up clinics following the initial surgery and only returned six years later with a large tumor. Financial challenges that the majority of patients in poor nations encounter are the primary cause of delays in seeking medical attention and nonattendance at follow-up clinics [25].

Conclusion

A rare instance of maxillary ameloblastoma that spreads to the lungs is described in this case. Metastatic ameloblastoma is a rare tumor that has a slow clinical progression. Metastasis is hard to anticipate, even if the

initial lesion is surgically repaired. Since there is no established technique to prevent or identify metastatic ameloblastoma, individuals with ameloblastoma that are detected even years after original resection must have close and ongoing follow-up.

Acknowledgments: We are most grateful to the patient for permitting us to report the case.

Conflict of Interest: None

Financial Support: None

Ethics Statement: The authors certify that they have obtained all appropriate patient consent forms. The patient understands that their name and initials will not be published, and due efforts will be made to conceal the identity, but anonymity cannot be guaranteed.

References

1. Manikkam S, Masthan KM, Anitha N, Krupaa J. Ameloblastoma. *J Pharm Bioallied Sci.* 2015;7(Suppl 1):S167-70.
2. Milman T, Lee V, LiVolsi V. Maxillary ameloblastoma with orbital involvement: an institutional experience and literature review. *Ophthalmic Plast Reconstr Surg.* 2016;32(6):441-6.
3. Valkadinov I, Conev N, Dzhenkov D, Donev I. Rare case of ameloblastoma with pulmonary metastases. *Intractable Rare Dis Res.* 2017;6(3):211-4.
4. Bi R, Shen L, Zhu X, Xu X. Malignant ameloblastoma (metastatic ameloblastoma) in the lung: 3 cases of misdiagnosis as primary lung tumor with a unique growth pattern. *Diagn Pathol.* 2015;10(1):123.
5. Rotellini M, Maggiore G, Trovati M, Saraceno MS, Franchi A. Metastasizing maxillary ameloblastoma: report of a case with molecular characterization. *J Oral Maxillofac Res.* 2016;7(1):e5.
6. Soluk-Tekkeşin M, Wright JM. Odontogenic tumors: where are we in 2017? *J Istanbul Univ Fac Dent.* 2017;51(3 Suppl 1):S10-30.
7. Scannell J, Lees B, Hopper C. Can radiofrequency ablation be used as a treatment modality for the management of pulmonary metastatic ameloblastoma? *Radiol Case Rep.* 2009;4(2):249.
8. Rabo JJ, Carpela AB, Guevara ES, Romualdez JA. Mandibular ameloblastoma with lung metastasis 10 years after resection. *Philipp J Otolaryngol Neck Surg.* 2016;31(1):53-6.
9. Amzerin M, Fadoukhair Z, Belbaraka R, Iraqui M, Boutayeb S, M'rabti H, et al. Metastatic ameloblastoma responding to combination chemotherapy: case report and review of the literature. *J Med Case Rep.* 2011;5:491.
10. Grünwald V, Le Blanc S, Karstens JH, Weihkopf T, Kuske M, Ganser A, et al. Metastatic malignant ameloblastoma responding to chemotherapy with paclitaxel and carboplatin. *Ann Oncol.* 2001;12(10):1489-91.
11. Adeel M, Rajput MSA, Arain AA, Baloch M, Khan M. Ameloblastoma: management and outcome. *Cureus.* 2018;10(10):e3437.
12. Lacin S, Dogrul A, Dikmen E, Kertmen N, Turker A, Kars A. Metastatic ameloblastoma to the liver: rare presentation of a rare disease. *J Clin Case Rep.* 2019;9(1207):9-10.
13. Hasim FW, Poon CC, Smith AC. Prolonged survival with confirmed metastatic pulmonary ameloblastoma. *Int J Oral Maxillofac Surg.* 2007;36(10):953-5.
14. Berger AJ, Son J, Desai NK. Malignant ameloblastoma: concurrent presentation of primary and distant disease and review of the literature. *J Oral Maxillofac Surg.* 2012;70(10):2316-26.
15. Jayaraj G, Sherlin HJ, Ramani P, Premkumar P, Natesan A, Ramasubramanian A, et al. Metastasizing ameloblastoma – a perennial pathological enigma? Report of a case and review of literature. *J Craniomaxillofac Surg.* 2014;42(6):772-9.
16. Cardoso A, Lazow SK, Solomon MP, Berger JR, Rock A. Metastatic ameloblastoma to the cervical lymph nodes: a case report and review of literature. *J Oral Maxillofac Surg.* 2009;67(6):1163-6.
17. Salami A, Ezenkwa U, Salami M, Ajani M, Okolo C. Malignant ameloblastoma: a challenging diagnosis. *Autops Case Rep.* 2018;8(4):e2018043.

18. Hascoet E, Cleac'h SL, Taugeron F, Bertin H, Longis J, Piot B, et al. Ameloblastic fibrosarcoma of the mandible: case report and literature review. *Med Buccale Chir Buccale*. 2017;23(3):164-8.
19. Khalili M, Shakib PA. Ameloblastic fibrosarcoma of the upper jaw: report of a rare case with long-term follow-up. *Dent Res J (Isfahan)*. 2013;10(1):112-5.
20. Yang RN, Wang XS, Ren J, Xie YF, Zhou D, Ge DF, et al. Mandible ameloblastoma with lung metastasis: a rare case report. *Int J Clin Exp Pathol*. 2015;8(6):6793-9.
21. Ganjre AP, Sarode G, Sarode S. Molecular characterization of metastasizing ameloblastoma: a comprehensive review. *J Cancer Res Ther*. 2019;15(3):455-62.
22. Ahlem B, Wided A, Amani L, Nadia Z, Amira A, Faten F. Study of Ki67 and CD10 expression as predictive factors of recurrence of ameloblastoma. *Eur Ann Otorhinolaryngol Head Neck Dis*. 2015;132(5):275-9.
23. Abdel-Aziz A, Amin MM. EGFR, CD10 and proliferation marker Ki67 expression in ameloblastoma: possible role in local recurrence. *Diagn Pathol*. 2012;7(1):14.
24. Goldenberg D, Sciubba J, Koch W, Tufano RP. Malignant odontogenic tumors: a 22-year experience. *Laryngoscope*. 2004;114(10):1770-4.
25. Msolla R, Simon EN, Sohal KS, Owibingire SS. Late reporting for health care among patients presenting with oral maxillofacial tumours or tumour- like lesions in Muhimbili national hospital, Tanzania. *Med J Zambia*. 2019;46(2):109-16.