

Platelet-Rich Plasma as an Adjunct for Accelerating Maxillary Canine Retraction: Clinical Implications

Yuki Li^{1*}, Lina Hansen², Kenji Z. Huang¹

¹Department of Preventive and Community Dentistry, Faculty of Dentistry, Peking University, Beijing, Taiwan.

²Department of Orthodontics, College of Dental Medicine, University of Helsinki, Helsinki, Norway.

*E-mail ✉ yli@outlook.com

Received: 14 March 2021; Revised: 24 May 2021; Accepted: 27 May 2021

ABSTRACT

Various techniques have been developed to speed up orthodontic tooth movement. PRP (platelet-rich plasma) is one of the newest methods because it is less intrusive and has few adverse effects. It should record any related pain and assess how a PRP submucosal injection affects maxillary canine retraction. Twenty patients were chosen and randomized at random to a split-mouth trial in which one side (the study side) received a PRP injection and the other side (the control) received no injection. The injection was administered before the retraction of the canine and was not repeated. Immediately after extraction, alignment, and leveling, the canine retraction was performed on a 0.017x0.025-inch stainless steel arch wire with a coil spring attached from the canine hook to a mini-screw positioned laterally between the upper 2nd premolar and the first molar. The research lasted for four months. For four months, alginate impressions were collected monthly and before canine retraction. The extent of canine retraction was measured using data from digital models. The pain was determined using the VAS (visual analog scale). There was a statistically remarkable difference ($P < 0.05$) in the canine retraction rate between the study and control groups across the four months of the trial. The dog's total distance traveled on the study side differed statistically significantly ($P = 0.022$). Higher levels of pain were reported on the study side. A safe and less invasive method for quickening canine retraction and cutting down on treatment duration is submucosal PRP injection.

Keywords: Canine retraction, Pharmacological approaches, Platelet-rich plasma, Acceleration

How to Cite This Article: Li Y, Hansen L, Huang KZ. Platelet-Rich Plasma as an Adjunct for Accelerating Maxillary Canine Retraction: Clinical Implications. *J Orthod Periodontal Biomater Res.* 2021;1:23-30. <https://doi.org/10.51847/zB9dLy6adf>

Introduction

One of the most time-consuming dental procedures is orthodontic correction [1-4]. Based on the case severity, individual specifications, and treatment plan, the determined duration of orthodontic therapy by conventional orthodontics is 24 months [2]. Prolonged treatment has many drawbacks, such as caries [5, 6], external root resorption [7, 8], patient burnout, and periodontal diseases [9]. There have been several attempts to shorten orthodontic therapy duration, including biological, surgical, and physical approaches [10], but most of these technologies still have a lot of unknown and unsolved problems. Numerous studies have calculated the effects of several biological materials, including prostaglandin [11-13], vitamin D [14, 15], vitamin C [16], and parathyroid hormone [17] on the pace of orthodontic tooth movements (OTM), with encouraging findings. However, employing allogenic products, like extra hormones, requires frequent injections and can have a systemic effect that is too strong [18]. One biological substance that has been employed recently to accelerate OTM is PRP. A tiny quantity of plasma with an autologous concentration of human platelets is called platelet-rich plasma (PRP) [18]. PRP contains alpha granules, which are prevalent in cytokines and autologous growth factors. These cytokines and growth factors are crucial for osteoclastic and osteoblastic activity, which promotes the process of alveolar bone remodeling [19, 20]. Liou [21] stated that PRP can accelerate various tooth movement types

clinically. Rashid *et al.* [22] and Gulec *et al.* [23] stated a positive association between PRP local injection and OTM acceleration in animal studies. In contrast, Akbulut *et al.* [24] stated that PRP was not useful in accelerating OTM. Additionally, Timamy *et al.* [25] documented PRP's short-term accelerating impact. Since PRP's impact is still debatable, more clinical research is required to validate its efficacy in accelerating OTM. The current trial's objectives were to document any associated pain and assess the impact of submucosal PRP injection on maxillary canine retraction.

Materials and Methods

Split-mouth randomized clinical investigation with 1:1 allocation is what this trial is. The trial was conducted at Mansoura University with ethics committee approval from the faculty of dentistry (No. M08070519).

The sample size was calculated using G power version 3.1.2.9 based on a type I error frequency of 5%. Taking into consideration the *in vitro* studies done by Rashid *et al.* [22] and Gulec *et al.* [23], we assumed the effect size difference between groups to be large (0.4). The calculation using repeated Anova had revealed that 17 patients were needed. The sample was increased by 10% to 20 patients to guard against any dropout during the trial. A simple randomization procedure drawing lots was used to allocate the side of the maxilla for the PRP injection, while the opposing side will serve as the split-mouth control. All patients were recruited from subjects attending the orthodontic department, faculty of dentistry, Mansoura University.

The following inclusion characteristics were applied: (1) Both male and female subjects with class II division 1 malocclusion that requires therapeutic extraction of the upper first premolars, (2) Age ranging from 16-22 years, (3) Good general and oral health, (4) Maximum anchorage required using a mini implant. The exclusion characteristics were: (1) Systemic diseases or medication that are probable to influence bone biology, (2) Evidence of root resorption, (3) Poor oral hygiene, and (4) Previous orthodontic treatment.

All patients were acquainted with the study and the injection procedures and then they were invited to sign a consent.

Methods

All patients were treated using fixed orthodontic brackets MBT prescription; 0.022-inch slot brackets (Dentaurum, Germany). After initial leveling and alignment, each patient received two mini-screws (3M-Unitek, 1.8x8 mm) buccally on both sides between the upper second premolar and the upper first molar, 5 mm from the alveolar crest to be used as direct anchorage. The patients were referred for extraction of the upper first premolars within the same week of the mini-screw insertion. After that, leveling and alignment were completed until 0.017x0.025-inch stainless steel wire to minimize binding and friction during canine retraction. The canine retraction was started after 6 months to ensure complete healing of the extraction socket [26].

PRP injection and preparation

According to Liou [21], PRP was obtained using the double spin method under aseptic processing procedures. Three PRP tubes (Golden VAC), each containing sodium citrate (as an anticoagulant), were filled with thirty milliliters of the patient's entire blood. The tubes were shaken, mingled six to eight times, and rotated 180 degrees upside down. After separating the red blood cells with a centrifuge set at 1000 rpm for 12 minutes, the platelets were concentrated using a second centrifuge set for 8 minutes at 3000 rpm. The concentration of PRP was five times higher than that of whole blood (**Figure 1**).

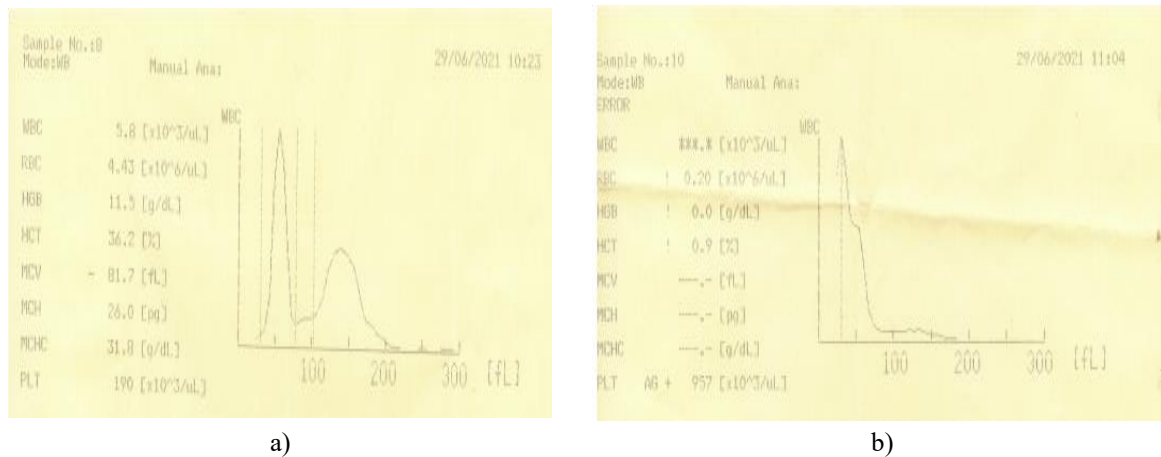


Figure 1. AZZOTA utilized B-LSC-6K Centrifuge, generating high concentration PRP (five times the concentration in the entire blood)

The study side underwent local anesthesia to manage pain before PRP injection. The buccal and palate mucosa distal to the dog were then submucosally injected with 30 PRP units in six injection sites. The buccal mucosa contains three injection sites. Three millimeters away from the canine was the first one. Three millimeters separated the first and second ones. Additionally, the distance between the second and third injection points was 3 mm. The palatal surface underwent the same process (**Figures 2 and 3**). Every injection had the same volume (5 units per location), was administered solely before canine retraction, and was never repeated. The control side was not injected.

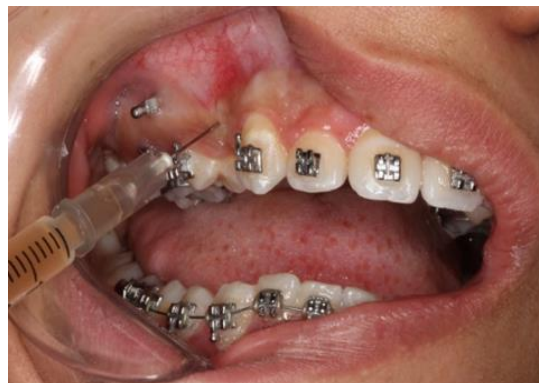

Figure 2. Buccal PRP submucosal injection on the research side

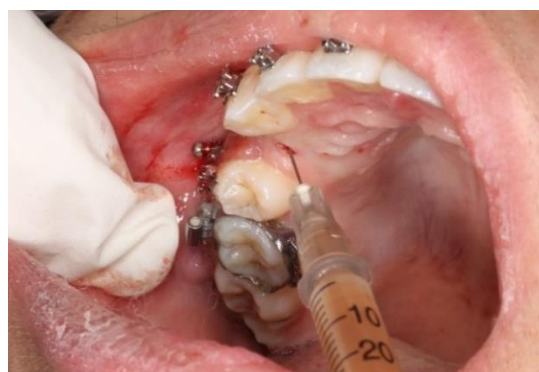

Figure 3. PRP submucosal injection into the palate on the research side.

A nickel-titanium closed coil spring that was stretched between the canine hook and the mini-screws and provided a retraction force of 150 gm on each side was used to start the canine retraction after PRP injection. A force gauge was used to alter the force level (040-712-Dentaurum, Correx 100-500 gm, Pforzheim, Germany).

Alginate imprints were taken every month for four months (T1, T2, and T3) and right before canine retraction (T0). A 3D shape scanner (3 forms, Copenhagen, Denmark) was used to scan each stone cast from (T0-T4). Three spots on the third rugae were used to superimpose the five models by the software of the 3-shape analyzer. The canine cusp point was localized in each digital approach. The distance between the canine cusp tip and the frontal plane was determined in each digital approach. The amount of monthly canine retraction was then determined using the variation in the canine cusp tip location across the five approaches. All of the models were shuffled and coded before measurements to make sure blinding throughout data analysis.

At the injection site, seven days later, five days later, three days later, one day later, twelve hours later, six hours later, and one hour later, the pain was measured using a 10 mm VAS (visual analog scale).

On the questionnaire, patients were asked to mark their level of discomfort vertically on a 10-cm horizontal line. 0 indicates no pain, 2-4 indicates mild pain, 5-7 indicates moderate pain, 8-9 indicates severe pain, and 10 indicates intolerable agony. All patients were ordered not to take any analgesics to avoid interfering with their feeling of pain. Individuals who were in excruciating pain were provided analgesics; these individuals were excluded from the pain assessment.

Statistical analysis

The statistical software for SPSS version 24 was utilized to analyze all of the values. Descriptive statistics (mean, standard deviation, maximum, and minimum) were computed for each side while taking the canine movement into account. The acquired data was examined for normal allocation using the Shapiro-Wilk test. The rate of canine retraction between the two sides was utilized to calculate the statistical significance of variances at a 95% confidence level by a paired t-test; a significance level of $P < 0.05$ was taken into consideration.

Results and Discussion

Twenty individuals, ranging in age from 16-22 years (mean 19 ± 3.74 years), finished the four-month trial. Every PRP injection was carried out without incident or danger. For each of the 20 patients, the canine retraction rate and the resulting pain were assessed.

With a mean value of 0.87, 1.09, 1.16, and 1.39 mm in the fourth, third, second, and first months, respectively, for the control group and 1.66, 1.49, 1.10, and 1.07 mm in the first, second, third, and fourth months, respectively, for the study group, the canine retraction rate demonstrated a statistically remarkable difference ($P < 0.05$) between the two sides during the four-month trial interval time. This suggests that PRP injection accelerates OTM.

Table 1. Mean values for the canine retraction rate in two groups (mm)

Measurement	Group	Min.	Max.	Mean	SD
First month (T0-T1)	Control	0.72	2.30	1.3980	0.62257
	Study	1.11	2.41	1.6680	0.48129
Second month (T1-T2)	Control	0.67	1.88	1.1600	0.41644
	Study	0.95	2.62	1.4980	0.50749
Third month (T2-T3)	Control	0.51	1.87	1.0900	0.44649
	Study	0.52	1.88	1.1050	0.44873
Fourth month (T3-T4)	Control	0.06	1.99	0.8720	0.67115
	Study	0.42	2.18	1.0760	0.63353

Table 2. Mean difference comparison of the amount of canine retraction between groups for each month

Measurement	Group	Mean difference	SD	SEM	95% Confidence interval of the difference		t	df	P-Value
					Lower	Upper			
First month (T0-T1)	Control Study	-0.27000	0.31344	0.09912	-0.49422	-0.04578	-2.724	9	0.023*
Second month (T1-T2)	Control Study	-0.33800	0.38381	0.12137	-0.61256	-0.06344	-2.785	9	0.021*

Third month (T2-T3)	Control Study	-0.01500	0.01958	0.00619	-0.02901	-0.00099	-2.423	9	0.038*
Fourth month (T3-T4)	Control Study	-0.20400	0.28159	0.08905	-0.40544	-0.00256	-2.291	9	0.048*

* Significant level at $P \leq 0.05$

There were statistically remarkable differences ($P = 0.022$) between the mean total distances traveled by the dog during the research period on the study side (4.331 mm) and the control side (4.273 mm) (**Table 3**).

Table 3. Mean difference comparison in the canine retraction total amount between groups

Measurement	Group	Mean	SD	Mean difference	SD	SEM	95% Confidence interval of the difference		t	df	P-Value
							Lower	Upper			
Total retraction (T0-T4)	Control	4.2736	0.1385	-0.0574	0.0657	0.02079	-0.10443	-	-2.761	9	0.022
	Study	4.3310	0.1632					0.01037			

The canine retraction mean rate was 1.08 and 1.06 mm/month for the study groups and the control group, respectively.

The data showed that the study side experienced more pain than the control side 1, 6, 12, and 24 hours later, with a statistically remarkable difference ($P < 0.05$), even though none of the patients used painkillers and all experienced tolerable pain (**Table 4**). The worst pain ratings were noted six and twelve hours after the injection. After a day, neither side was observed to be sore.

Table 4. Mean difference comparison in perception of pain between groups at four various time intervals

Measurement	Group	Mean difference	SD	SEM	95% Confidence interval of the difference		t	df	P-Value
					Lower	Upper			
1 hour	Control study	0.500	0.707	0.224	-0.006	1.006	2.236	9	.050*
6 hours	Control study	1.900	1.101	0.348	1.113	2.687	5.460	9	0.000*
12 hours	Control study	2.100	0.738	0.233	1.572	2.628	9.000	9	0.000*
24 hours	Control study	1.200	1.317	0.416	0.258	2.142	2.882	9	0.018*

* Significant level at $P \leq 0.05$

Due to its autogenous origin, healing properties, and low side effects, PRP has been regarded as a novel method for accelerating OTM [27].

To explain the PRP preparation process, several methods have been devised [28]. The first method of creating PRP involved combining it with thrombin and calcium chloride to activate the growth factor and coagulate the platelets into a gel [29]. Nevertheless, the duration of activity for this gel form was brief. So far as it can be maintained in liquid form, be injected, and have a long-lasting impact on the target tissue, the PRP utilized in this investigation was made similarly to the PRP utilized by Liou [21] without combining it with thrombin and calcium chloride.

The double centrifuge process was employed to create the PRP used in this investigation, resulting in a high PRP concentration (5 times that of whole blood). In their work, Seidel *et al.* [30] showed that preparing PRP using a double centrifugation methodology resulted in a higher concentration of platelets, whereas a single centrifugation protocol produced a lower concentration of platelets.

According to Gulec *et al.* [23], using a high concentration of PRP accelerates OTM more effectively than using a moderate concentration. They found that a moderate dose of PRP was useful, but not as much as a high concentration.

However, a greater dose of PRP (4.5 times) was not helpful as an adjuvant to orthodontic therapy, according to Akbulut *et al.* [24].

According to earlier research, RP was injected submucosally rather than intraperiosteally or subperiosteally after the use of PRP was suggested [21, 23, 24]. Additionally, prior research assessing the impact of local pharmacologic agent injection on OTM acceleration documented submucosal injection [11, 23, 31, 32].

The identical procedure described by Liou [21] was used for the submucosal injection method into the palatal and buccal mucosa distal to the canine. This may be consistent with the Akbulut *et al.* [24] results, who administered PRP exclusively to the buccal vestibular mucosa next to the maxillary right first molar's distal root. Additionally, Gulec *et al.* [23] exclusively administered the PRP to the buccal vestibular mucosa adjacent to the maxillary right first molar's mesial root. On the contrary, EL-Timamy *et al.* [25] and Rashid *et al.* [22] investigated the impact of intraligamentary PRP injection.

A single PRP injection, according to Liou [21], lasts for five to six months clinically, with an acceleration higher rate in the 2-4 months after the injection. For this reason, the injection was performed before the retraction of the canine and did not recur.

Throughout the trial's four months, the study side had a higher canine retraction rate than the control side; the study side's and the control side's total canine retraction measurements were 4.273 and 4.331 mm, respectively. The results were clinically non-significant despite being statistically significant ($P = 0.022$). These findings concurred with those of Gulec *et al.* [23], who found that PRP speeds up OTM by 1.4-1.7 times. Additionally, Rashid *et al.* [22] found that the PRP group saw a more notable acceleration.

Few human researchers have used PRP to accelerate OTM. A study by Ali *et al.* [33] found that the rate of canine retraction on the research side was 29.1% more than that on the control side. However, according to El-Timamy *et al.* [25], the rate of cuspid retraction rose statistically considerably in the early phases of tooth movement, even if PRP did not have a long-term accelerating impact.

Particularly six and twelve hours following the injection, the study group's pain levels were higher than those of the control group. These findings concurred with those published by Liou [21], who found that 85% of people had discomfort 6–12 hours after injection. Given that clinical studies have shown that post-injection discomfort increases with PRP concentration, this pain may be connected to the increased PRP concentration [21].

Conclusion

- PRP submucosal injection is at least an aggressive and cheap method for accelerating the retraction of canines and decreasing the overall treatment time.
- PRP repeated injection in treatment time requires more study as to its impact reduction over time.

Acknowledgments: We would like to thank Dr. Nehal Fouad for her participation in statistical analysis.

Conflict of interest: None

Financial support: None

Ethics statement: The study protocol was approved by IRB (code no. M08070519).

References

1. Fink DF, Smith RJ. The duration of orthodontic treatment. *Am J Orthod Dentofacial Orthop.* 1992;102(1):45-51. doi:10.1016/0889-5406(92)70013-Z
2. Fisher MA, Wenger RM, Hans MG. Pretreatment characteristics associated with orthodontic treatment duration. *Am J Orthod Dentofacial Orthop.* 2010;137(2):178-86. doi:10.1016/j.ajodo.2008.09.028
3. Asgari I, Soltani S, Sadeghi SM. Effects of iron products on decay, tooth microhardness, and dental discoloration: A systematic review. *Arch Pharm Pract.* 2020;11(1):60-82.
4. Yamany IA. The employment of CBCT in assessing bone loss around dental implants in patients receiving mandibular implant-supported overdentures. *Int J Pharm Res Allied Sci.* 2019;8(3):9-16.
5. Geiger AM, Gorelick L, Gwinnett AJ, Benson BJ. Reducing white spot lesions in orthodontic populations with fluoride rinsing. *Am J Orthod Dentofacial Orthop.* 1992;101(5):403-7. doi:10.1016/0889-5406(92)70112-N

6. Bishara SE, Ostby AW. White spot lesions: formation, prevention, and treatment. *Semin Orthod.* 2008;14:174-82. doi:10.1053/j.sodo.2008.03.002
7. Segal GR, Schiffman PH, Tuncay OC. Meta-analysis of the treatment-related factors of external apical root resorption. *Orthod Craniofac Res.* 2004;7(2):71-8. doi:10.1111/j.1601-6343.2004.00286.x
8. Pandis N, Nasika M, Polychronopoulou A, Eliades T. External apical root resorption in patients treated with conventional and self-ligating brackets. *Am J Orthod Dentofacial Orthop.* 2008;134(5):646-51.
9. Royko A, Denes Z, Razouk G. The relationship between the length of orthodontic treatment and patient compliance. *Fogorv Sz.* 1999;92(3):79-86.
10. Nimeri G, Kau CH, Abou-Kheir NS, Corona R. Acceleration of tooth movement during orthodontic treatment - a frontier in orthodontics. *Prog Orthod.* 2013;14(1):42. doi:10.1186/2196-1042-14-42
11. Yamasaki K, Shibata Y, Imai S, Tani Y, Shibasaki Y, Fukuhara T. Clinical application of prostaglandin E1 (PGE1) upon orthodontic tooth movement. *Am J Orthod.* 1984;85(6):508-18.
12. Spielmann T, Wieslander L, Hefti A. Acceleration of orthodontically induced tooth movement through the local application of prostaglandin (PGE1). *Schweiz Monatsschr Zahnmed.* 1989;99(2):162-5.
13. Patil AK, Keluskar K, Gaitonde S. The clinical application of prostaglandin E1 on orthodontic tooth movement-A clinical trial. *J Indian Orthod Soc.* 2005;39(2):91-8.
14. Ciur MD, Zetu IN, Danisia HA, Bourgeois D, Andrian S. Evaluation of the influence of local administration of vitamin D on the rate of orthodontic tooth movement. *Med-Surg J.* 2016;120(3):694-9.
15. Varughese ST, Shamanna PU, Goyal N, Thomas BS, Lakshmanan L, Pulikkottil VJ, et al. Effect of vitamin D on canine distalization and alveolar bone density using multi-slice spiral CT: a randomized controlled trial. *Dent Pract.* 2019;20(12):1430-5.
16. Yussif NMA, Dehis HM, Rahman ARA, Aziz Mawma, Yassin MM. Efficacy and safety of locally injectable vitamin C on accelerating the orthodontic movement of maxillary canine impaction (oral mesotherapy technique): prospective study. *Clin Cases Miner Metab.* 2018;15(2):280-7.
17. Soma S, Iwamoto M, Higuchi Y, Kurisu K. Effects of continuous infusion of PTH on experimental tooth movement in rats. *J Bone Miner Res.* 1999;14(4):546-54.
18. Mangal U. Influence of platelet-rich plasma on orthodontic tooth movement: A review. *Biomed Pharmacol J.* 2017;10(3):1463-8.
19. Suaid FF, Carvalho MD, Santamaria MP, Casati MZ, Nociti FH Jr, Sallum AW, et al. Platelet-rich plasma and connective tissue grafts in the treatment of gingival recessions: a histometric study in dogs. *J Periodont.* 2008;79(5):888-95.
20. Andrade I, Taddei SRA, Souza PEA. Inflammation and tooth movement: the role of cytokines, chemokines, and growth factors. *Semin Orthod.* 2012;18(4):257-69.
21. Liou EJW. The development of submucosal injection of platelet-rich plasma for accelerating orthodontic tooth movement and preserving pressure side alveolar bone. *APOS Trends Orthod.* 2016;6(1):5-11.
22. Rashid A, ElSharaby FA, Nassef EM, Mehanni S, Mostafa YA. Effect of platelet-rich plasma on orthodontic tooth movement in dogs. *Orthod Craniofac Res.* 2017;20(2):102-10.
23. Güleç A, Bakkalbaşı BÇ, Cumbul A, Uslu Ü, Alev B, Yarat A. Effects of local platelet-rich plasma injection on the rate of orthodontic tooth movement in a rat model: a histomorphometric study. *Am J Orthod Dentofacial Orthop.* 2017;151(1):92-104.
24. Akbulut S, Yagci A, Yay AH, Yalcin B. Experimental investigation of effects of platelet-rich plasma on early phases of orthodontic tooth movement. *Am J Orthod Dentofacial Orthop.* 2019;155(1):71-9.
25. El-Timamy A, El Sharaby F, Eid F, El Dakroury A, Mostafa Y, Shagr O. Effect of platelet-rich plasma on the rate of orthodontic tooth movement: a split-mouth randomized trial. *Angle Orthod.* 2020;90(3):354-61.
26. Cardaropoli G, Araujo M, Lindhe J. Dynamics of bone tissue formation in tooth extraction sites. *J Clin Periodontol.* 2003;30(9):809-18.
27. Albanese A, Licata ME, Polizzi B, Campisi G. Platelet-rich plasma (PRP) in dental and oral surgery: from the wound healing to bone regeneration. *Immun Ageing.* 2013;10(1):21-3.
28. Chahla J, Cinque ME, Piuze NS, Mannava S, Geeslin AG, Murray IR, et al. A call for standardization in platelet-rich plasma preparation protocols and composition reporting: a systematic review of the clinical orthopaedic literature. *Bone Joint Surg Am.* 2017;99(20):1769-79.
29. Whitman DH, Berry RL, Green DM. Platelet gel: an autologous alternative to fibrin glue with applications in oral and maxillofacial surgery. *J Oral Maxillofac Surg.* 1997;55(11):1294-9.

30. Seidel SR, Vendruscolo CP, Moreira JJ, Fülber J, Ottaiano TF, Oliva ML, et al. Does double centrifugation lead to premature platelet aggregation and decreased TGF- β 1 concentrations in equine platelet-rich plasma? *Vet Sci.* 2019;6(3):68.
31. Kobayashi Y, Takagi H, Sakai H, Hashimoto F, Mataka S, Kobayashi K, et al. Effects of local administration of osteocalcin on experimental tooth movement. *Angle Orthod.* 1998;68(3):259-66.
32. Leiker BJ, Nanda RS, Currier GF, Howes RI, Sinha PK. The effects of exogenous prostaglandins on orthodontic tooth movement in rats. *Am J Orthod Dentofacial Orthop.* 1995;108(4):380-8.
33. Ali TM, Chawshli OF. The effect of submucosal injection of plasma-rich platelets on the rate of orthodontically induced canine retraction in subjects with bimaxillary Protrusion. *Sulaimani Dent J.* 2020;7(2):70-80.