

## Comparison of Bacterial Cellulose and Acellular Dermal Matrices Seeded with Fibroblasts versus Free Gingival Grafts: A Randomized Animal Study

Giulia Romano<sup>1\*</sup>, Marco Bianchi<sup>1</sup>, Paolo Conti<sup>2</sup>

<sup>1</sup>Department of Orthodontics and Biomaterials Engineering, Faculty of Dentistry, University of Milan, Milan, Italy.

<sup>2</sup>Department of Periodontology and Dental Tissue Engineering, Faculty of Dentistry, University of Bologna, Bologna, Italy.

\*E-mail ✉ [giulia.romano@outlook.com](mailto:giulia.romano@outlook.com)

Received: 29 September 2024; Revised: 28 November 2024; Accepted: 04 December 2024

### ABSTRACT

Mucogingival defects (MGDs), such as dental root recessions, decreased vestibular depth, and absence of keratinized tissues, are commonly seen in dental clinics. MGDs may result in functional, aesthetic, and hygienic concerns. In these situations, autogenous soft tissue grafts are considered the gold-standard treatment. This study compares the healing process of free gingival grafts (FGGs) to bacterial cellulose matrix (BCM) and human acellular dermal matrix (ADM) seeded with fibroblasts from culture supplemented with platelet-rich plasma in a rat model. Surgical defects were made in rats, which received the following treatments in a randomized manner: group I, negative control (defect creation only); group II, positive control (FGG); group III, BCM; group IV, BCM + fibroblasts; group V, ADM; and group VI, ADM + fibroblasts. Clinical, histological, and immunological analyses were performed 15 days after grafting. Clinical examinations recorded epithelium regularity and the presence of ulcers, erythema, and/or edema. The histological analysis revealed the degree of reepithelization, width, regularity, and presence of keratin. The Fisher exact statistical test was applied to the results ( $P < 0.05$ ). No groups showed ulcers except for group I. All groups had regular epithelium without erythema and without edema. Histologically, all groups exhibited regular epithelium with keratinization, and myofibroblasts were present in the connective tissue. The groups that received engineered grafts showed similar clinical and histological results to the FGG group. Within the limitations of this study, it was concluded that BCM and ADM can be used as cell scaffolds, with ADM yielding the best results. This study supports the use of this technical protocol in humans.

**Keywords:** Cellulose, Cultured cells, Fibroblasts, Animal study

**How to Cite This Article:** Romano G, Bianchi M, Conti P. Comparison of Bacterial Cellulose and Acellular Dermal Matrices Seeded with Fibroblasts versus Free Gingival Grafts: A Randomized Animal Study. *J Orthod Periodontal Biomater Res.* 2024;4(2):124-34. <https://doi.org/10.51847/xjuKODxHHF>

### Introduction

Mucogingival defects (MGDs), such as dental root recessions, decreased vestibular depth, and absence of keratinized tissues, are commonly seen in the dental clinic. MGDs may result in functional, aesthetic, and hygienic concerns. In these situations, autogenous soft tissue grafts are considered the gold-standard treatment [1].

The use of autogenous grafts (AGs) results in increased morbidity and discomfort to the patient due to the need for an additional surgical site to harvest the graft. There is also an increased risk of bleeding from the donor site, difficulty in standardizing tissue thickness, and color/thickness differences, which may result in an aesthetic challenge and limit graft quantity [2-8].

Thus, a less invasive reconstructive technique has been sought. To this end, tissue engineering aims to create a scaffold of absorbable or non-absorbable material, capable of storing cells and growth factors that may assist in the development of the lost tissues [9]. This technique can be used in the fields of periodontics and implant

dentistry [10-15]. When using allografts for the purpose of restoring periodontal soft tissues (gingiva and periodontal ligament), it is necessary to acquire adequate cells. Gingival fibroblasts are fundamental in the fabrication/maintenance of the periodontal tissues [16]. Prato *et al.* [17] seeded fibroblasts on a matrix of hyaluronic acid and used this combination graft in a human clinical case series. This experimental technique was successful, as demonstrated by the clinical observation of restored keratinized mucosa and histological findings [17].

Fibroblasts are responsible for the fabrication and maintenance of extracellular matrix (ECM) and the production of periodontal collagen fibers. The manipulation and cultivation of these cells allow the establishment of a suitable and viable culture method for the development of a cellular scaffold. It is typical to use fetal bovine serum (FBS) in cell culture. However, aiming at the use of this technique in humans, in this study FBS was replaced by platelet-rich plasma (PRP) for the purpose of medium supplementation. The influence of progressively high concentrations of PRP on human osteoblast proliferation was evaluated [18]. PRP-supplemented culture medium showed higher osteoblast proliferation when stimulated by 50% PRP dilution, with or without FBS. The conclusion of that study was that PRP promotes osteoblast proliferation, suggesting that it could be applied clinically to bone graft procedures in implant dentistry.

Bacterial cellulose matrix (BCM) (Jadam Co., Jeju, Korea) and human acellular dermal matrix (ADM) (SureDerm™; Hans Biomed Corp., Seoul, Korea) have been used for wound dressings and temporary skin replacement in the treatment of burns and ulcers, at graft sites, and as an aid in cases of dermal abrasion [19-22]. When the matrix is applied subcutaneously on the dorsum of wild-type mice, it supports cell infiltration and undergoes progressive remodeling, forming functional tissue without activation of the immune response [23].

Wound closure may occur by means of regeneration or repair. Regeneration results in newly formed tissue, fully reproducing the tissue architecture and function after an injury. Repair is a process that results in a scar, which is a disorganized cluster of ECM that, despite closing the lesion, does not reconstruct the original tissue characteristics. The repair process is divided into 3 phases: inflammation, proliferation, and remodeling. In the inflammation phase, coagulation factors are present. In the proliferation phase, wound reepithelization, granulation tissue formation, and angiogenesis occur, and fibroblasts differentiate into myofibroblasts (contractile cells that tend to close the wound) at the edges of the lesion. In the remodeling phase, tissue organization and keratin production take place [24].

In light of the above information, and since there are very few studies in this field, the aim of this study was to compare the healing process of free gingival grafts (FGGs) to BCM and ADM seeded with fibroblasts grown in PRP-supplemented medium in a rat model. The null hypothesis was that all 3 procedures would show similar healing patterns.

## Materials and Methods

### *PRP medium supplementation*

Whole blood was collected from 10 rats to fabricate the PRP used to supplement the culture medium. Venipuncture was conducted using minimal trauma to avoid triggering platelet factors, facilitating platelet adhesion, agglutination, and aggregation. Next, the blood was centrifuged [25]. The total blood collected from each rat was contained in a receptacle with citrate phosphate dextrose adenine, resulting in an approximate volume of 20 mL from each rat.

### *Fibroblast primary culture*

Tissue harvesting was conducted with the animals placed in the prone position, with their heads immobilized at 2 fixed points on a stereotactic table. A 5 mm<sup>2</sup> (2.5×2.0 mm) biopsy of keratinized mucosa (epithelium and connective tissue) of the palatal region was performed under ketamine sedation after 0.12% chlorhexidine disinfection. The samples were used for primary fibroblast culture. Samples were processed under a laminar flow hood (VECO, Campinas, SP, Brazil) at room temperature, between 25°C and 28°C, in a type P2 safety laboratory. The rat oral mucosa tissue samples were washed twice with phosphate-buffered saline (PBS), and subsequently the epithelial tissue was removed and fragmented into 5 explants of approximately 1 mm<sup>2</sup>.

The explants were incubated at 37°C, 5% CO<sub>2</sub> with 2 mL of Dulbecco's modified Eagle medium (DMEM) culture medium supplemented with PRP. Cell growth was checked daily using an inverted phase microscope (×40 to ×200; Olympus, Tokyo, Japan). When approximately 70% confluence was found, the cells were trypsinized to

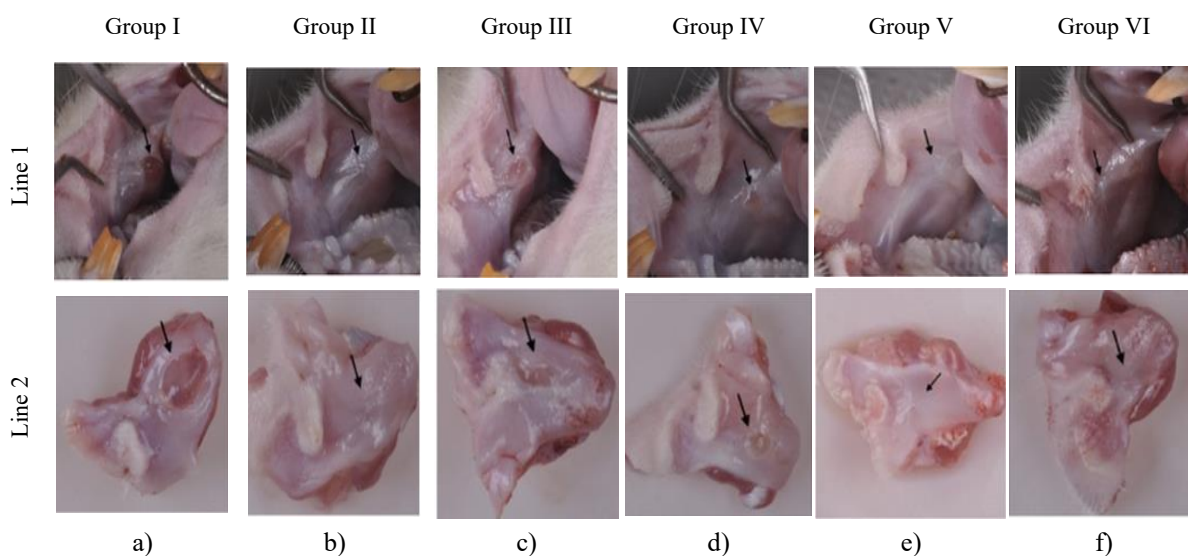
dissociate them, and this primary culture yielded a new 1:1 subculture. In this first passage, the explants were removed. The trypsin was inactivated by adding supplemented DMEM culture medium. Next, the flasks were re-incubated until the new sub-confluence was reached.

#### *Cell viability test*

An MTS calorimetric assay was used to assess fibroblast metabolic activity after 48 hours of incubation. inverted phase microscopy was used to observe fibroblasts growth. Absorbance was determined at 490 nm in a Spectramax spectrophotometer (Molecular Devices, San Jose, CA, USA). The positive control group consisted of cells cultured in a tissue culture flask (TPP®; Sigma-Aldrich, St. Louis, MO, USA). Cell counting was performed using.

#### *Ethical considerations*

The research was approved by the Animal Ethics Committee (PP00908) and followed the ARRIVE guidelines. Twenty rats were selected for blood collection (for PRP preparation) and gingival tissue biopsy. Graft surgery was performed in the other 50 rats (**Figure 1**).



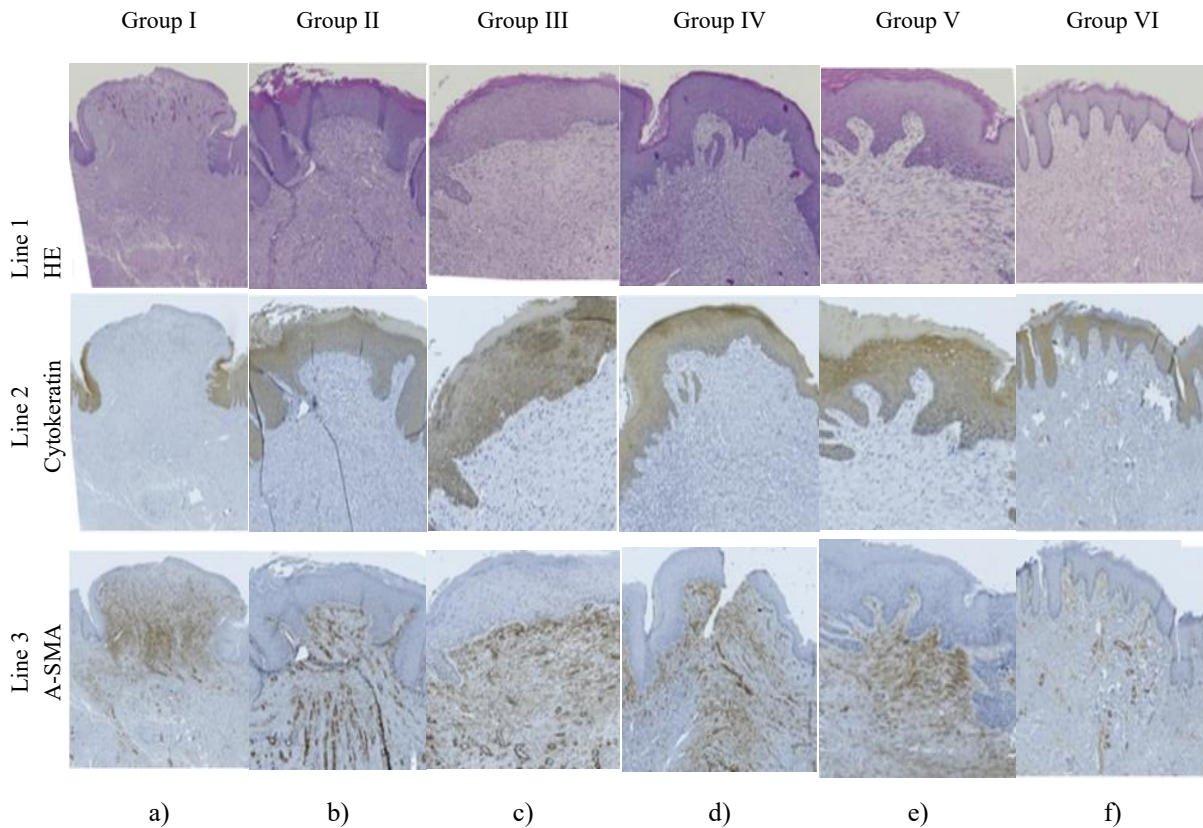
**Figure 1.** Selected clinical images of 20 rats were selected for blood collection procedures (for PRP preparation) and gingival tissue biopsy. Graft surgeries were performed in the other 50 rats. After whole blood was collected from 10 rats for fabrication of PRP used to supplement culture media. At 15-day post-operatively, clinical images were taken. (a) Group I, negative control, no grafting of the surgical site; (b) Group II, positive control, FGG; (c) Group III, BCM; (d) Group IV, BCM + fibroblasts; (e) Group V, ADM; and (f) Group VI, ADM + fibroblasts. Arrow indicates surgical wound and grafted site. Surgical site was created in proximity to the lip commissure. Note that in some images, it is harder to identify the operated site due to the advanced healing. Images indicate the following: Line 1, Frontal view of the surgical site. Direct image of the mucosa. Arrows indicating graft position; Line 2, Frontal view of the sample harvested after biopsy. Arrows indicating graft position. PRP: platelet-rich plasma, FGG: free gingival graft, BCM: bacterial cellulose matrix, ADM: acellular dermal matrix.

#### *Grafting procedures*

The grafting procedure was conducted in the buccal mucosa; therefore, the grafting technique was adapted to the site. The surgical procedure is described as follows. The animals were anesthetized with 25 mg/kg ketamine hydrochloride (Dopalen, Sespo Indústria e Comércio, Paulínia, Brazil) via an intra-muscular injection. Next, intra-oral asepsis was conducted using 0.2% chlorhexidine digluconate. The incisions were made using Bard-Parker 15C blades. A circular blade measuring 8 mm in diameter was used to delimit the recipient site starting 3 mm from the labial commissure of the rat's buccal mucosa. After preparing the recipient site, a partial-thickness flap was raised, exposing the connective tissue. Standardized circular defects were made bilaterally in the jugular mucosa, and group allocation was performed randomly. Group I only received the defects without any coverage.

Group II received an FGG from the palate. In groups III, IV, V, and VI, scaffolds were sutured over the surgical wound.

The following technique was used to obtain the FGG. At the donor site, the same circular blade was used to harvest the graft. A Bard-Parker 15C blade was used with an approximate depth of 1.5 mm over the lines marked by the circular blade. The graft was dissected from the donor site. Irregularities and adipose tissues were removed from the graft, adjusting the graft's thickness. The suture technique was the same as used for the FGG and the remaining groups. The graft was positioned in the recipient site and stabilized using 5-0 thread to make an anterior and a posterior simple interrupted suture. Due to the rat's limited mouth opening, all grafts were stabilized with 2 simple interrupted sutures using 5-0 nylon thread (**Figure 2**). Finally, digital compression was performed over the graft for 3 minutes.



**Figure 2.** Selected clinical images of 20 rats were selected for blood collection procedures (for PRP preparation) and gingival tissue biopsy. Graft surgeries were performed in the other 50 rats. After whole blood was collected from 10 rats for fabrication of PRP used to supplement culture media. At 15-day post-operatively, histological and immunohistochemistry sections were obtained from the samples biopsied and stained. (a) Group I, negative control, no grafting of the surgical site; (b) Group II, positive control, FGG; (c) Group III, grafting with BCM; (d) Group IV, grafting with BCM + fibroblasts; (e) Group V, grafting with ADM; and (f) Group VI, grafting with ADM + fibroblasts. Images indicate the following: Line 1, Immunohistochemistry for Cytokeratin marker, which marks epithelial cells. These cells are in brown. The other cells are in blue; Line 2, Immunohistochemistry with  $\alpha$ -SMA marker, which marks myofibroblasts and neovasculature. This cells are in brown. The other cells are in blue; Line 3, Immunohistochemistry with  $\alpha$ -SMA marker, which marks myofibroblasts and neovasculature in brown.

PRP: platelet-rich plasma, FGG: free gingival graft, BCM: bacterial cellulose matrix, ADM: acellular dermal matrix, HE: hematoxylin and eosin,  $\alpha$ -SMA: alpha-smooth muscle actin.

The animals were kept in cages, with 4 animals in each cage. The cages were stored in the University of Santa Catarina's Biological Unit facility, where the temperature and humidity were controlled. The animals were fed

daily with food and water *ad libitum*. In the first 3 post-operative days, they were fed a softer diet. The hardwood chip bedding in the animal cages was changed every 2 days.

#### *Randomization*

All animals were anesthetized and numbered with a tail tag. Tag numbers from 1 to 10 were placed inside a box. These tags were removed from the box by the operator and randomly distributed to each animal, which received three procedures. The randomization process followed a given sequence generated by an online website (Sealed Envelope Ltd., London, UK; 2017). The first randomized procedure was to be performed on the right and left sides of each rat. The sequence of animals operated started in group I and followed the rats' tag numbers, from 1 to 10. The rats were randomly divided into 6 groups: group I: negative control (n=12); group II: positive control (n=14); group III: BCM (n=16); group IV: fibroblasts in BCM (n=10); group V: ADM (n=8); and group VI: fibroblasts in ADM (n=6). Due to the deaths of some rats, some groups showed a different total number.

#### *Clinical evaluation*

Fifteen days after graft surgery, the animals were sedated for clinical and photographic evaluation. The clinical evaluation of the operated area considered the regularity of the epithelium and the presence or absence of ulcers, edema, and flushing. All information was tabulated and the predominant characteristics in each group were analyzed.

#### *Histological processing*

At 5 days post-operatively, a biopsy was performed, removing a margin of untouched host tissue, and the explants were fixed in 10% buffered formalin for 48 hours. Next, the pieces were evaluated macroscopically, the explants were trimmed, and the specimens were removed, and a longitudinal cut was made to establish the inclusion profile of the grafted site. Afterward, the explants underwent histological processing and analysis, and 3- $\mu$ m-thick sections were obtained for hematoxylin and eosin staining. Images were taken of the operated site.

#### *Immunohistochemical processing*

At 5 days post-operatively, immunohistochemical processing was conducted with the biopsy samples. The manufacturer's guidelines were followed for each antibody used, and positive/negative controls were used for each reaction. The antibodies used were alpha-smooth muscle actin ( $\alpha$ -SMA) (Dako North America, Carpinteria, CA, USA), for identifying myofibroblasts in the sample's connective tissue, and pan-cytokeratin AE1/AE3 (Santa Cruz Biotechnology, Dallas, TX, USA), for identifying epithelial cells at the repair site if keratin was present. Reaction amplification was conducted using the EasyLink One kit (EasyPath, São Paulo, SP, Brazil). After mounting, the slides were kept in an oven (40°C) for at least 24 hours before being examined under a light microscope. The histology and immunohistochemistry were analyzed.

#### *Histological/immunohistochemical analysis*

The slides were scanned with an AXIO SCAN Z.1 slide scanner (Zeiss, Köln, NRW, Germany) and analyzed by a previously calibrated observer using the AxionVision image analysis program (Zeiss). Next, the grafted site was identified and analyzed for the presence of complete reepithelization or ulcerations. The epithelium was classified as thin (1 to 3 cell layers) or regular (4 or more epithelial cell layers). The presence or absence of epithelial ridges and keratin (pan-cytokeratin) were evaluated. Blood vessels, inflammatory cells, and myofibroblasts ( $\alpha$ -SMA) were counted within the same area ( $\times 20$  magnification), and their presence was classified as mild (less than 20 cells), regular (20 to 60 cells) and intense (60 or more cells) (**Figure 2**). The Fisher exact test was used to verify statistical significance within each group ( $P < 0.05$ ). The kappa test was performed for examiner calibration.

## **Results and Discussion**

The results of this study are described in the tables, organized by the relevant criteria. Clinical evaluations are presented in **Table 1**. Immunohistochemical and histological evaluations are presented in **Table 2**. All the data obtained can be seen and compared among the groups using the tables. The main comparisons are described in the Discussion section.

**Table 1.** Results of the clinical evaluation of the groups

| Groups    | Epithelium |         |                 |                 | Erythema        |                 | Edema           |                 |
|-----------|------------|---------|-----------------|-----------------|-----------------|-----------------|-----------------|-----------------|
|           | Absent     | Present | Irregular       | Regular         | Absent          | Present         | Absent          | Present         |
| Group I   | 10         | -       | -               | -               | -               | 10              | -               | 10              |
| Group II  | -          | 10      | 1 <sup>a)</sup> | 9 <sup>b)</sup> | 9 <sup>a)</sup> | 1 <sup>b)</sup> | 9 <sup>a)</sup> | 1 <sup>b)</sup> |
| Group III | -          | 10      | 5 <sup>a)</sup> | 5 <sup>a)</sup> | 5 <sup>a)</sup> | 5 <sup>a)</sup> | 5 <sup>a)</sup> | 5 <sup>a)</sup> |
| Group IV  | -          | 10      | 4 <sup>a)</sup> | 6 <sup>a)</sup> | 6 <sup>a)</sup> | 4 <sup>a)</sup> | 6 <sup>a)</sup> | 4 <sup>a)</sup> |
| Group V   | -          | 10      | 3 <sup>a)</sup> | 7 <sup>a)</sup> | 10              | -               | 7 <sup>a)</sup> | 3 <sup>a)</sup> |
| Group VI  | -          | 10      | -               | 10              | 10              | -               | 10              | -               |

The evaluated criteria were presence of ulcer (absence of epithelium), regularity of the epithelium, presence of erythema, and presence of edema. The numbers represented quantity of the samples with the same characteristics. The results were statistically analyzed using the exact Fisher's test. All the analyzed criteria showed statistically significant values ( $P<0.05$ ). Statistical difference was expressed within the groups. Subjects were randomly divided into 6 groups: group I, negative control; group II, positive control; group III, BCM; group IV, BCM + fibroblasts; group V, ADM; and group VI, ADM + fibroblasts.

BCM: bacterial cellulose matrix, ADM: acellular dermal matrix.

<sup>a,b)</sup> Groups that showed different letters (a, b) presented a predominant characteristic, the one present in the majority of each of the groups. Groups that showed the same letters (a, a), did not present statistical significance. The groups that did not have letters, presented only one characteristic that was predominant in that group.

**Table 2.** Histological results

| Groups    | Epithelium |         | Epithelium width |                 | Epithelium ridges |                 | Inflammatory infiltrate |                 |
|-----------|------------|---------|------------------|-----------------|-------------------|-----------------|-------------------------|-----------------|
|           | Absent     | Present | Thin             | Regular         | Absent            | Present         | Regular                 | Intense         |
| Group I   | 10         | -       | -                | -               | 10                | -               | -                       | 10              |
| Group II  | -          | 10      | 5 <sup>a)</sup>  | 5 <sup>a)</sup> | 5 <sup>a)</sup>   | 5 <sup>a)</sup> | 5 <sup>a)</sup>         | 5 <sup>a)</sup> |
| Group III | -          | 10      | 9 <sup>b)</sup>  | 1 <sup>a)</sup> | 4 <sup>a)</sup>   | 6 <sup>a)</sup> | 5 <sup>a)</sup>         | 5 <sup>a)</sup> |
| Group IV  | -          | 10      | 7 <sup>a)</sup>  | 3 <sup>a)</sup> | 2 <sup>a)</sup>   | 8 <sup>a)</sup> | 9 <sup>a)</sup>         | 1 <sup>a)</sup> |
| Group V   | -          | 10      | 3 <sup>a)</sup>  | 7 <sup>a)</sup> | 1 <sup>a)</sup>   | 9 <sup>a)</sup> | 9 <sup>a)</sup>         | 1 <sup>a)</sup> |
| Group VI  | -          | 10      | -                | 10              | -                 | 10              | 10                      | -               |

The evaluated criteria were the presence of epithelium, thickness of the epithelium (thin or regular), presence of epithelial crests and quantity of inflammatory infiltrate (regular or intense). The numbers represent the quantity of the samples with the same characteristic. The results were statistically analyzed using the exact Fisher's test. All the analyzed criteria showed statistically significant values ( $P<0.05$ ). Statistical difference was expressed within the groups. Subjects were randomly divided into 6 groups: group I, negative control; group II, positive control; group III, BCM; group IV, BCM + fibroblasts; group V, ADM; and group VI, ADM + fibroblasts.

BCM: bacterial cellulose matrix, ADM: acellular dermal matrix.

<sup>a,b)</sup> Groups that showed different letters (a, b) presented a predominant characteristic, the one present in the majority of each of the groups. Groups that showed the same letters (a, a), did not present statistical significance. The groups that did not have letters, presented only one characteristic that was predominant in that group.

### Statistical analysis

The sample size was calculated using the formula:

$$n_0 = Z^2 \times p \times (1-p) / d \quad n_0 \neq n \quad Z \neq z, \quad (1)$$

where  $n$  = the sample size at time 0,  $z$  = the  $z$  value (also called the standard value),  $p$  = standard deviation, and  $d$  = the margin of error. Seventy healthy young-adult (20–24 weeks) male rats (*Rattus norvegicus albinus*; Wistar, Philadelphia, PA, USA) weighing 180 g on average, were used in the *in vivo* portion of this study. In the *in vitro* analysis, the kappa test result was 0.845. Statistically significant intragroup results were obtained for all characteristics evaluated ( $P<0.05$ ). Different letters are used to show the presence of a significantly predominant

characteristic in certain groups, while the same letters are used to indicate an even distribution of characteristics, with no predominance in specific groups (**Tables 1 and 2**).

As shown in **Table 1**, which presents details on clinical parameters, ulcers were only found in group I. Groups II, IV, V, and VI did not present ulcers. Groups II and VI presented regular epithelium at the operated site. Groups IV and V showed a non-statistically significant tendency for a regular epithelium. Erythema was present in group I and absent in groups II, V, and VI. Edema was present in group I and absent in groups II and VI. Group I presented ulcers, erythema, and edema clinically. Group II presented regular epithelium and an absence of ulcers, erythema, and edema. Ulcers were absent in group III. Group IV did not present ulcers. Group V presented an absence of ulcers and erythema. Group VI presented clinically regular epithelium and an absence of ulcers, erythema, and edema (**Table 1**).

As presented in **Table 2**, the histological analysis revealed that ulcers were only present in Group I, which did not show epithelial ridges or keratin, but there was a large amount of inflammatory infiltrate and blood vessels, as well as a regular amount of myofibroblasts. Group II presented keratinized epithelium and a tendency for a high concentration of myofibroblasts. Group III presented thin epithelium, inflammatory infiltrate, and blood vessels. Group IV presented epithelium with keratin and inflammatory infiltrate and blood vessels in the connective tissues, as well as a large amount of myofibroblasts. Group VI showed regular epithelium. Epithelial ridges were absent in group I and present in group VI. Group II presented split results (50% with epithelial ridges). Groups III, IV, and V showed a tendency for epithelial ridges, although it did not reach statistical significance. Inflammatory infiltrate was present in all groups, with a high concentration in group I and a regular concentration in group VI. Groups II and III presented split results (50% with regular inflammatory infiltrate). Groups IV and V had a tendency for regular inflammatory infiltrate, but without statistical significance. Group V presented epithelium with keratin and myofibroblasts in large quantity, as well as epithelial ridges and a regular quantity of inflammatory infiltrate. Group VI presented regular epithelium with keratin and epithelial ridges, as well as a regular concentration of inflammatory infiltrate and blood vessels. In group VI, myofibroblasts were found in large quantities (**Table 2**).

As detailed in **Table 3**, the immunohistochemical analysis showed the presence of keratin in groups II, IV, V, and VI. Group I did not exhibit keratin. Blood vessels were present in all groups, with a high concentration in group I and a regular concentration in group VI. A non-statistically significant tendency was observed for groups II and III to have a large amount of blood vessels and for groups IV and V to have a regular amount. Myofibroblasts were present in all groups, with a regular amount in group I and an intense amount in groups IV, V, and VI. Groups II and III tended to have a large amount of myofibroblasts, albeit without statistical significance (**Table 3**).

**Table 3.** Results of the immunohistochemical evaluation

| Group     | Keratin         |                 | Blood vessels   |                 | Myofibroblasts  |                 |
|-----------|-----------------|-----------------|-----------------|-----------------|-----------------|-----------------|
|           | Absent          | Present         | Regular         | Intense         | Regular         | Intense         |
| Group I   | 10              | -               | -               | 10              | 10              | -               |
| Group II  | 2 <sup>a)</sup> | 8 <sup>a)</sup> | 5 <sup>a)</sup> | 5 <sup>a)</sup> | 2 <sup>a)</sup> | 8 <sup>a)</sup> |
| Group III | 4 <sup>a)</sup> | 6 <sup>a)</sup> | 3 <sup>a)</sup> | 7 <sup>a)</sup> | 3 <sup>a)</sup> | 7 <sup>a)</sup> |
| Group IV  | 2 <sup>a)</sup> | 8 <sup>a)</sup> | 7 <sup>a)</sup> | 3 <sup>a)</sup> | -               | 10              |
| Group V   | 1 <sup>a)</sup> | 9 <sup>a)</sup> | 7 <sup>a)</sup> | 3 <sup>a)</sup> | -               | 10              |
| Group VI  | -               | 10              | 10              | -               | -               | 10              |

The evaluated criteria were presence of keratin, expressed by the  $\alpha$ -SMA marker; quantity of blood vessels and myofibroblasts (regular or intense), expressed by the cytokeratin marker. The numbers represent the quantity of the samples with the same characteristic. The results were statistically analyzed using the exact Fisher's test. All the analyzed criteria showed statistically significant values ( $P < 0.05$ ). Statistical difference was expressed within the groups. Subjects were randomly divided into 6 groups: group I, negative control; group II, positive control; group III, BCM; group IV, BCM + fibroblasts; group V, ADM; and group VI, ADM + fibroblasts.

BCM: bacterial cellulose matrix, ADM: acellular dermal matrix,  $\alpha$ -SMA: alpha-smooth muscle actin.

<sup>a)</sup> Groups that showed different letters (a, b) presented a predominant characteristic, the one present in the majority of each of the groups. Groups that showed the same letters (a, a), did not present statistical significance. The groups that did not have letters, presented only one characteristic that was predominant in that group.

For many years, AGs have been successfully employed, but certain limitations have forced researchers to seek alternative grafting procedures to enhance patient comfort, site acceptability and compatibility. In the FGG technique, a second surgical site is required to harvest the donor tissue. This secondary site heals by secondary intention, which may increase post-operative pain and morbidity. FGGs often result in an unaesthetic appearance due to the behavior of the graft. In addition, AGs cannot be used to increase the gingival width in many cases due to the limitations of the donor sites [26].

The main outcome of this study was that all groups, except for group I, did not have ulcers. All groups had regular epithelium without erythema and without edema. Histologically, all groups exhibited regular epithelium with keratinization, and myofibroblasts were present in the connective tissue. The groups that received engineered grafts showed similar clinical and histological results to those of the FGG group.

No inflammatory responses were identified in any of the experimental or control groups, despite using blood in a homogenous manner to fabricate PRP. A possible reason for this finding may be the use of animals from an established and genetically mapped lineage, where the genetic variations between the animals are very minute.

In the present study, the negative control group presented unfavorable clinical results, such as the presence of ulcers, erythema, and edema. It also presented unfavorable histological results, with no epithelial ridges or keratin. It had a high concentration of inflammatory infiltrate and blood vessels, as well as a regular amount of myofibroblasts. These results corroborate previously reported findings in the literature [1], since in the negative group, no procedure was conducted to cover the surgical site; for this reason, it was expected that this group would show the longest delay before healing in this region. Therefore, it is ideal to cover oral lesions.

In the present study, the positive control group showed no ulcers, erythema, or edema. Histologically, it presented epithelium with a tendency to express keratin. A histological evaluation of the FGG healing process was detailed by Caffesse *et al.* [26] in rhesus monkeys. In that study, FGGs were placed at recipient sites with or without periosteum. The histological analysis of the FGGs on the periosteum at 14 days showed complete epithelialization with the development of the morphological characteristics of the attached gingiva. The findings of the present study agree with those of the 14-day histological analysis in the study of Caffesse *et al.* [26]. However, they did not show the presence of keratinization in the 14-day analysis, whereas the present study did show the presence of keratin in the samples collected at a 15-day time interval. Therefore, this is an inconsistency between the present study and the previous study. Some possible reasons are that 1) the samples in the present study were collected at 15 days post-operatively, whereas those in the previous study were collected a day earlier; and 2) the present study used a different animal model (namely, rats as compared to rhesus monkeys), and rats have a higher metabolic rate.

Group III (BCM), in the present study, did not show the presence of ulcers. However, it presented thin epithelium, inflammatory infiltrate, and blood vessels. BCM has several indications and is a relevant tool for various purposes, such as burn therapy and peri-implant tissue grafting. Our results concur with the literature that healing was predictable when BCM was used [4].

Clinically, group IV exhibited regular tissue without ulceration. Histologically, it presented keratinized epithelium, inflammatory infiltrate, and blood vessels in the connective tissue. It also contained a large amount of myofibroblasts. The presence of keratin is an important factor that should be highlighted, as it demonstrates that the BCM seeded with fibroblasts favored the formation of epithelial tissue. The large amount of myofibroblasts also indicates that the healing process for this group was more advanced than that of group III. There are no previous reports in the literature describing the use of this material with this specific cell culture technique, indicating a need for further research.

Group V showed similar results to the positive control group. Group V did not present ulcers or erythema. There was keratinized epithelium with a tendency for the presence of epithelial ridges, a regular amount of inflammatory infiltrate, and a high concentration of myofibroblasts. The literature also indicates the importance of permeability, with the presence of pores in the membranes in order to promote regeneration [27], which is a characteristic of the ADM. Studies have shown that ADM provides uniform thickness, easy handling, favorable adaptation, and a short rehydration time before its use [28]. ADM is not as effective as FGG in increasing the width of the grafted tissue, but its aesthetic results are more predictable, and it blends in with adjacent tissue [28]. The amount of grafted tissue acquired with ADM is clinically sufficient to prevent persistent inflammation [29]. ADM acts as a scaffold to allow the restocking of fibroblasts and blood vessels from the surrounding tissue epithelium, with later replacement by the host tissues [30].

Group VI presented promising results. In addition to its excellent clinical qualities, including a regular surface and absence of ulcers, edema, and erythema, this group had advanced histological healing, such as a regular epithelium, with an acceptable amount of keratinized tissue and well-defined and constant epithelial ridges, inflammatory infiltrate and blood vessels, and a high concentration of myofibroblasts. Group VI presented better clinical and histological results than the positive control group and the other groups. This could have been due to the presence of fibroblasts, which favor the healing process, especially when a direct comparison is made with group V (ADM without the presence of fibroblasts). There are no studies in the literature that would allow a direct comparison of this result. However, this finding shows great potential.

A limitation of this study is that 5 rats died during anesthesia and 4 died in the post-operative period. Three rats chewed off their tags and had to be excluded from the study. Due to the operation dates being different, the authors were able to add animals to some groups, but not to others. In addition, blood collection for the fabrication of autogenous PRP, as would be performed in a clinical scenario, was not possible due to the low amount of blood that we were permitted to collect from each animal.

The proposed techniques used for gingival grafting with PRP-supplemented primary fibroblast culture showed similar clinical and histological results to the gold-standard FGG technique. This study established a protocol to research the performance of soft tissue grafts in a rat model. The two matrices tested can be used as a scaffold for gingival tissue cells, with ADM being the most indicated matrix for FGGs in rat jugal mucosa. The use of fibroblasts obtained by primary culture positively influenced the repair process. Supplementation of the medium with PRP favored the healing process and could be used in humans.

The technical use of tissue engineering without culture medium supplementation from a different species avoids the risk of immunological responses or cross-contamination. These factors facilitate the clinical application of this method by using primary culture originating from the recipient. Therefore, genetic testing and the application of this technique to medium-size animals (e.g., minipigs) should be conducted prior to tests in humans.

## Conclusion

In conclusion, within the limitations of this study, the histological analysis showed that the groups exhibited very similar results, with a slight difference favoring group VI, which exhibited the characteristics of more mature tissue. This study shows alternative treatment options for contemporary clinical challenges. However, future studies should be performed with different healing periods, at other anatomical sites, and in other types of organisms to derive more concrete conclusions regarding the clinical and histological performance of these materials, combined with cell culture or not.

**Acknowledgments:** This research study was conducted in the Laboratory of Pain and Inflammation Neurobiology (LPIN) and the Laboratory of Integrated Technologies (LIT), and Laboratories of the Federal University of Santa Catarina. The Brazilian Ministry of Education funded a PhD student with the Coordination and Refinement of Superior Level Personnel (CAPES) scholarship. The authors would like to thank Mr. Raí Heidenreich for assistance with the animal surgery and Mr. Guilherme Colla for assistance with the cell culture.

**Conflict of interest:** None

**Financial support:** None

**Ethics statement:** None

## References

1. Clavero J, Lundgren S. Ramus or chin grafts for maxillary sinus inlay and local onlay augmentation: comparison of donor site morbidity and complications. *Clin Implant Dent Relat Res.* 2003;5(3):154–60.
2. Broome WC, Taggart EJ Jr. Free autogenous connective tissue grafting: report of two cases. *J Periodontol.* 1976;47(10):580–5.
3. Caffesse RG, Guinard EA. Treatment of localized gingival recessions. Part II. Coronally repositioned flap with a free gingival graft. *J Periodontol.* 1978;49(7):357–61.

4. Callan DP, Silverstein LH. Use of acellular dermal matrix for increasing keratinized tissue around teeth and implants. *Pract Periodontics Aesthet Dent.* 1998;10(6):731-4.
5. Dorfman HS, Kennedy JE, Bird WC. Longitudinal evaluation of free autogenous gingival grafts. *J Clin Periodontol.* 1980;7(4):316-24.
6. Edel A. The use of a free connective tissue graft to increase the width of attached gingiva. *Oral Surg Oral Med Oral Pathol.* 1975;39(3):341-6.
7. Haeri A, Serio FG. Mucogingival surgical procedures: a review of the literature. *Quintessence Int.* 1999;30(6):475-83.
8. Marx RE, Garg AK. Bone structure, metabolism, and physiology: its impact on dental implantology. *Implant Dent.* 1998;7:267-76.
9. Ueda M. Current status of tissue engineering industry in Japan and U.S. *Tanpakushitsu Kakusan Koso* 2000;45:2342-2347.
10. Breault LG, Fowler EB, Billman MA. Retained free gingival graft rugae: a 9-year case report. *J Periodontol.* 1999;70(4):438-40.
11. Hall WB. Present status of soft tissue grafting. *J Periodontol.* 1977;48(6):587-97.
12. Silverstein LH. Fundamentally changing soft tissue grafting. *Dent Today.* 1997;16(3):56-9.
13. Sullivan HC, Atkins JH. Free autogenous gingival grafts. I. Principles of successful grafting. *Periodontics.* 1968;6(3):121-9.
14. Kriegebaum U, Mildenerger M, Mueller-Richter UD, Klammert U, Kuebler AC, Reuther T. Tissue engineering of human oral mucosa on different scaffolds: in vitro experiments as a basis for clinical applications. *Oral Surg Oral Med Oral Pathol Oral Radiol.* 2012;114(5 Suppl):S190-8.
15. Ophof R, Maltha JC, Kuijpers-Jagtman AM, Von den Hoff JW. Implantation of tissue-engineered mucosal substitutes in the dog palate. *Eur J Orthod.* 2008;30(1):1-9.
16. Ten Cate AR. The fibroblast and its products. In: *Oral histology: development, structure and function.* Toronto: C.V. Mosby; 1989. p. 90-105.
17. Prato GP, Rotundo R, Magnani C, Soranzo C, Muzzi L, Cairo F. An autologous cell hyaluronic acid graft technique for gingival augmentation: a case series. *J Periodontol.* 2003;74(2):262-7.
18. Ferreira CF, Carriel Gomes MC, Filho JS, Granjeiro JM, Oliveira Simões CM, Magini RS. Platelet-rich plasma influence on human osteoblasts growth. *Clin Oral Implants Res.* 2005;16(4):456-60.
19. Fontana JD, de Souza AM, Fontana CK, Torriani IL, Moreschi JC, Gallotti BJ, et al. Acetobacter cellulose pellicle as a temporary skin substitute. *Appl Biochem Biotechnol.* 1990;24-25:253-64.
20. Sanchavanakit N, Sangrungraungroj W, Kaomongkolgit R, Banaprasert T, Pavasant P, Phisalaphong M. Growth of human keratinocytes and fibroblasts on bacterial cellulose film. *Biotechnol Prog.* 2006;22(4):1194-9.
21. Zhang X, Deng Z, Wang H, Yang Z, Guo W, Li Y, et al. Expansion and delivery of human fibroblasts on micronized acellular dermal matrix for skin regeneration. *Biomaterials.* 2009;30(14):2666-74.
22. Feng Y, Wang J, Ling S, Li Z, Li M, Li Q, et al. Differentiation of mesenchymal stem cells into neuronal cells on fetal bovine acellular dermal matrix as a tissue engineered nerve scaffold. *Neural Regen Res.* 2014;9(22):1968-78.
23. Rennert RC, Sorkin M, Garg RK, Januszyk M, Gurtner GC. Cellular response to a novel fetal acellular collagen matrix: implications for tissue regeneration. *Int J Biomater.* 2013;2013:527957.
24. Wynn TA, Vannella KM. Macrophages in tissue repair, regeneration, and fibrosis. *Immunity.* 2016;44(3):450-62.
25. Devereaux J, Nurgali K, Kiatos D, Sakkal S, Apostolopoulos V. Effects of platelet-rich plasma and platelet-poor plasma on human dermal fibroblasts. *Maturitas.* 2018;117:34-44.
26. Caffesse RG, Burgett FG, Nasjleti CE, Castelli WA. Healing of free gingival grafts with and without periosteum. Part I. Histologic evaluation. *J Periodontol.* 1979;50(11):586-94.
27. Rambo CR, Carminatti CA, Pitlovanciv AK, Antônio RV, Porto LM. Template assisted synthesis of nanofibrous cellulose membranes for tissue engineering. *Mater Sci Eng C.* 2008;28(3):549-54.
28. Shulman J. Clinical evaluation of an acellular dermal allograft for increasing the zone of attached gingiva. *Pract Periodontics Aesthet Dent.* 1996;8(2):201-8.

29. Harris RJ. Root coverage with a connective tissue with partial thickness double pedicle graft and an acellular dermal matrix graft: a clinical and histological evaluation of a case report. *J Periodontol.* 1998;69(11):1305-11.
30. Wei PC, Laurell L, Geivelis M, Lingen MW, Maddalozzo D. Acellular dermal matrix allografts to achieve increased attached gingiva. Part 1. A clinical study. *J Periodontol.* 2000;71(9):1297-305.