

## Periodontal Regeneration Induced by Activin/BMP-2 Chimera AB204 in a Buccal Dehiscence Model: A Pilot Study

Ahmed Mansour<sup>1\*</sup>, Omar Saeed<sup>1</sup>

<sup>1</sup>Department of Orthodontics and Dental Biomaterials, Faculty of Dentistry, Cairo University, Cairo, Egypt.

\*E-mail ✉ [ahmed.mansour@gmail.com](mailto:ahmed.mansour@gmail.com)

Received: 02 June 2024; Revised: 08 October 2024; Accepted: 12 October 2024

### ABSTRACT

A combination of activin and bone morphogenetic protein-2 (BMP-2), termed AB204, has been shown to improve osteogenic potential with fewer side effects than BMP-2 alone. This study was performed to evaluate the effect of AB204 on periodontal tissue regeneration in a dog buccal dehiscence model. Buccal dehiscence defects were created on the maxillary premolars (P1, P2, and P3) of 6 mongrel dogs. After 5 weeks, the dogs were randomly assigned to 1 of 3 groups: the control, collagen matrix (CM), and CM/AB204 groups. Grafting procedures were then performed. The dogs were sacrificed 8 weeks after the grafting procedure, and volumetric and histological analyses were conducted. The thickness of the buccal gingiva in the CM/AB204 group was greater than those in the other groups at 2 weeks ( $P<0.05$ ). The ridge width in the AB204/CM group exceeded the width in the other groups at 4 and 8 weeks; however, the difference was not statistically significant. Histological analysis revealed that the CM/AB204 group demonstrated the formation of new bone surrounded by newly formed periodontal ligament and cementum ( $P=0.035$ ). The combined application of CM and AB204 shows promise in facilitating the regeneration of periodontal attachment, including the formation of new bone, cementum, and periodontal ligament.

**Keywords:** AB204, Activin, Animal experimentation, Bone regeneration, Collagen, Dental cementum

**How to Cite This Article:** Mansour A, Saeed O. Periodontal Regeneration Induced by Activin/BMP-2 Chimera AB204 in a Buccal Dehiscence Model: A Pilot Study. J Orthod Periodontal Biomater Res. 2024;4(2):100-12. <https://doi.org/10.51847/dWaxEqb55d>

### Introduction

Bone morphogenetic protein-2 (BMP-2), a member of the transforming growth factor-beta (TGF- $\beta$ ) superfamily, is known to stimulate the formation of new bone and periodontal tissue in treated areas [1]. Nevertheless, the application of BMP-2 in periodontal regeneration is still under active investigation due to concerns about its safety and efficacy [2]. Several studies have been conducted with the goal of creating a substance that can regenerate bone as effectively as BMP-2, but with fewer undesirable side effects.

The application of a low concentration (50 or 100 mg/mL) of recombinant human BMP-2 (rhBMP-2) to the dentinal surface has been shown to enhance the formation of cementum-like tissue in the gingival connective tissue. However, the use of a high concentration (400 mg/mL) can lead to dentin resorption [3, 4]. While the application of rhBMP-2 to the dentinal surface inhibits epithelial downgrowth [5], it does not appear to stimulate early responses in periodontal ligament (PDL) cells in humans, which could potentially enhance periodontal regeneration [6].

A previous study demonstrated that AB204, a novel fusion protein composed of activin A and BMP-2, exhibits greater osteogenic activity than BMP-2 alone in both *in vitro* and *in vivo* models of bone defect repair [7]. Additionally, this treatment was associated with fewer adverse side effects [8]. The osteoblastic activity of AB204 is more sustained compared to that of rhBMP-2 [8, 9, 10], and it has the capacity to induce the differentiation of mesenchymal stem cells into osteoblasts, which are essential for bone formation [7, 10]. Preclinical studies of AB204 have shown promising results regarding its use in therapeutic applications for bone regeneration and

repair. In a study using a rat model with critical-sized bone defects, AB204 was found to promote bone regeneration and enhance mechanical properties, achieving comparable levels of tibial recovery with only one-tenth the dose of rhBMP-2 [7].

Collagen sponges are frequently utilized as carriers or scaffolds for BMP-2 in the fields of periodontal and bone tissue engineering [11, 12]. Collagen loaded with BMP-2 can induce the differentiation of mesenchymal stem cells into osteoblasts, thereby stimulating the regeneration of bone and periodontal tissues. Additionally, it may be applied to connective tissue sites for tissue repair or regeneration [13]. However, the application of collagen sponges in tissue engineering is limited by their relatively rapid degradation rate, which may impede the development of volume-stable tissues [14].

Collagen matrix (CM) has been increasingly utilized in the treatment of dehiscence defects for periodontal tissue regeneration in recent years [15, 16]. Compared to collagen sponges, CM has a more organized and structured composition, enabling it to serve as a barrier between the oral environment and the underlying tissues [17]. This property facilitates periodontal tissue regeneration and the formation of functional periodontal attachments [16]. Thus, CM enhances periodontal tissue regeneration by providing root coverage and leads to improved esthetic outcomes in patients when used as a stand-alone treatment for buccal dehiscence defects [18].

This study was performed to compare gingival thickness measurements obtained using CM alone with those acquired using a combination of CM and AB204 in a canine buccal dehiscence model. The comparison was conducted using 3-dimensional (3D) digital imaging, probe visibility testing, and histological analysis to assess the impact of AB204 on periodontal tissue regeneration.

## Materials and Methods

### *Animals*

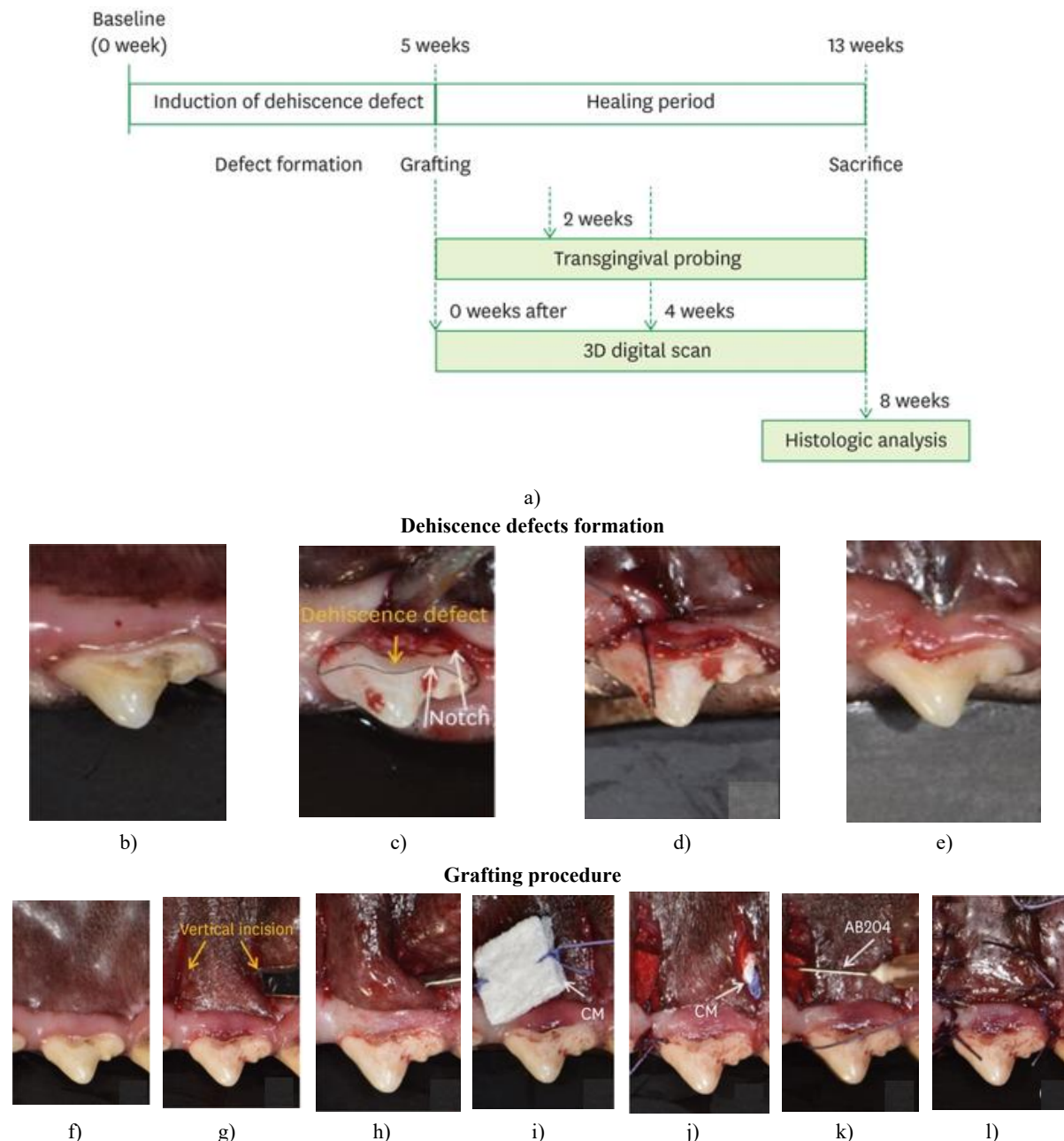
The study involved 6 male mongrel dogs, aged 10–12 months and weighing 31–35 kg. Each animal had a healthy periodontium and complete dentition. The sample size was established in accordance with a prior study [19], ensuring that each group contained a sufficient number of subjects while also minimizing the total number of animals required. The Institutional Animal Care and Use Committee of CRONEX in Seoul, Korea, granted approval for the study protocol (approval number: 202108009), in accordance with the ARRIVE guidelines for preclinical studies.

### *Material preparation*

The CM (Collagen Graft 2®; Genoss, Suwon, Korea) was derived from porcine type I crosslinked collagen. The activin/BMP-2 chimera (AB204; Darnatein, Incheon, Korea) and CM were either used independently or in combination; for the latter, the CM was dissolved in 0.2 mL of AB204 at a concentration of 50 µg/mL [20].

### *Study design*

Dehiscence defects were induced in the maxillary premolars of dogs by removing the buccal wall and cementum, as previously described [19, 21-23]. Five weeks later, the biomaterial was applied to the affected area (**Figure 1**). The dogs were allocated into 3 groups: the control group, which had the dehiscence defect induced but received no biomaterial graft; the CM group, which had the dehiscence defect induced and was grafted with CM; and the CM/AB204 group, which had the dehiscence defect induced and was grafted with CM containing 10 µg of AB204.



**Figure 1.** Experimental flowchart and clinical photographs of the surgical procedure. (a) Dehiscence defects were created in the maxillary premolars of dogs by removing the buccal wall and cementum. Biomaterial was applied to the defect area after 4 weeks. Transgingival probing was conducted using a probe at 0, 2, 4, and 8 weeks following the application of the biomaterial, and 3D scanning was carried out with an oral scanner at 0, 4, and 8 weeks after application. After 8 weeks, the animals were sacrificed to obtain specimens. (b-e) Formation of dehiscence defects. (b) Preoperative status. (c) Formation of a dehiscence defect after flap elevation. (d) Suturing of the flap. (e) Removal of the sutures at the maxillary second premolar after 2 weeks. (f-l) Grafting procedure. (f) Preoperative status. (g) Vertical incision at the interproximal region of the maxillary second premolar. (h) Elevation of a full-thickness mucoperiosteal flap. (i, j) Application of collagen matrix onto the dehiscence defect area. (k) Soaking of AB204 in the CM/AB204 group. (l) Suturing of the flap at the maxillary second premolar.

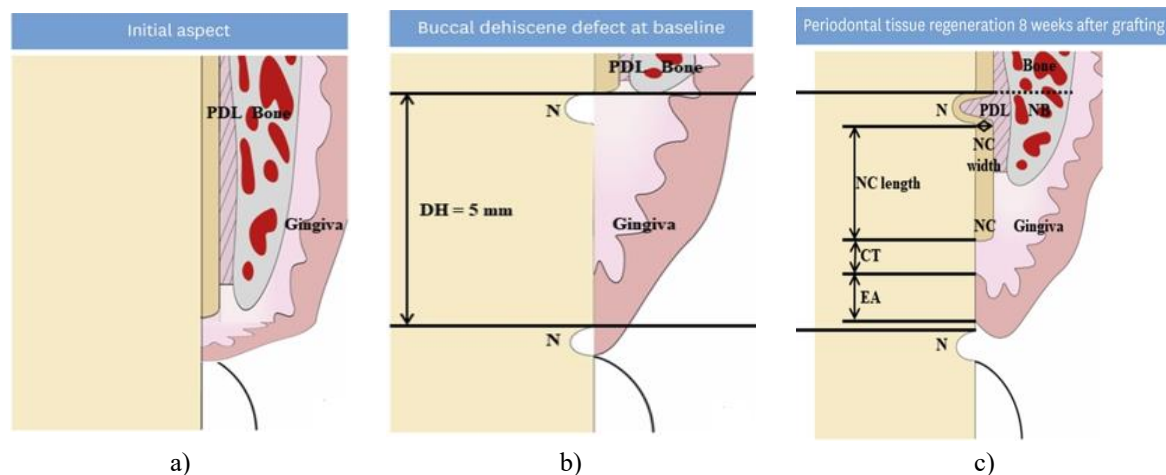
3D: 3-dimensional, CM: collagen matrix (Collagen Graft 2<sup>®</sup>), BMP-2: bone morphogenetic protein-2, AB204: Activin/BMP-2 Chimera.

Overall, 36 sites (6 experimental sites per dog) were allocated across the 6 dogs. A total of 12 sites were included for each of the maxillary premolars.

### *Surgical protocol*

The methods used in this study to create dehiscence defects and promote healing were largely consistent with those reported in previous research, with the exception of the bone graft materials and biomaterials [19]. The surgical procedures were performed under both general and local anesthesia. General anesthesia was initiated with a combination of Zoletil 50 (tiletamine hydrochloride/zolazepam hydrochloride; Virbac, Carros, France) and Rompun (xylazine hydrochloride; Bayer, Leverkusen, Germany). Inhalation anesthesia was maintained using a Terrell solution of isoflurane (Piramal Critical Care Inc., Seoul, Korea) and oxygen.

A 3D digital scan was acquired using a dental scanner (Medit, Seoul, Korea). Transgingival probing was conducted using a 25-mm K-file (#15; MANI, Inc., Tochigi, Japan) and digital calipers (CAS Co., Yangju, Korea) with the animals under general anesthesia. Standardized dehiscence defects, as shown in **Figures 1b-1e**, were created in the premolars by elevating a full-thickness mucoperiosteal flap through an intracrevicular incision (**Figure 1c**). The cementum was entirely removed, and horizontal notches were placed at the coronal and apical borders of the bony defects (**Figure 2c**). Sutures were removed after 2 weeks.



**Figure 2.** Schematic diagram of the buccal dehiscence defect and periodontal tissue regeneration. (a) Initial aspect. (b) Buccal dehiscence defect at baseline. (c) Periodontal tissue regeneration 8 weeks after grafting.

PDL: periodontal ligament, DH: defect height, NC: new cementum, NB: new bone height, CT: gingival connective tissue, EA: epithelial adhesion, N: notch.

A full-thickness mucoperiosteal flap was elevated on the buccal side of the premolars using a vertical incision (**Figure 1g**), following a 1-month healing period (**Figure 1f**). The keratinized portion of the buccal soft tissues was then tunneled mesiodistally, as previously described [24]. The biomaterial was applied to the defect area according to the assigned group (**Figure 1i-1k**), with the CM trimmed to a uniform size. Afterward, the mucoperiosteal flap was sutured using 3/0 Vicryl (Ethicon, Somerville, NJ, USA); (**Figure 1l**). Antibiotics were prescribed for 3 days postoperatively. Sutures were removed at the 2-week mark, and the animals were euthanized 8 weeks post-procedure for analysis of the left and right maxillae. The harvested specimens were then fixed in 10% neutral-buffered formalin for 10 days.

### *Analysis of 3D digital images*

The experimental site was scanned with a dental scanner (Medit) at each visit. The collected data were then analyzed using 3D measurement software (Geomagic Design X and Control X; 3D Systems, Rock Hill, SC, USA). For the analysis, scanned images were superimposed using the upper and lower notches as reference points. A 3D digital linear analysis was performed to assess changes in gingival thickness [25, 26].

The volumetric measurements were bisected by a transverse slice through the ridge, and the heights of the adjacent distal and mesial teeth were measured orthogonally from the longitudinal axis. Ridge widths were determined at various time points. Absolute ridge width was measured at 1, 3, and 5 mm beneath the upper border of the buccal notches, and the changes in ridge width over time were calculated.

### *Analysis of transgingival probing*

A #15 K-file, affixed with a rubber stop, was utilized to determine the vertical length at the measurement site. Additionally, a digital caliper was employed to measure the vertical length at the same site. For the premolars, the measurement site was established as 5 mm below the upper boundary of the upper notch.

#### *Analysis of the histological samples*

The extracted specimens were embedded in acrylic resin (Technovit 7200 VLC; Heraeus Kulzer GmbH, Wehrheim, Germany). The buccolingual sections were then sectioned to a thickness of 40 µm and stained with Goldner trichrome for histopathological analysis. Digital slide scans were acquired using a Panoramic 250 Flash III. An experienced investigator (H.S.H.) analyzed the data using computer software (Case Viewer).

As depicted in **Figure 2**, the length and width of the new cementum, the length of connective tissue adhesion, and the length of epithelial adhesion were measured. The lengths of the new cementum, connective tissue, and epithelial adhesion were quantified using a straight line parallel to the root surface. The width of the new cementum was measured perpendicularly from the root surface (**Figure 2c**). The area of new bone formation was determined by defining a region of interest as a 2×2 mm square located above the inferior notch.

#### *Statistical analysis*

All statistical analyses were performed using SPSS version 26.0 (IBM Corp., Armonk, NY, USA). The Shapiro–Wilk test was used to assess the normality of the distribution. Analysis of variance was used to evaluate normally distributed data, and the Kruskal–Wallis test was used to evaluate non-normally distributed data. *Post hoc* Bonferroni correction was used for multiple comparisons, and *P* values less than 0.05 were considered to indicate statistical significance.

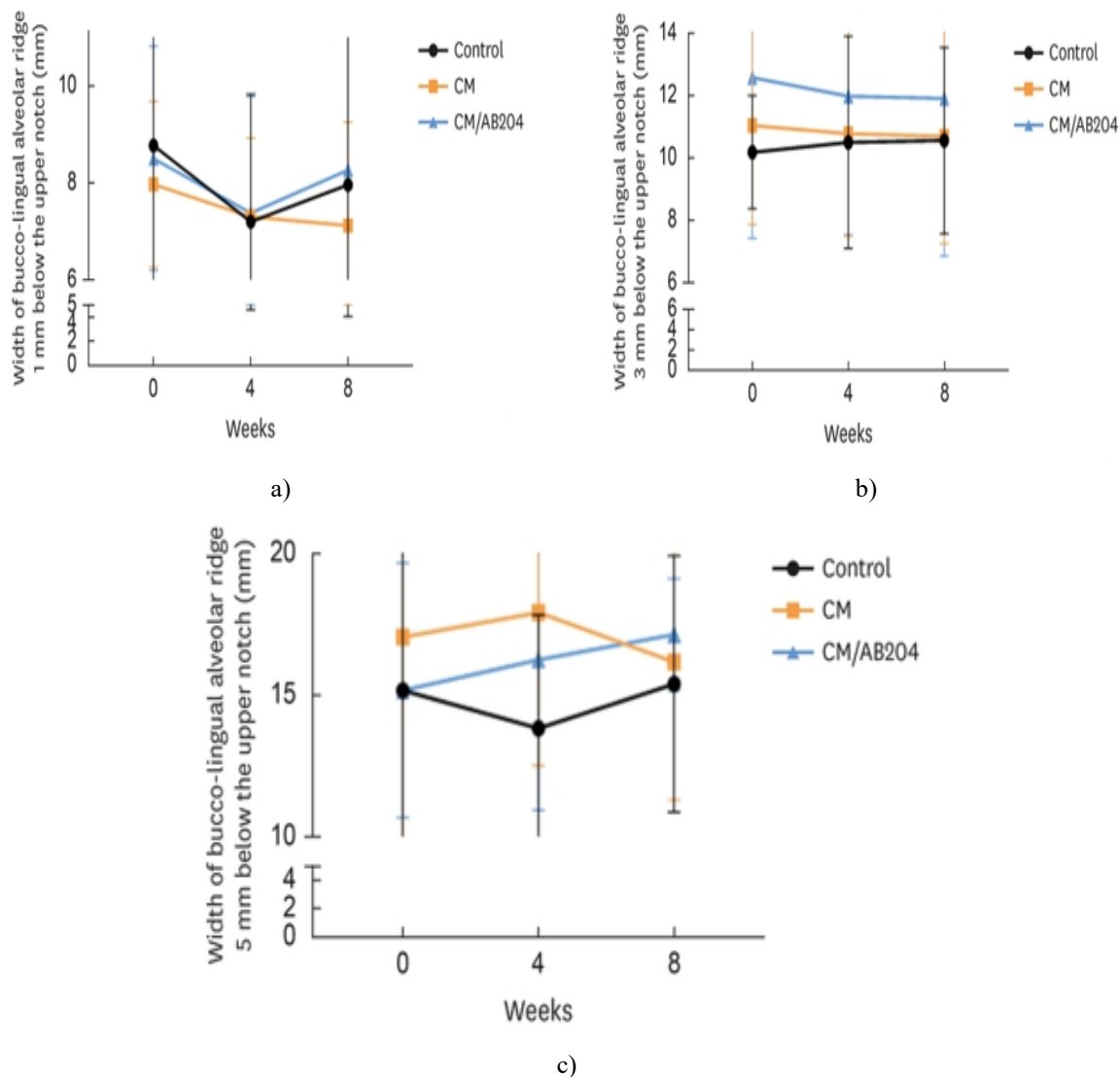
## **Results and Discussion**

#### *Clinical findings*

All animals remained healthy throughout the study period. No instances of systemic complications were observed.

#### *Analysis of the 3D digital images*

**Figure 3** presents the findings of the 3D analysis of the buccolingual ridge width over time. All groups exhibited a reduction in ridge width 1 mm below the upper notch from baseline to 4 weeks following the grafting procedure. Between 4 and 8 weeks after grafting, the control and CM/AB204 groups displayed a tendency for increased ridge width at the same level, in contrast to the CM group. At 3 mm below the upper notch, both the CM and CM/AB20 groups experienced a decrease in ridge width from baseline to 4 weeks post-grafting. However, by 8 weeks, the control and CM groups presented with comparable ridge widths. The CM/AB204 group, in contrast, maintained a larger ridge width at this location throughout the study period. At 5 mm below the upper notch, the control group's ridge width first decreased and then increased, while the CM group's ridge width showed the opposite pattern. The ridge width of the CM/AB204 group consistently increased. Despite these trends, no significant differences in ridge width were detected among the 3 groups at any measured distance from the upper notch, as shown in **Table 1**. After an 8-week healing period, the buccolingual alveolar ridge width in the CM/AB204 group was consistently greater than that of the other groups at all measured locations.



**Figure 3.** Results of the 3-dimensional volumetric analyses at different time points based on location. (a) Width of the buccolingual alveolar ridge 1 mm below the upper notch at 0, 4, and 8 weeks after grafting. (b) Width of the buccolingual alveolar ridge 3 mm below the upper notch at 0, 4, and 8 weeks after grafting. (c) Width of the buccolingual alveolar ridge 5 mm below the upper notch at 0, 4, and 8 weeks after grafting. CM: collagen matrix (Collagen Graft 2<sup>®</sup>), BMP-2: bone morphogenetic protein-2, AB204: Activin/BMP-2 Chimera.

**Table 1.** Bucco-lingual ridge width (mm) measured 3D digital analysis

Variables	Linear measurements (mm)			P value
	Control	CM	CM/AB204	
0 week (immediately after surgery)				
1 mm	8.78±3.63	7.98±1.71	8.51±2.31	0.94
3 mm	10.18±1.81	11.03±3.16	12.56±5.13	0.28
5 mm	15.17±6.18	17.05±7.93	15.18±4.49	0.69
4 weeks (change from 0 weeks)				
1 mm	7.21±2.63	7.31±1.62	7.39±2.40	0.79
	-1.57±1.88	-0.674±0.863	-1.12±1.93	0.48
3 mm	10.49±3.39	10.77±3.28	11.97±4.43	0.77

	0.305±2.47	-0.252±1.42	-0.588±1.68	0.82
5 mm	13.84±3.99	17.92±5.39	16.25±5.30	0.08 <sup>a)</sup>
	-1.33±5.61	0.871±6.67	1.07±2.16	0.65
8 weeks (change from 0 week)				
1 mm	7.97±3.92	7.13±2.13	8.27±2.85	0.52
	-0.807±1.24	-0.848±0.905	-0.242±2.29	0.58
3 mm	10.55±2.98	10.69±3.43	11.90±5.04	0.81
	0.368±2.23	-0.336±0.839	-0.662±2.91	0.86
5 mm	15.40±4.52	16.18±4.88	17.15±5.93	0.71
	0.236±6.12	-0.872±7.60	1.97±2.60	0.70

Values are presented as mean ± standard deviation.

3D: 3-dimensional, CM: collagen matrix (Collagen Graft 2<sup>®</sup>), BMP-2: bone morphogenetic protein-2, AB204: Activin/BMP-2 Chimera.

<sup>a)</sup> Statistically significant different at the same observation period (statistical significance level was 5%,  $P<0.05$ ).

#### Analysis of transgingival probing

Two weeks postoperatively, a significant difference was observed in the measured value of the buccal gingiva at 5 mm below the marginal gingiva among the 3 groups (control group: 4.46±0.88 mm, CM group: 5.04±1.03 mm, and CM/AB204 group: 5.45±1.03 mm;  $P<0.05$ ) (Table 2, Figure 4).

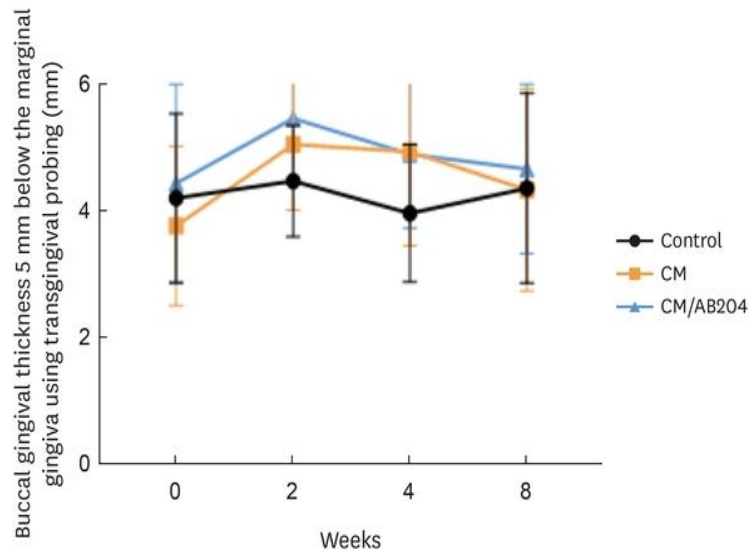
**Table 2.** Buccal gingival thickness 5 mm below marginal gingiva using transgingival probing (mm)

Variables	Control	CM	CM/AB204	P value
Baseline (0 week)	4.19±1.34	4.10±1.10	4.43±1.56	0.82
2 weeks after surgery	4.46±0.88	5.04±1.03	5.45±1.03	0.05 <sup>a)</sup>
Change from 0 week	0.27±1.12	0.94±1.40	1.02±1.36	0.31
4 weeks after surgery	3.95±1.09	4.93±1.49	4.89±1.17	0.11
Change from 0 week	-0.24±0.98	0.83±1.38	0.45±1.60	0.15
Change from 2 weeks	-0.517±0.956	-0.10±1.36	-0.56±1.45	0.62
8 weeks after surgery	4.35±1.50	4.32±1.60	4.65±1.34	0.69
Change from 0 week	0.15±1.18	0.22±1.52	0.21±1.14	0.99
Change from 2 weeks	-0.11±1.51	-0.71±1.21	-0.808±1.29	0.39

Values are presented as mean ± standard deviation.

CM: collagen matrix (Collagen Graft 2<sup>®</sup>), BMP-2: bone morphogenetic protein-2, AB204: Activin/BMP-2 Chimera.

<sup>a)</sup> Statistically significant different at the same observation period (statistical significance level was 5%,  $P<0.05$ ).

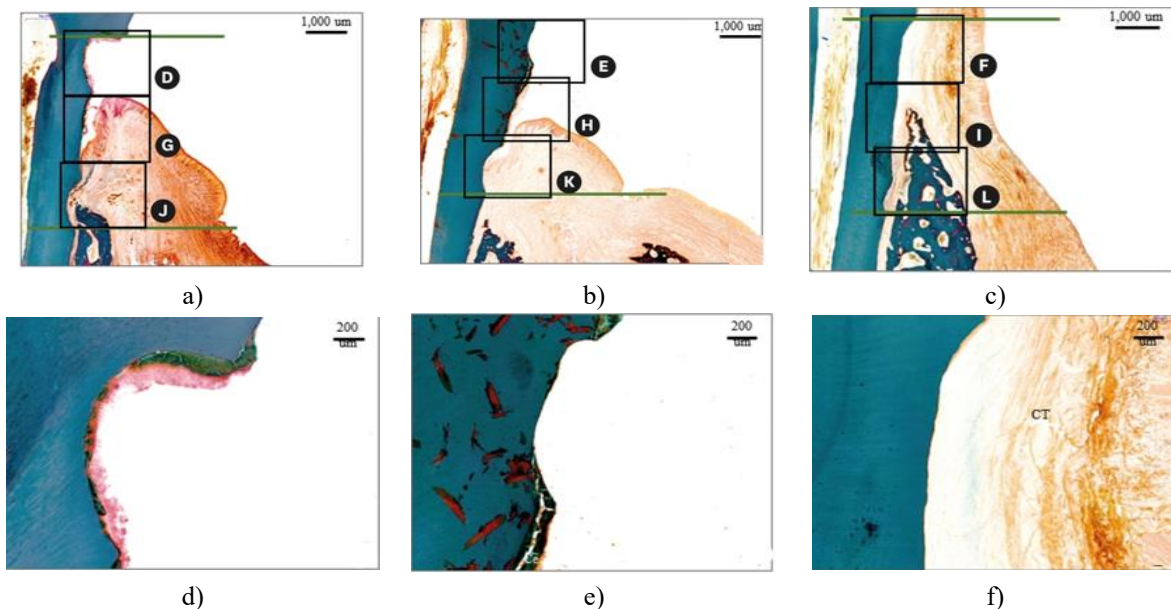


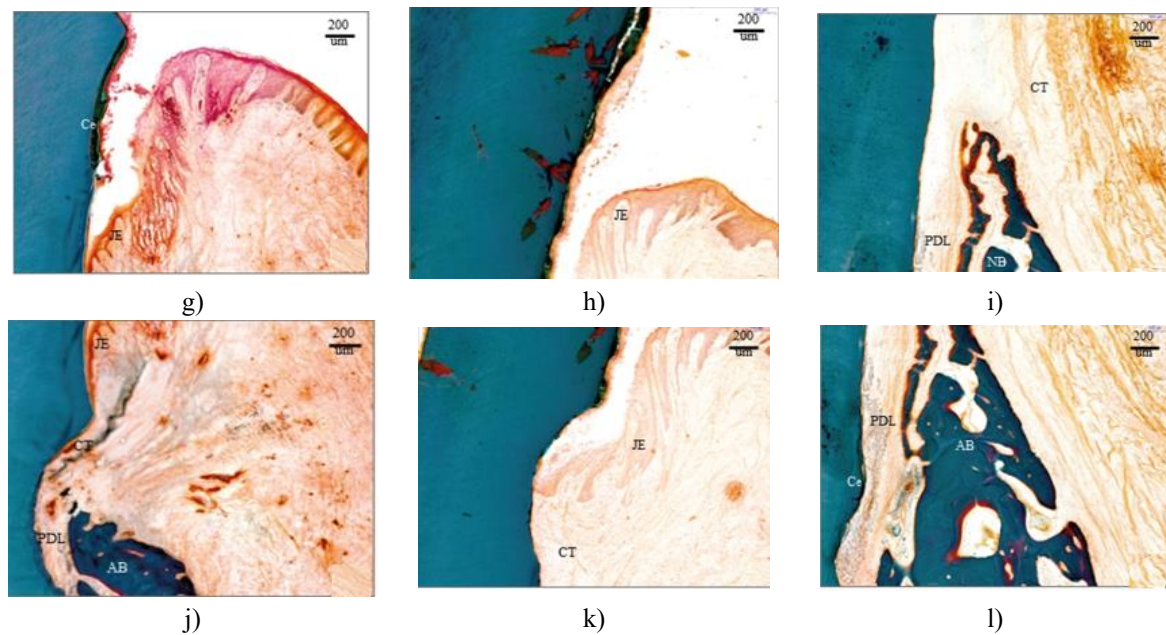
**Figure 4.** Thickness of the buccal gingiva measured 5 mm below the marginal gingiva at 0, 2, 4, and 8 weeks after surgery. CM: collagen matrix (Collagen Graft 2<sup>®</sup>), BMP-2: bone morphogenetic protein-2, AB204: Activin/BMP-2 Chimera.

All groups demonstrated an increasing trend until 2 weeks after grafting, with a subsequent decrease. However, between 4 and 8 weeks, the control group displayed a slight increase. While the difference was not statistically significant, the buccal gingival thickness in the CM/AB204 group was thicker than that in the other groups at 8 weeks after grafting.

*Analysis of histological images*

The formation of new cementum within the defect was discontinuous in the control group (**Figure 5a**), with epithelial adhesions noted on the external surface (**Figures 5d and 5g**). The apical migration of epithelial adhesions was more pronounced in the control group compared to the experimental groups (**Figure 5a**). New bone formation and PDL development were observed around the lower notch (**Figure 5j**).





**Figure 5.** Photomicrographs of the buccolingual section in dehiscence defects of periodontal tissue in the maxillary premolars, stained with Goldner trichrome stain. The control (a), CM (b), and CM/AB204 (c) groups are depicted, showing the areas from the apical extension of the surgically created defect (scale bar=1,000  $\mu$ m) (coronal insert; d-f) along the root surface to the coronal extension of the newly formed alveolar bone and cementum (apical insert; g-i), as well as the apical extension of the epithelial adhesion (j-l) (scale bar=200  $\mu$ m).

CM: collagen matrix (Collagen Graft 2<sup>®</sup>), BMP-2: bone morphogenetic protein-2, AB204: Activin/BMP-2 Chimera, NB: new bone, Ce: cementum, CT: connective tissue, JE: junctional epithelium, PDL: periodontal ligament.

A relatively continuous layer of cementum-like tissue was observed between the notches in the CM group (**Figure 5b**). The newly formed cementum in the CM group was both longer and thicker than that in the control group (**Figure 5h**). Apical migration of the epithelial attachment was also noted in the CM group, resembling that in the control group. However, new bone formation was not detected, even in the lower notch. Connective tissue attachment was observed to extend up to the lower notch (**Figure 5k**).

The formation of new bone, as well as the presence of the PDL and new cementum around the new bone, was observed in the CM/AB204 group (**Figures 5i and 5l**). A newly formed PDL was evident in this group, characterized by dense collagen fibers that were inserted obliquely into the newly formed cementum on the root surface (**Figure 5l**). Additionally, a thin, continuous layer of newly formed cementum was noted at the lower notch. No instances of ankylosis were noted. Unlike the other groups, the newly formed bone in the CM/AB204 group was seen extending coronally beyond the lower notch (**Figure 5i**).

Due to defect loss during the acquisition of tissue specimens, only 5 of the 12 specimens were suitable for histometric analysis (**Table 3**). The measurements of new cementum width, the length of connective tissue adhesion, and new bone formation appeared to decrease sequentially in the CM/AB204, CM, and control groups. However, only the new cementum width demonstrated a statistically significant difference (**Table 3**).

**Table 3.** Results of histometric analysis of periodontal tissue formation after surgery

Variables	Control (n=5)	CM (n=5)	CM/AB204 (n=5)	P value
New cementum length (um)	944.3±1,383.9	799.7±249.1	1,611.8±1,110.0	0.429
New cementum width (um)	23.2±33.7	88.1±25.8	120.6±110.8	0.035 <sup>a)</sup>
New bone (mm <sup>2</sup> )	0.158±0.157	0.162±0.220	0.442±0.447	0.272
Connective tissue adhesion (um)	1,386.8±1,119.3	1,905.8±1,186.1	2082.7±1,418.6	0.666
Epithelial adhesion (um)	2,043.8±1,150.5	1,870.6±581.4	1,062.5±514.5	0.161

Values are presented as mean  $\pm$  standard deviation.

CM: collagen matrix (Collagen Graft 2<sup>®</sup>), BMP-2: bone morphogenetic protein-2, AB204: Activin/BMP-2 Chimera.

<sup>a)</sup> Statistically significant different at the same observation period (statistical significance level was 5%,  $P < 0.05$ ).

This study explored the combined effects of AB204 and CM implantation on the development of periodontal attachment. To our knowledge, this is the first investigation into the impact of AB204 on periodontal regeneration, providing both 3D and histological evidence regarding the effectiveness of AB204 in treating dehiscence-type defects. Our findings indicate that AB204 promotes the formation of new bone, cementum, and PDL. While the thickness of the buccal gingiva did not differ significantly between the experimental and control groups, it was observed to be thicker in the group treated with CM and AB204. Furthermore, CM was observed to represent an excellent scaffold for AB204, as demonstrated by the considerable ingrowth of hard and soft tissues, which occurred without any infiltration of inflammatory cells.

A previous study reported that BMP-2 administration can promote the formation of cementum-like tissue and alveolar bone in dehiscence-type periodontal defects [27]. The use of biosafe collagen hydrogel scaffolds combined with BMP-2 has resulted in improved periodontal attachment, including the formation of cementum-like tissue, PDL, and alveolar bone, in 1-wall intrabony defects [28]. However, this study was limited to histological analysis, which posed challenges for drawing statistical conclusions. Consequently, the regeneration of newly formed bone, cementum, and PDL could only be confirmed through histological images.

BMPs selectively bind to high-affinity type I receptors (Alk1, Alk2, Alk3, and Alk6) and low-affinity type II receptors (ActRII, ActRIIb, and BMPRII), leading to the formation of receptor complexes that activate Smad 1 and 5 [29, 30]. In contrast, activins, which are members of the TGF- $\beta$  family similar to BMP-2 but exhibit a more compact conformation [31] and a degree of flexibility [32] not seen in BMPs, bind with exceptionally high affinity to type II receptors (ActRII and ActRIIb). Activins then facilitate the recruitment of type I receptors (Alk4 and Alk7) and the activation of Smads 2 and 3 [33, 34]. The chimeric ligand merges the BMP-2 component, which specifically targets type I receptors, with activin A, known for its high affinity for type II receptors. This combination results in enhanced signaling properties, akin to those of BMP-2, through synergistic effects [7]. AB204 may demonstrate superior osteogenic and bone-healing properties in comparison to BMP-2 [35].

Previous research has indicated a correlation between BMP-2 concentration and the occurrence of dentin resorption or ankylosis [4, 36]. In a prior study, administering a low dose of BMP-2 (1.5  $\mu\text{g}$ ) promoted the formation of alveolar bone and cementum-like tissue in the periodontal dehiscence defects of beagle dogs. In contrast, a high dose of BMP-2 (15  $\mu\text{g}$ ) resulted in ankylosis and root resorption [27]. The regeneration of periodontal attachment, which includes cementum-like tissue, PDL, and alveolar bone, was noted in 1-wall defects in beagle dogs treated with 25  $\mu\text{g}$  of BMP-2 [28]. Although a mouse model was utilized in another study, the efficacy of AB204 was found to be one-tenth that of rhBMP-2 [7]. Therefore, the application of 10  $\mu\text{g}$  of AB204 in the current study may be comparable to a relatively high BMP-2 concentration.

The findings of the present study are consistent with those of previous research, suggesting that the use of CM as a scaffold can effectively promote the regeneration of periodontal tissue. A study on minipigs with gingival recession defects showed that grafting with CM, as opposed to using a coronally advanced flap alone, resulted in greater cementum formation and a shorter epithelium [37]. Similarly, another study found that CM, when compared to open flap debridement, promoted the development of continuous cementum and bone, along with a shorter junctional epithelium, in the treatment of 2-wall intrabony defects [16]. In the group treated with CM, probing pocket depth decreased over time, while in the control group, probing pocket depth showed a tendency to increase from 4 to 8 weeks (**Table 2**). This difference may be attributed to the fact that in the control group, only the junctional epithelium was formed.

The present study employed 2 distinct methods to measure the gingival thickness. The first approach involved evaluating the increase in ridge width using 3D digital imaging, while the second method entailed directly measuring the gingival thickness through transgingival probing. Employing a metal periodontal probe for transgingival probing is a reliable and accurate clinical technique, and it is considered the gold standard for such measurements [38]. A recent study indicated that digital measurements of gingival thickness are comparable to those obtained from direct clinical assessments using transgingival probing. The digital method provides several benefits, including noninvasiveness, reproducibility, and reliability [39].

Nevertheless, the present study has several limitations. The sample size was insufficient for the histomorphometric analysis to achieve the statistical power required, due to the loss of the defect over the course of the study. To validate the regenerative potential of AB204 on periodontal tissue, future studies should consider using optimal concentrations and increasing the sample size. Additionally, the histological analysis was limited to a single

healing period. It is also important to be cautious when extrapolating the results of animal studies to humans, as species differences in anatomy and physiology may impact the applicability of the findings to human populations.

## Conclusion

In conclusion, AB204 may effectively support the restoration of periodontal attachment by promoting the formation of new bone, cementum, and PDL.

**Acknowledgments:** None

**Conflict of interest:** None

**Financial support:** This research was supported by the New Faculty Startup Fund from Seoul National University and a grant from the National Research Foundation of Korea (NRF), funded by the Korean government (MSIT) (No. 2020R1C1C1005830/2022M3A9F3082330).

**Ethics statement:** None

## References

1. Wei L, Teng F, Deng L, Liu G, Luan M, Jiang J, et al. Periodontal regeneration using bone morphogenetic protein 2 incorporated biomimetic calcium phosphate in conjunction with barrier membrane: a pre-clinical study in dogs. *J Clin Periodontol.* 2019;46(10):1254–63.
2. James AW, LaChaud G, Shen J, Asatrian G, Nguyen V, Zhang X, et al. A review of the clinical side effects of bone morphogenetic protein-2. *Tissue Eng Part B Rev.* 2016;22(4):284–97.
3. Miyaji H, Sugaya T, Miyamoto T, Kato K, Kato H. Hard tissue formation on dentin surfaces applied with recombinant human bone morphogenetic protein-2 in the connective tissue of the palate. *J Periodontal Res.* 2002;37(3):204–9.
4. Miyaji H, Sugaya T, Kato K, Kawamura N, Tsuji H, Kawanami M. Dentin resorption and cementum-like tissue formation by bone morphogenetic protein application. *J Periodontal Res.* 2006;41(4):311–5.
5. Miyaji H, Sugaya T, Ibe K, Ishizuka R, Tokunaga K, Kawanami M. Root surface conditioning with bone morphogenetic protein-2 facilitates cementum-like tissue deposition in beagle dogs. *J Periodontal Res.* 2010;45(5):658–63.
6. Zaman KU, Sugaya T, Kato H. Effect of recombinant human platelet-derived growth factor-BB and bone morphogenetic protein-2 application to demineralized dentin on early periodontal ligament cell response. *J Periodontal Res.* 1999;34(4):244–50.
7. Yoon BH, Esquivies L, Ahn C, Gray PC, Ye SK, Kwiatkowski W, et al. An activin A/BMP2 chimera, AB204, displays bone-healing properties superior to those of BMP2. *J Bone Miner Res.* 2014;29(9):1950–9.
8. Ryu D, Yoon BH, Oh CH, Kim MH, Kim JY, Yoon SH, et al. Activin A/BMP2 Chimera (AB204) exhibits better spinal bone fusion properties than rhBMP2. *J Korean Neurosurg Soc.* 2018;61(6):669–79.
9. Son S, Yoon SH, Kim MH, Yun X. Activin A and BMP chimera (AB204) induced bone fusion in osteoporotic spine using an ovariectomized rat model. *Spine J.* 2020;20(5):809–20.
10. Zheng GB, Lee JH, Jin YZ. *In vitro* and *in vivo* evaluation of osteoinductivity and bone fusion ability of an Activin A/BMP2 Chimera (AB204): a comparison study between AB204 and rhBMP-2. *Growth Factors.* 2017;35(3):249–58.
11. Polo CI, Sendyk WR, Correa L, Sendyk D, Deboni MC, Naclério-Homem MD. Synergism between recombinant human bone morphogenetic protein 2/absorbable collagen sponge and bone substitutes favors vertical bone augmentation and the resorption rate of the biomaterials: histomorphometric and 3D microcomputed tomography analysis. *J Periodontol.* 2020;91(11):1295–306.
12. Choi SH, Kim CK, Cho KS, Huh JS, Sorensen RG, Wozney JM, et al. Effect of recombinant human bone morphogenetic protein-2/absorbable collagen sponge (rhBMP-2/ACS) on healing in 3-wall intrabony defects in dogs. *J Periodontol.* 2002;73(1):63–72.
13. Xiao Y, Qian H, Young WG, Bartold PM. Tissue engineering for bone regeneration using differentiated alveolar bone cells in collagen scaffolds. *Tissue Eng.* 2003;9(6):1167–77.

14. Bauer-Kreisel P, Goepferich A, Blunk T. Cell-delivery therapeutics for adipose tissue regeneration. *Adv Drug Deliv Rev.* 2010;62(7-8):798–813.
15. Asparuhova MB, Stähli A, Guldener K, Sculean A. A novel volume-stable collagen matrix induces changes in the behavior of primary human oral fibroblasts, periodontal ligament, and endothelial cells. *Int J Mol Sci.* 2021;22(8):4051.
16. Imber JC, Bosshardt DD, Stähli A, Saulacic N, Deschner J, Sculean A. Pre-clinical evaluation of the effect of a volume-stable collagen matrix on periodontal regeneration in two-wall intrabony defects. *J Clin Periodontol.* 2021;48(5):560-9.
17. Sorushanova A, Delgado LM, Wu Z, Shologu N, Kshirsagar A, Raghunath R, et al. The collagen suprafamily: from biosynthesis to advanced biomaterial development. *Adv Mater.* 2019;31(1):e1801651.
18. AlSarhan MA, Al Jasser R, Tarish MA, AlHuzaimi AI, Alzoman H. Xenogeneic collagen matrix versus connective tissue graft for the treatment of multiple gingival recessions: a systematic review and meta-analysis. *Clin Exp Dent Res.* 2019;5(4):566–79.
19. Yoo SY, Lee JS, Cha JK, Kim SK, Kim CS. Periodontal healing using a collagen matrix with periodontal ligament progenitor cells in a dehiscence defect model in beagle dogs. *J Periodontal Implant Sci.* 2019;49(4):215–27.
20. Wikesjö UM, Guglielmoni P, Promsudthi A, Cho KS, Trombelli L, Selvig KA, et al. Periodontal repair in dogs: effect of rhBMP-2 concentration on regeneration of alveolar bone and periodontal attachment. *J Clin Periodontol.* 1999;26(6):392–400.
21. Shirakata Y, Sculean A, Shinohara Y, Sena K, Takeuchi N, Bosshardt DD, et al. Healing of localized gingival recessions treated with a coronally advanced flap alone or combined with an enamel matrix derivative and a porcine acellular dermal matrix: a preclinical study. *Clin Oral Investig.* 2016;20(7):1791–800.
22. Suárez-López Del Amo F, Rodríguez JC, Asa'ad F, Wang HL. Comparison of two soft tissue substitutes for the treatment of gingival recession defects: an animal histological study. *J Appl Oral Sci.* 2019;27:e20180584.
23. Shirakata Y, Nakamura T, Shinohara Y, Nakamura-Hasegawa K, Hashiguchi C, Takeuchi N, et al. Split-mouth evaluation of connective tissue graft with or without enamel matrix derivative for the treatment of isolated gingival recession defects in dogs. *Clin Oral Investig.* 2019;23(8):3339–49.
24. Schmitt CM, Matta RE, Moest T, Humann J, Gammel L, Neukam FW, et al. Soft tissue volume alterations after connective tissue grafting at teeth: the subepithelial autologous connective tissue graft versus a porcine collagen matrix - a pre-clinical volumetric analysis. *J Clin Periodontol.* 2016;43(6):609–17.
25. Naenni N, Bienz SP, Benic GI, Jung RE, Hämmerle CH, Thoma DS. Volumetric and linear changes at dental implants following grafting with volume-stable three-dimensional collagen matrices or autogenous connective tissue grafts: 6-month data. *Clin Oral Investig.* 2018;22(3):1185–95.
26. Lee D, Lee Y, Kim S, Lee JT, Ahn JS. Evaluation of regeneration after the application of 2 types of deproteinized bovine bone mineral to alveolar bone defects in adult dogs. *J Periodontal Implant Sci.* 2022;52(4):370–82.
27. Miyaji H, Sugaya T, Ibe K, Ishizuka R, Tokunaga K, Kawanami M. Influence of root dentin surface conditioning with bone morphogenetic protein-2 on periodontal wound healing in beagle dogs. *J Oral Tissue Eng.* 2011;8(3):173–80.
28. Kato A, Miyaji H, Ishizuka R, Tokunaga K, Inoue K, Kosen Y, et al. Combination of root surface modification with BMP-2 and collagen hydrogel scaffold implantation for periodontal healing in beagle dogs. *Open Dent J.* 2015;9:52–9.
29. Hoodless PA, Haerry T, Abdollah S, Stapleton M, O'Connor MB, Attisano L, et al. MADR1, a MAD-related protein that functions in BMP2 signaling pathways. *Cell.* 1996;85(4):489–500.
30. Nishimura R, Kato Y, Chen D, Harris SE, Mundy GR, Yoneda T. Smad5 and DPC4 are key molecules in mediating BMP-2-induced osteoblastic differentiation of the pluripotent mesenchymal precursor cell line C2C12. *J Biol Chem.* 1998;273(3):1872–9.
31. Harrington AE, Morris-Triggs SA, Ruotolo BT, Robinson CV, Ohnuma S, Hyvönen M. Structural basis for the inhibition of activin signalling by follistatin. *EMBO J.* 2006;25(5):1035–45.
32. Greenwald J, Vega ME, Allendorph GP, Fischer WH, Vale W, Choe S. A flexible activin explains the membrane-dependent cooperative assembly of TGF-beta family receptors. *Mol Cell.* 2004;15(4):485–9.
33. Gray PC, Greenwald J, Blount AL, Kunitake KS, Donaldson CJ, Choe S, et al. Identification of a binding site on the type II activin receptor for activin and inhibin. *J Biol Chem.* 2000;275(5):3206–12.

34. Massagué J, Weis-Garcia F. Serine/threonine kinase receptors: mediators of transforming growth factor beta family signals. *Cancer Surv.* 1996;2:41–64.
35. Allendorph GP, Read JD, Kawakami Y, Kelber JA, Isaacs MJ, Choe S. Designer TGF $\beta$  superfamily ligands with diversified functionality. *PLoS One.* 2011;6(5):e26402.
36. Danesh-Meyer MJ. Tissue engineering in periodontics using rhBMP-2. *J N Z Soc Periodontol.* 2000;(85):10–4.
37. Vignoletti F, Nuñez J, Discepoli N, De Sanctis F, Caffesse R, Muñoz F, et al. Clinical and histological healing of a new collagen matrix in combination with the coronally advanced flap for the treatment of Miller class-I recession defects: an experimental study in the minipig. *J Clin Periodontol.* 2011;38(9):847–55.
38. Kloukos D, Koukos G, Gkantidis N, Sculean A, Katsaros C, Stavropoulos A. Transgingival probing: a clinical gold standard for assessing gingival thickness. *Quintessence Int.* 2021;52(5):394–401.
39. Couso-Queiruga E, Tattan M, Ahmad U, Barwacz C, Gonzalez-Martin O, Avila-Ortiz G. Assessment of gingival thickness using digital file superimposition versus direct clinical measurements. *Clin Oral Investig.* 2021;25(4):2353–61.