

Allogeneic Bone Block Grafts for Maxillary Alveolar Ridge Reconstruction: Evidence from a Systematic Review

Mantas Ozols^{1*}, Usman D. Gupta², Sana Singh², Jaan Petrauskas¹, Rana S. Hassan³, Egle J. Kask¹

¹Department of Orthodontics and Dentofacial Orthopedics, Faculty of Health Sciences, University of Tartu, Tallinn, Latvia.

²Department of Orthodontics, Faculty of Health Sciences, Aga Khan University, Karachi, Bangladesh.

³Department of Periodontology and Oral Implantology, School of Medicine and Dentistry, Mohammed V University, Rabat, United Arab Emirates.

*E-mail ✉ mantas.ozols@hotmail.com

Received: 25 April 2024; Revised: 28 July 2024; Accepted: 30 July 2024

ABSTRACT

This systematic review aimed to evaluate the effectiveness of allogeneic bone block grafts in the reconstruction of the maxillary alveolar ridge. A comprehensive search of PubMed, Cochrane Library, and Google Scholar was performed, complemented by manual searches. Studies included were randomized controlled trials (RCTs) and prospective clinical trials (non-RCTs) published up to December 2022, reporting outcomes of allogeneic bone blocks used for maxillary alveolar ridge augmentation. The primary outcome measures were graft resorption, implant survival, and new bone formation following augmentation. Study quality was appraised using the Joanna Briggs Institute Critical Appraisal Tool. Thirteen studies met the eligibility criteria and were analyzed. The reported bone resorption ranged from 0.2 to 29.2 mm, while the overall implant survival rate across studies was 96.87%. On average, 25.83 mm (range: 18.6–33 mm) of newly formed compact bone tissue was observed, featuring viable osteocytes intimately associated with the remaining cancellous bone. The findings of this review suggest that allogeneic bone block grafts represent an effective and dependable option for the reconstruction of atrophic maxillae.

Keywords: Review, Allogeneic bone block grafts, Reconstruction, Maxillary alveolar ridge

How to Cite This Article: Ozols M, Gupta UD, Singh S, Petrauskas J, Hassan RS, Kask EJ. Allogeneic Bone Block Grafts for Maxillary Alveolar Ridge Reconstruction: Evidence from a Systematic Review. *J Orthod Periodontal Biomater Res.* 2024;4(2):1-13. <https://doi.org/10.51847/sMukSfasuf>

Introduction

Reconstruction of atrophic alveolar ridges through ridge augmentation has been a cornerstone of clinical dentistry for over fifty years. This surgical approach aims to restore lost bone volume and is influenced by factors such as patient age, the quantity and quality of existing bone, and the anatomical location of the defect. The ideal graft material should be easy to manipulate, biocompatible to allow integration with the host tissue, and provide an osteoconductive matrix to support new bone formation [1]. Maxillary ridge reconstruction is particularly challenging because, unlike the sinus region, it often lacks a natural cavity to hold particulate grafts in place [2]. Bone loss can occur vertically, horizontally, or in both dimensions, with clinical studies indicating that horizontal resorption often exceeds vertical loss by approximately 43%. Implant placement in the maxilla is further complicated by variable bone density, increasing the risk of implant failure compared to the mandible, and posing additional prosthetic challenges [3]. Therefore, grafts must be structurally robust to resist muscular forces and maintain dimensional stability. When augmentation exceeds 3 mm in width or height, especially in the anterior maxilla, the use of block grafts is recommended [4]. Given these requirements, allogeneic bone block grafts have become a favored option over alternative graft materials.

The use of bone from donors dates back to 1880 when a Scottish surgeon successfully repaired a child's humerus using tibial bone from another child, marking the first regenerative procedure with allografts [5]. Allogenic bone block grafts are derived from donors of the same species but not the recipient, promoting bone regeneration through both osteoinductive and osteoconductive mechanisms [6]. Cadaveric bone undergoes careful processing to reduce immune reaction and infection risks. Compared with autogenous grafts, allografts offer advantages such as avoidance of donor-site morbidity, reduced operative time, and availability of large volumes of tissue [7]. However, potential drawbacks include immune responses, disease transmission, and incomplete integration with host bone. To mitigate these risks, stringent donor screening, sterilization, and stepwise processing protocols are applied [8].

Allogenic bone blocks can be composed of cancellous or corticocancellous bone, harvested, processed, and transplanted to the recipient site. They are available in multiple forms including fresh-frozen, freeze-dried, demineralized freeze-dried, and deproteinized allografts. Demineralized freeze-dried bone allograft (FDBA) is commonly used; demineralization with hydrochloric acid exposes growth factors such as bone morphogenetic proteins, enhancing the graft's osteoinductive potential.

Despite their clinical use, there is limited consolidated evidence evaluating the performance of allogenic block grafts specifically for maxillary alveolar ridge reconstruction. This systematic review therefore seeks to analyze both clinical and histological outcomes of allogenic block grafts in restoring atrophic maxillae.

Materials and Methods

This systematic review was conducted to answer the question: "In patients with atrophic maxillary ridges indicated for dental implant placement, does the use of allogenic block grafts influence outcomes such as new bone formation, graft resorption, and implant survival?"

A comprehensive literature search was carried out by one investigator (AP) across MEDLINE, EMBASE, the Cochrane Central Register of Controlled Trials, and the Cochrane Oral Health Group Trials Register, including only studies published in English. The review followed the PRISMA guidelines [9] and the Cochrane Handbook for Systematic Reviews of Interventions [10]. The protocol was prospectively registered in PROSPERO, the international database for systematic reviews.

To capture all relevant studies, search terms included combinations of ("allogenic bone block graft" OR "block allograft" OR "block graft") AND ("maxillary ridge reconstruction" OR "maxillary alveolar ridge reconstruction" OR "maxillary alveolar ridge augmentation" OR "maxillary ridge augmentation") AND ("randomized clinical trial" OR "randomized controlled trial" OR "prospective clinical trial") AND ("histological study" OR "histomorphometric study" OR "histomorphometrical investigation"). Additional publications were identified by manual searches and examining reference lists of eligible studies.

Three reviewers (AP, RK, and AK) independently screened titles and abstracts to select studies, followed by full-text evaluation of potentially relevant papers. Any articles with unclear data underwent a detailed review. Cross-referencing of included trials was also performed to identify additional studies. Disagreements during selection were resolved by a fourth reviewer (VL).

Inclusion criteria were: prospective human clinical trials published in English up to December 2022, involving patients without systemic diseases, reporting outcomes of allogenic bone block grafting in atrophic maxillary ridges, and including histological and implant survival data. The primary outcome measured was graft resorption, while secondary outcomes included implant survival, graft failure, incidence of failed implants, and new bone formation.

Exclusion criteria comprised studies with less than six months of follow-up, animal studies, case series, narrative or literature reviews, books, letters, studies with incomplete data, or studies not meeting eligibility in terms of population or study duration.

Data extraction was conducted independently by two reviewers (AP and RK), who collected information on authorship and year, sample size, mean age, type of allogenic block graft used, resorption rate, implant and graft survival, amount of newly formed bone, complications, and follow-up duration (minimum six months).

The methodological quality of each study was assessed independently by two reviewers (AP and AK) using the Joanna Briggs Institute Critical Appraisal Tool [11, 12]. Among the two included randomized controlled trials [13, 14], one was rated high quality and the other moderate quality. Of the eleven quasi-experimental studies [2, 15-24], three were high quality and eight were moderate quality (**Table 1; Figures 1 and 2**).

Study	Does the study clearly distinguish between the “ cause” and the “ effect,” ensuring there’s no ambiguity about which variable precedes the other?	Did the study include a control group?	Were the participants being compared sufficiently similar?	Aside from the exposure or intervention being studied, did the participants in the comparisons receive comparable treatment or care?	Were the outcomes measured multiple times, both before and after the intervention or exposure?	Were the outcomes assessed using the same method for all participants in the comparisons?	Were the outcomes assessed using a consistent and dependable method?	Was follow-up comprehensive, and if not, were any differences in follow-up between groups thoroughly reported and analyzed?	Was a suitable statistical method applied in the analysis?	Score	Quality assessment
Acocella <i>et al.</i> [19]	Yes	No	No	NA	Unclear	NA	Yes	Yes	Yes	6/9=0.67	Moderate
Nissan <i>J et al.</i> [18]	Yes	No	No	NA	Unclear	NA	Yes	Yes	No	5/9=0.55	Moderate
Chausshu <i>G et al.</i> [17]	Yes	No	No	NA	Unclear	NA	Yes	Yes	Yes	6/9=0.67	Moderate
Chausshu <i>G et al.</i> [16]	Yes	No	No	NA	Unclear	NA	Yes	Yes	No	5/9=0.55	Moderate
Barone <i>A et al.</i> [15]	Yes	No	No	NA	Unclear	NA	Yes	Yes	No	5/9=0.55	Moderate
Contar <i>CM et al.</i> [2]	Yes	No	No	NA	Unclear	NA	Yes	Yes	No	5/9=0.55	Moderate

Krasny M <i>et al.</i> [20]	Yes	No	Yes	Yes	Yes	Yes	Yes	Yes	No	7/9=0.78	High
Deluiz D <i>et al.</i> [21]	Yes	No	No	NA	Unclear	NA	Yes	Yes	Yes	6/9=0.67	Moderate
Ahmadi RS <i>et al.</i> [22]	Yes	No	Yes	Yes	Yes	Yes	Yes	Yes	Yes	8/9=0.89	High
Lorenz J <i>et al.</i> [23]	Yes	No	No	NA	Unclear	NA	Yes	Yes	Yes	6/9=0.67	Moderate
Krasny K <i>et al.</i> [24]	Yes	No	Yes	Yes	Yes	Yes	Yes	Yes	No	7/9=0.78	High

NA – Not available

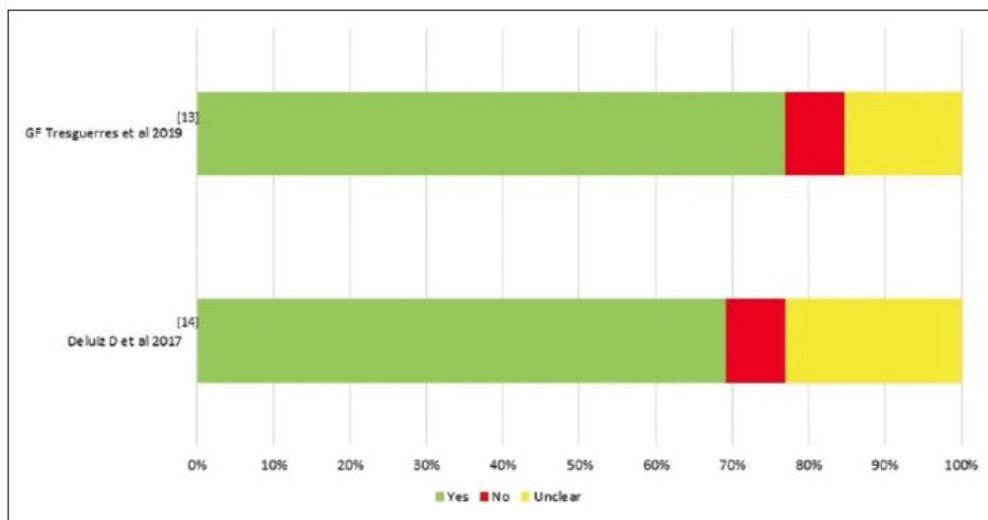


Figure 1. Quality assessment of the randomized controlled trials using Joanna Briggs Institute tool

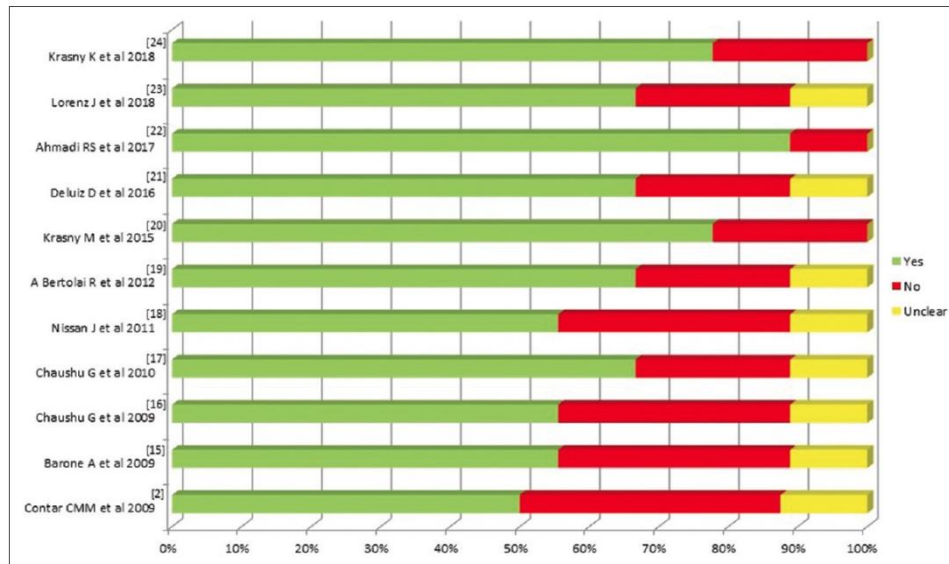


Figure 2. Quality assessment of the quasi-experimental studies using Joanna Briggs Institute tool [12]

Results and Discussion

After completing the analysis, a total of 13 studies were included in this review (Figure 3). This systematic review was conducted to evaluate the effects of allogeneic bone block grafting on implant survival and new bone formation. The study selection followed a three-step screening process: initially screening titles, followed by abstracts, and finally reviewing the full texts for eligibility. The details and characteristics of the included studies are summarized in the tables.

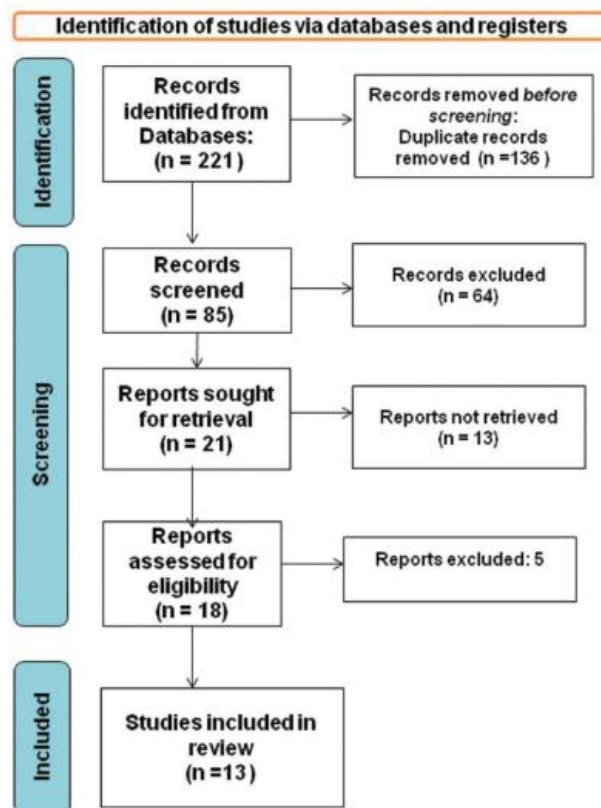


Figure 3. Flow diagram depicting the selection and screening process of studies included in this review, in accordance with the Preferred Reporting Items for Systematic Reviews and Meta-Analyses (PRISMA). n – number

Table 2 lists the 13 studies [2, 13-24] that satisfied the predefined inclusion criteria. Each study investigated the impact of block grafting on implant survival and new bone formation. The studies were published between 2009 and 2019, revealing a notable lack of long-term follow-up data on block grafting, suggesting that extended longitudinal evidence is still limited. Regarding study methodology, seven studies employed nonrandomized designs, while six were randomized controlled trials.

Table 2. Details of the studies included in the systematic review

Study Id/ Ref. No.)	Title	Authors name	Year of publication	Study design
2	Maxillary ridge augmentation with fresh-frozen bone allografts	Contar <i>et al.</i> [2]	2009	Non-RCT
13	Incorporation and remodeling of bone block allografts in the maxillary	Deluiz <i>et al.</i> [13]	2016	RCT
14	reconstruction: A randomized clinical trial Clinical and radiographic outcomes of allogenic block grafts for maxillary lateral	Tresguerres	2019	RCT
15	ridge augmentation: A randomized clinical trial Deep-Frozen Allogenic Onlay Bone Grafts for Reconstruction of atrophic	Tresguerres <i>et al.</i> [14]; Barone <i>et al.</i> [15]	2009	Non-RCT
16	maxillary alveolar ridges: A preliminary study The use of cancellous block allograft for sinus floor augmentation with	Chaushu <i>et al.</i> [16]	2009	Non- RCT
17	simultaneous implant placement in the posterior atrophic maxilla Histomorphometric analysis after maxillary sinus floor augmentation using	Chaushu <i>et al.</i> [17]	2010	Non- RCT
18	cancellous bone–block allograft Cancellous bone block allografts for the augmentation of the anterior atrophic	Nissan <i>et al.</i> [18]	2011	Non- RCT
19	maxilla Maxillary alveolar ridge reconstruction with monocortical fresh-frozen bone	Acocella <i>et al.</i> [19]	2012	Choice
20	blocks: A clinical, histological and histomorphometric study Long-term outcomes of the use of allogenic, radiation sterilized bone blocks in	Krasny <i>et al.</i> [20]	2015	randomization Non-RCT
21	reconstruction of the atrophied alveolar ridge in the maxilla and mandible Fresh-frozen bone allografts in maxillary alveolar augmentation: Analysis of	Deluiz <i>et al.</i> [21]	2016	Non- RCT
22	complications, adverse outcomes, and implant survival Clinical and Histomorphometric assessment of lateral alveolar ridge	Ahmadi <i>et al.</i> [22]	2017	Non-RCT
23	augmentation using a corticocancellous freeze-dried allograft bone block Allogenic bone block for challenging augmentation—A clinical, histological, and	Lorenz <i>et al.</i> [23]	2018	Non- RCT
24	histomorphometrical investigation of tissue reaction and new bone formation Allogenic bone block volume preservation in ridge augmentation for implants	Krasny <i>et al.</i> [24]	2018	Non RCT

RCT – Randomised controlled trial.

The studies included in this review utilized various types of bone grafts, such as fresh-frozen, deep-frozen allogenic, cancellous, monocortical fresh-frozen, radiation-sterilized, and corticocancellous freeze-dried allografts. All block grafts were applied to the maxilla to augment atrophic ridges in either the anterior or posterior region.

Table 3 outlines the sample and intervention details of the included studies. Collectively, 448 patients were treated, with individual study populations ranging from 10 to 117 cases. The majority of procedures targeted the maxilla, while only a few involved the mandible. Grafts were placed at 594 sites in total, with site numbers per study varying between 24 and 141. Of the seven studies reporting augmentation type, horizontal ridge augmentation was more frequently performed than vertical. Across all studies, 1,244 implants were inserted in both the maxilla and mandible, and follow-up periods ranged from 6 to 96 months to evaluate implant survival and new bone formation.

Table 3. Overview of Study Participants and Interventions in Selected Studies

Study ID/Ref. No.	Authors	No. of Patients	Maxilla/Mandible	No. of Grafted Sites/Blocks	Alveolar Ridge Augmentation (Horizontal/Vertical/Both)	No. of Implants	Follow-up (Months)
2	Contar <i>et al.</i> [2]	15	Maxilla	34	Not reported	51	24–35
13	Deluiz <i>et al.</i> [13]	66 (52 female, 14 male)	Maxilla	113	Not reported	305	12
14	Tresguerras <i>et al.</i> [14]	117 (79 female, 38 male)	92 maxilla, 18 mandible	141	88 horizontal, 7 vertical, 26 both	183	6–96
15	Barone <i>et al.</i> [15]	13 (3 male, 10 female)	13 anterior maxilla, 9 posterior maxilla	24	5 vertical, 19 horizontal	38	6
16	Chaushu <i>et al.</i> [16]	28 (13 female, 15 male)	Posterior maxilla	Not reported	Vertical	72	11–44 (27 avg.)
17	Chaushu <i>et al.</i> [17]	31 (16 female, 15 male)	Posterior maxilla	Not reported	Vertical	76	9
18	Nissan <i>et al.</i> [18]	31 (20 female, 11 male)	Anterior maxilla	46	42 horizontal, 27 vertical (9% vertical, 40% horizontal, 51% both)	63	6–59
19	Acocella <i>et al.</i> [19]	16 (11 male, 5 female)	Maxilla	18	Not reported	34	18–30
20	Krasny <i>et al.</i> [20]	21 (15 female, 6 male)	19 maxilla, 7 mandible	26	Not reported	33	28–50 (39 avg.)
21	Deluiz <i>et al.</i> [21]	58 (15 male, 43 female)	22 posterior maxilla, 19 anterior maxilla, 17 full-arch	92	Not reported	268	16
22	Ahmadi <i>et al.</i> [22]	10 (3 female, 7 male)	Not reported	Not reported	Horizontal	Not reported	12–18
23	Lorenz <i>et al.</i> [23]	14 (9 female, 5 male)	Not reported	14	4 horizontal	28	6
24	Krasny <i>et al.</i> [24]	28 (14 female, 14 male)	Not reported	37 cortical, 49 cancellous	Not reported	93 (39 cortical, 53 cancellous)	24

Table 4 provides an overview of the outcomes of allogeneic block grafts in atrophic maxilla from the studies reviewed. Graft success was assessed through indicators including resorption rate, implant survival, number of

failed implants, number of unsuccessful grafts, and quantity of newly formed bone. While not every study reported on all these measures, only studies reporting on more than two of these outcomes were considered for inclusion.

Table 4. Summary of Outcomes Following Block Grafting in Included Studies

Study ID/Ref. No.	Authors	Bone Resorption Rate	Implant Survival Rate (%)	Number of Failed Implants	Number of Failed Blocks	New Bone Formation Description
2	Contar <i>et al.</i> [2]	Not reported	94.4	0	Not reported	Mature, dense bone tissue with marrow spaces; viable and newly formed bone observed.
13	Deluiz <i>et al.</i> [13]	Group 1: 13.98% ± 65.59 (lower than Group 2: 31.52% ± 66.31)	94.6	16	Not reported	Incorporated with grafted areas; no further details reported.
14	Tresguerres <i>et al.</i> [14]	20.06 ± 1.43 mm	98.4	96.7%	Not reported	Not reported.
15	Barone <i>et al.</i> [15]	Not reported	94.74	2	2	Not reported.
16	Chaushu <i>et al.</i> [16]	Not reported	94.4	4	Not reported	Not reported.
17	Chaushu <i>et al.</i> [17]	Not reported	94.7	4	Not reported	Newly formed vital bone, residual cancellous bone-block allograft, and connective tissue observed in all augmented sinuses; residual bone showed empty lacunae and separation lines; newly formed bone with viable osteocytes in close contact with residual cancellous bone.
18	Nissan <i>et al.</i> [18]	Mean buccal bone resorption: 0–1 mm; 0.5 ± 0.5 mm at implant placement, 0.2 ± 0.2 mm at second-stage surgery	98	Not reported	2	Not reported.
19	Acocella <i>et al.</i> [19]	11.45 ± 8.37 mm	100	0	Not reported	Not reported.
20	Krasny <i>et al.</i> [20]	Not reported	Not reported	Not reported	Not reported	Not reported.
21	Deluiz <i>et al.</i> [21]	Not reported	Not reported	Not reported	Not reported	Not reported.
22	Ahmadi <i>et al.</i> [22]	1.62 ± 0.75 mm at 2 mm from crest; -1.95 ± 0.55 mm at 5 mm from crest	Not reported	Not reported	Not reported	33.0 ± 11.35 mm.
23	Lorenz <i>et al.</i> [23]	Not reported	Not reported	Not reported	Not reported	18.65 ± 12.20 mm.
24	Krasny <i>et al.</i> [24]	Cancellous grafts: 29.2% ± 2.6; corticocancellous grafts: 0.2 ± 0.45 mm (0–2.2 mm) at 1 year, 0.5 ± 0.8 mm (0–3.1 mm) at 2 years; cancellous group: 0.3 ± 0.65 mm (0–2.6 mm) at 1 year, 0.7 ± 1.0 mm (0–3.4 mm) at 2 years	100	Not reported	Not reported	Not reported.

Primary outcome analysis

Five studies [13-14,18-19, 22, 24] reported on bone resorption or the reduction in bone volume following block graft placement, with resorption rates ranging from 0.2 to 29.2 mm across the included studies. Nissan *et al.* observed buccal bone resorption of 0–1 mm, with 0.5 ± 0.5 mm occurring after implant placement and 0.2 ± 0.2 mm following the second-stage surgery [18]. Krasny *et al.* reported higher resorption, with corticocancellous

grafts showing 0.2 ± 0.45 mm and cancellous grafts 0.3 ± 0.65 mm at 1 year, increasing to 0.5 ± 0.8 mm and 0.7 ± 1.0 mm, respectively, at 2 years [24]. Deluiz *et al.* documented resorption rates between 13.98% and 31.52% in their study groups [13], whereas Acocella *et al.* reported a mean resorption of $11.45\% \pm 8.37\%$ [19].

Secondary outcome analysis

Implant survival following block grafting was reported in nine studies, with an average survival rate of 96.87%, ranging from 94.4% to 100%, and 26 implant failures across all studies. Only two studies reported complete implant survival without complications [19, 24], both of which used monocortical fresh-frozen and allogeneic bone blocks for maxillary reconstruction. Overall, all studies demonstrated implant survival rates above 90%. Block graft failure was noted in two studies as a contributing factor to implant failure, totaling four failed blocks [15, 18].

Only four studies reported on new bone formation and its characteristics, showing an average formation of 25.83 mm (range 18.65–33 mm) [22, 23]. Contar *et al.* (2009) observed mature, dense bone tissue with marrow spaces, and radiographic evidence indicated integration of new bone with grafted areas [2]. Chashu *et al.* reported vital bone, residual cancellous graft material, and connective tissue in augmented maxillary sinuses [17], with histological analyses confirming viable osteocytes in close contact with residual cancellous bone.

Allogeneic bone block grafts are used to restore the maxillary alveolar ridge, increasing bone volume for implant placement and enhancing implant stability and longevity [19]. The maxillary ridge generally has lower bone density, which is critical for achieving primary implant stability [25]. In the anterior maxilla, where no natural scaffold exists to contain particulate grafts, grafts must provide sufficient rigidity to remain anchored at the recipient site and resist muscular forces [12]. Improper occlusal loading from the final prosthesis can lead to biological or mechanical complications [26]. Axial forces are distributed around the implant, placing significant load on peripheral bone, particularly in the molar-premolar region, while transverse forces in the anterior maxilla increase bending stress, potentially harming both implants and supporting tissues [27]. Consequently, maxillary ridge augmentation is generally more challenging than mandibular ridge augmentation.

Allogeneic bone tissue is usually sourced from cadavers and undergoes extensive processing to reduce the risks of immune rejection and infection. This method offers several advantages over autogenous bone grafting, including decreased donor site morbidity, shorter surgical time, and access to larger amounts of bone [7]. Nonetheless, allografts must be evaluated for antigenicity. Some studies have examined the long-term outcomes of fresh-frozen allografts. In a 30-year follow-up study, Virolainen *et al.* reported no significant allergic reactions, graft rejection, or unexpected antibody responses after bone augmentation with allografts [28]. Histological assessments and immune response evaluations also showed no evidence of antigenic reactions to fresh-frozen allografts used in reconstructing large bony defects [29]. Nissan *et al.* additionally reported dimensional gains in bone after augmentation, with vertical increases of 2 ± 0.5 mm (0–3 mm) and horizontal gains of 5 ± 0.5 mm (4–6 mm) following implant placement, indicating the stability of allogeneic block grafts throughout the study period [18].

A key aspect of these studies was the evaluation of various block allografts used alone for maxillary alveolar ridge reconstruction, accompanied by histologic or histomorphometric analyses. Acocella *et al.* observed numerous empty osteocyte lacunae and nonvital bone surrounding newly formed bone after a 9-month healing period [19], while Contar *et al.* reported a lamellar structure with osteocytes within lacunae around Haversian canals [2]. Within the center of the block graft, osteocytes were present alongside many vacant lacunae. Spin-Neto *et al.* identified extensive necrotic bone and empty lacunae without osteoclastic activity, although blood vessels infiltrated the graft's Haversian canals without direct contact between transplanted and remodeled bone [30].

The process of creeping substitution differs between cancellous and cortical bone. Cancellous grafts integrate rapidly due to faster revascularization, as invading blood vessels carry osteoprogenitor cells that differentiate into osteoblasts, forming new bone around necrotic trabeculae. Cortical grafts integrate more slowly because of their dense structure; vascular invasion occurs only after osteoclasts enlarge Haversian and Volkmann's canals, delaying complete revascularization, which may take several months. Osteoblasts eventually occupy these widened canals to deposit new bone. Corticocancellous grafts combine these mechanisms, benefiting from features of both cortical and cancellous layers [31].

Lumetti *et al.* reported similar outcomes between allogeneic and autogenous blocks, achieving adequate bone density at grafted sites, suggesting allografts as a viable alternative to autografts [32]. The cancellous layer facilitates close contact with native bone and improves compressibility, enhancing osteoconduction and vascularization, while the cortical layer provides mechanical resistance and protects against early resorption. This

combination promotes graft integration and stability. Kloss *et al.* [7] compared three-dimensional changes following autogenous and allogenic onlay grafts for alveolar ridge augmentation and found no significant differences in vertical or horizontal dimensions or remodeling rates between the two types of grafts. Additionally, da Costa *et al.* evaluated freeze-dried and fresh-frozen allogenic block grafts, reporting superior bone regeneration with fresh-frozen grafts [33].

This comprehensive review indicates that, regardless of subtype, allogenic bone block grafts are an effective approach for augmenting the atrophic maxilla, despite the considerable heterogeneity across the included studies. While the rates of resorption, implant survival, and complications related to allogenic blocks appear acceptable, the lack of standardization across investigations limits the ability to draw definitive conclusions. Furthermore, due to differences in study design, it remains unclear which type of allogenic block graft provides the most consistent bone gain and optimal host-bone integration. Although the results generally support favorable outcomes in terms of graft integration, new bone formation, implant survival, and associated complications, the scarcity of high-quality trials prevents strong conclusions, highlighting the need for further research. Future studies should focus on extensive, long-term randomized clinical trials to evaluate the outcomes and performance of allogenic bone block grafts.

The limitations of this systematic review include the variability in evaluation methods across studies and inherent differences in clinical settings. Despite the rigorous search strategy, some gray literature may have been missed. Additionally, due to the limited number of high-quality randomized controlled trials, certain prospective clinical studies were included to expand the review's scope, which may be considered a limitation.

Overall, considering all outcome measures, allogenic bone block grafting demonstrates significant benefits for implant survival and new bone formation, underlining its importance in implant dentistry for patients with an atrophic maxilla.

Conclusion

Based on the findings of this systematic review, allogenic bone block grafts show promising results for maxillary alveolar ridge reconstruction, offering high implant survival, low complication rates, and long-term stability, making them a reliable option for augmenting severely atrophic alveolar ridges.

Acknowledgments: None

Conflict of interest: None

Financial support: None

Ethics statement: None

References

1. Aslan E, Gultekin A, Karabuda C, Mortellaro C, Olgac V, Mijiritsky E. Clinical, histological, and histomorphometric evaluation of demineralized freeze-dried cortical block allografts for alveolar ridge augmentation. *J Craniofac Surg.* 2016;27(5):1181-6.
2. Contar CM, Sarot JR, Bordini J Jr, Galvão GH, Nicolau GV, Machado MA. Maxillary ridge augmentation with fresh-frozen bone allografts. *J Oral Maxillofac Surg.* 2009;67(6):1280-5.
3. Schropp L, Wenzel A, Kostopoulos L, Karring T. Bone healing and soft tissue contour changes following single-tooth extraction: A clinical and radiographic 12-month prospective study. *Int J Periodontics Restorative Dent.* 2003;23(4):313-23.
4. Moy P, Palacci P. Minor bone augmentation procedures. In: Palacci P, Ericsson I, editors. *Esthetic Implant Dentistry: Soft and Hard Tissue Management.* Hanover Park (IL): Quintessence Publishing; 2001. p.137-58.
5. de Boer HH. The history of bone grafts. *Clin Orthop Relat Res.* 1988;(226):292-8.
6. Nissan J, Marilena V, Gross O, Mardinger O, Chaushu G. Histomorphometric analysis following augmentation of the posterior mandible using cancellous bone block allograft. *J Biomed Mater Res A.* 2011;97(4):509-13.

7. Kloss FR, Offermanns V, Kloss-Brandstätter A. Comparison of allogeneic and autogenous bone grafts for augmentation of alveolar ridge defects: A 12-month retrospective radiographic evaluation. *Clin Oral Implants Res.* 2018;29(12):1163-75.
8. Mellonig JT. Donor selection, testing, and inactivation of the HIV virus in freeze-dried bone allografts. *Pract Periodontics Aesthet Dent.* 1995;7(3):13-22.
9. Page MJ, McKenzie JE, Bossuyt PM, Boutron I, Hoffmann TC, Mulrow CD, et al. The PRISMA 2020 statement: An updated guideline for reporting systematic reviews. *BMJ.* 2021;372:n71.
10. Higgins JP, Altman DG, Sterne JAC. Assessing risk of bias in included studies (Chapter 8). In: Higgins JP, Green S, editors. *Cochrane Handbook for Systematic Reviews of Interventions.* Version 5.1.0. The Cochrane Collaboration; 2011.
11. Barker TH, Stone JC, Sears K, Klugar M, Tufanaru C, Leonardi-Bee J, et al. The revised JBI critical appraisal tool for the assessment of risk of bias for randomized controlled trials. *JBI Evid Synth.* 2023;21(3):494-506.
12. Barker TH, Habibi N, Aromataris E, Stone JC, Leonardi-Bee J, Sears K, et al. The revised JBI critical appraisal tool for the assessment of risk of bias for quasi-experimental studies. *JBI Evid Synth.* 2024;22(4):378-88.
13. Deluiz D, Santos Oliveira L, Ramôa Pires F, Reiner T, Armada L, Nunes MA, et al. Incorporation and remodeling of bone block allografts in the maxillary reconstruction: A randomized clinical trial. *Clin Implant Dent Relat Res.* 2017;19(1):180-94.
14. Tresguerres FG, Cortes AR, Hernandez Vallejo G, Cabrejos-Azama J, Tamimi F, Torres J. Clinical and radiographic outcomes of allogeneic block grafts for maxillary lateral ridge augmentation: A randomized clinical trial. *Clin Implant Dent Relat Res.* 2019;21(6):1087-98.
15. Barone A, Varanini P, Orlando B, Tonelli P, Covani U. Deep-frozen allogeneic onlay bone grafts for reconstruction of atrophic maxillary alveolar ridges: A preliminary study. *J Oral Maxillofac Surg.* 2009;67(6):1300-6.
16. Chaushu G, Mardinger O, Calderon S, Moses O, Nissan J. The use of cancellous block allograft for sinus floor augmentation with simultaneous implant placement in the posterior atrophic maxilla. *J Periodontol.* 2009;80(3):422-8.
17. Chaushu G, Vered M, Mardinger O, Nissan J. Histomorphometric analysis after maxillary sinus floor augmentation using cancellous bone-block allograft. *J Periodontol.* 2010;81(8):1147-52.
18. Nissan J, Mardinger O, Calderon S, Romanos GE, Chaushu G. Cancellous bone block allografts for the augmentation of the anterior atrophic maxilla. *Clin Implant Dent Relat Res.* 2011;13(2):104-11.
19. Acocella A, Bertolai R, Ellis E 3rd, Nissan J, Sacco R. Maxillary alveolar ridge reconstruction with monocortical fresh-frozen bone blocks: A clinical, histological, and histomorphometric study. *J Craniomaxillofac Surg.* 2012;40(6):525-33.
20. Krasny M, Krasny K, Fiedor P, Zadurska M, Kamiński A. Long-term outcomes of the use of allogeneic, radiation-sterilised bone blocks in reconstruction of the atrophied alveolar ridge in the maxilla and mandible. *Cell Tissue Bank.* 2015;16(4):631-8.
21. Deluiz D, Oliveira L, Fletcher P, Pires FR, Nunes MA, Tinoco EM. Fresh-frozen bone allografts in maxillary alveolar augmentation: Analysis of complications, adverse outcomes, and implant survival. *J Periodontol.* 2016;87(11):1261-7.
22. Ahmadi RS, Sayar F, Rakhshan V, Iranpour B, Jahanbani J, Toumaj A, et al. Clinical and histomorphometric assessment of lateral alveolar ridge augmentation using a corticocancellous freeze-dried allograft bone block. *J Oral Implantol.* 2017;43(3):202-10.
23. Lorenz J, Kubesch A, Al-Maawi S, Schwarz F, Sader RA, Schlee M, et al. Allogeneic bone block for challenging augmentation: A clinical, histological, and histomorphometrical investigation of tissue reaction and new bone formation. *Clin Oral Investig.* 2018;22(9):3159-69.
24. Krasny K, Krasny M, Wojtowicz A, Kaminski A. Allogeneic bone block volume preservation in ridge augmentation for implants. *Int J Periodontics Restorative Dent.* 2018;38(3):355-60.
25. Misch CE, Goodacre CJ, Finley JM, Misch CM, Marinbach M, Dabrowsky T, et al. Consensus conference panel report: Crown-height space guidelines for implant dentistry. Part 1. *Implant Dent.* 2005;14(3):312-8.
26. Rangert B, Krogh PH, Langer B, Van Roekel N. Bending overload and implant fracture: A retrospective clinical analysis. *Int J Oral Maxillofac Implants.* 1995;10(3):326-34.

27. Rangert B, Jemt T, Jörneus L. Forces and moments on Brånemark implants. *Int J Oral Maxillofac Implants.* 1989;4(3):241-7.
28. Virolainen P, Heikkilä J, Hirn M, Aro HT, Aho AJ. Thirty years of bone banking at Turku bone bank. *Cell Tissue Bank.* 2003;4(1):43-8.
29. Aho AJ, Eskola J, Ekfors T, Manner I, Kouri T, Hollmen T. Immune responses and clinical outcome of massive human osteoarticular allografts. *Clin Orthop Relat Res.* 1998;(346):196-206.
30. Spin-Neto R, Landazuri Del Barrio RA, Pereira LA, Marcantonio RA, Marcantonio E, Marcantonio E Jr. Clinical similarities and histological diversity comparing fresh-frozen onlay bone block allografts and autografts in human maxillary reconstruction. *Clin Implant Dent Relat Res.* 2013;15(3):490-7.
31. Albrektsson T. Repair of bone grafts: A vital microscopic and histological investigation in the rabbit. *Scand J Plast Reconstr Surg.* 1980;14(1):1-12.
32. Lumetti S, Consolo U, Galli C, Multinu A, Piersanti L, Bellini P, et al. Fresh-frozen bone blocks for horizontal ridge augmentation in the upper maxilla: Six-month outcomes of a randomized controlled trial. *Clin Implant Dent Relat Res.* 2014;16(1):116-23.
33. da Costa CE, Pelegrine AA, Fagundes DJ, Simoes Mde J, Taha MO. Use of corticocancellous allogeneic bone blocks impregnated with bone marrow aspirate: A clinical, tomographic, and histomorphometric study. *Gen Dent.* 2011;59(3):e200-5.