

## Clinicoradiographic Evaluation of Peri-Implant Tissues Following Flapless Posterior Implant Placement

Neha Verma<sup>1\*</sup>, Rahul H. Verma<sup>2</sup>

<sup>1</sup>Department of Dental Public Health, Faculty of Health Sciences, Aga Khan University, Karachi, Nepal.

<sup>2</sup>Department of Pediatric Dentistry and Orthodontics, School of Medicine and Dentistry, University of Mumbai, Mumbai, Nepal.

\*E-mail ✉ [nverma@hotmail.com](mailto:nverma@hotmail.com)

Received: 15 April 2023; Revised: 17 August 2023; Accepted: 18 August 2023

### ABSTRACT

It is important to prognosticate the hard- and soft-tissue alterations in immediate and delayed implants, as inadequacy can lead to complications affecting the long-term survival of the implant. Therefore, the purpose of this study was to evaluate and compare the hard- and soft-tissue changes in immediate and delayed posterior implants with a flapless approach. With an equal allocation ratio, the study included 46 patients requiring implant treatment in the posterior segment, including the premolars and molars. Group 1 consisted of patients with immediate implants, whereas Group 2 consisted of patients who received delayed implants. The clinical parameters, including plaque index (PI), gingival index, modified sulcus bleeding index, probing depth, and soft-tissue assessment using the Testori esthetic score (TS), were evaluated at baseline, 3, 6, 9, and 12 months. Hard-tissue parameters, such as buccal bone thickness (BBT), crestal bone height (CBH), and ridge width, were evaluated radiographically with cone-beam computed tomography at baseline and 12 months posttherapy. Intragroup comparisons in both the groups showed significant differences in PI, probing pocket depth, and TS over time ( $P = 0.00$ ). The mean BBT at the crest in delayed implants ( $1.76 \pm 0.24$ ) significantly reduced after 12 months compared to immediate implants. A significantly higher TS score was observed after 12 months in both the groups. A significant difference in TS scores after 12 months was found between the two groups, with better esthetics in Group 1 compared to Group 2. However, no significant changes in BBT or CBH were observed after 12 months in Group 1.

**Keywords:** Delayed implants, Flapless approach, Immediate implants, Peri-implant tissues

**How to Cite This Article:** Verma N, Verma RH. Clinicoradiographic Evaluation of Peri-Implant Tissues Following Flapless Posterior Implant Placement. J Orthod Periodontal Biomater Res. 2023;3(2):15-24. <https://doi.org/10.51847/9aqIHpscCs>

### Introduction

The functional and esthetic replacement of lost teeth using dental implants is currently considered a successful treatment modality. Even with their high success rates, osseointegrated implants might experience pathological processes such as peri-implantitis or physiological remodeling, resulting in alterations in the crestal bone level. Due to esthetic concerns, there is a greater need to maintain soft-tissue volume and peri-implant bone levels.

Immediate posttooth extraction implants have several benefits for both the patient and the dentist, including reduced treatment time, better esthetics, and prevention of bone resorption. However, this approach is frequently associated with a residual gap between the coronal section of the implant and the remaining bone walls, an increased risk of infection, and concomitant failure if the socket becomes contaminated. This issue can be addressed by delaying implant placement for 6–8 weeks following extraction to allow for soft-tissue repair and reduce the risk of infection.

The flapless technique offers advantages such as minimal surgical trauma to the patient through minimally invasive incisions, reduced bleeding, minimal interference with the blood supply, faster healing of soft tissue without sutures, reduced surgical time, and thereby, increased patients' comfort, compliance, and satisfaction.

The architectural and vascular properties of the bone crest according to Novaes *et al.* may have a significant influence on the bone remodeling process that starts soon after placement [1]. Previous research has found that the more densely vascularized peri-implant mucosa provided by the flapless treatment is directly associated with enhanced blood supply surrounding the implant, which may boost the implant's resistance to inflammation [2, 3]. Hence, the research hypothesis was that minimal hard- and soft-tissue changes occur in delayed implants compared to immediate implants using the flapless approach when evaluated clinically and radiographically. However, there is a paucity of literature and *in vivo* studies evaluating hard- and soft-tissue alterations in cases of immediate and delayed implants using the flapless technique in the posterior segment, clinically and radiographically, using cone-beam computed tomography (CBCT). There is a need for a better understanding of the variations in the soft-tissue parameters in terms of papillary fill, gingival color, contour, texture, etc., around immediate and delayed posterior implants placed using the flapless approach. Hence, the aim of the present study was to evaluate and compare hard- and soft-tissue alterations in immediate and delayed implants placed with the flapless approach in the posterior segment, clinically and radiographically.

## Materials and Methods

This clinical trial was performed in the department of periodontology and implant dentistry at our institute. The study was granted approval by the Institutional Ethics Committee in agreement with the revised principles of the Helsinki Declaration for biomedical research. The trial was registered with the Clinical Trials Registry (Reg No. CTRI/2020/04/024591) and was reported according to the CONSORT statement and adheres to the EQUATOR guidelines. Written informed consent was obtained from each study participant before commencement.

The sample size was determined based on the study by Edward *et al.* [4] considering the mean values of the peri-implant bone density gray scale at the 6<sup>th</sup> month, with a confidence interval of 99% and a power of 80%. Therefore, a minimum of 17 implants in each group was selected.

Systemically healthy patients aged at least 21 years, with healthy and stable soft-tissue architecture, and sites where a minimum torque of 35 Ncm was obtained at the time of implant insertion were included in the study. The inclusion criteria for delayed implants were partially edentulous sites in the posterior maxilla or mandible requiring dental implant(s), and an adequate volume of native or grafted bone to accommodate the dental implants. Immediate implant placement criteria included tooth/teeth with Grade I or II mobility requiring extraction, root stumps, teeth with endodontic failure or nonrestorable caries, and teeth with acute periapical pathology such as vertical root fracture or chronic periodontal disease with a hopeless prognosis.

The exclusion criteria were patients who had undergone irradiation in the head-and-neck area within the past 6 months, those treated or under treatment with intravenous aminobisphosphonates, individuals with any known systemic conditions, pregnant and lactating females, smokers, patients with para-functional habits, and those with poor oral hygiene.

With an assumption that a few patients may be lost to follow-up, 23 patients were recruited in each group for the study. Suitable sites requiring dental implants and satisfying the inclusion criteria were divided into two groups:

1. Group I: Immediate implant ( $n = 23$ )
2. Group II: Delayed implant ( $n = 23$ ).

Initial therapy consisted of detailed oral hygiene instructions and oral prophylaxis. Before initiating the study, CBCT scans of the sites (baseline), blood investigations, and study models were prepared. Occlusal acrylic stents were fabricated using cold cure acrylic resin to cover the occlusal surface of the implant-supported prosthesis, as well as at least one tooth mesially and distally, to standardize the repeatability of clinical assessments. To cover the coronal third of the teeth, the stents were extended apically on the buccal and lingual surfaces. The stent was grooved to maintain a constant probe position to obtain reliable readings during the follow-up visits. The clinical parameters such as plaque index (PI), [5] gingival index (GI), [6] modified sulcus bleeding index (mSBI), [7] and probing depth (PD) were measured at baseline, 3, 6, 9, and 12 months postoperatively. Before surgery, clinical data were recorded by a single examiner (PB) in all the patients, who was precalibrated for the measurements. However, the assessor (AK) was blinded to the information regarding treatment groups. All the parameters were recorded at two different time points, and the intraobserver reliability of the measurements was calculated using the intraclass correlation coefficient.

Peri-implant soft-tissue assessment included the presence and stability of the mesial and distal papilla, texture of the peri-implant soft tissue, color of the peri-implant soft tissue, and gingival contour. The scoring was done

according to the criteria proposed by Testori *et al.* [8] (TS). The changes in midfacial mucosal level (peri-implant soft-tissue dehiscence) at any time point, if present, were also recorded.

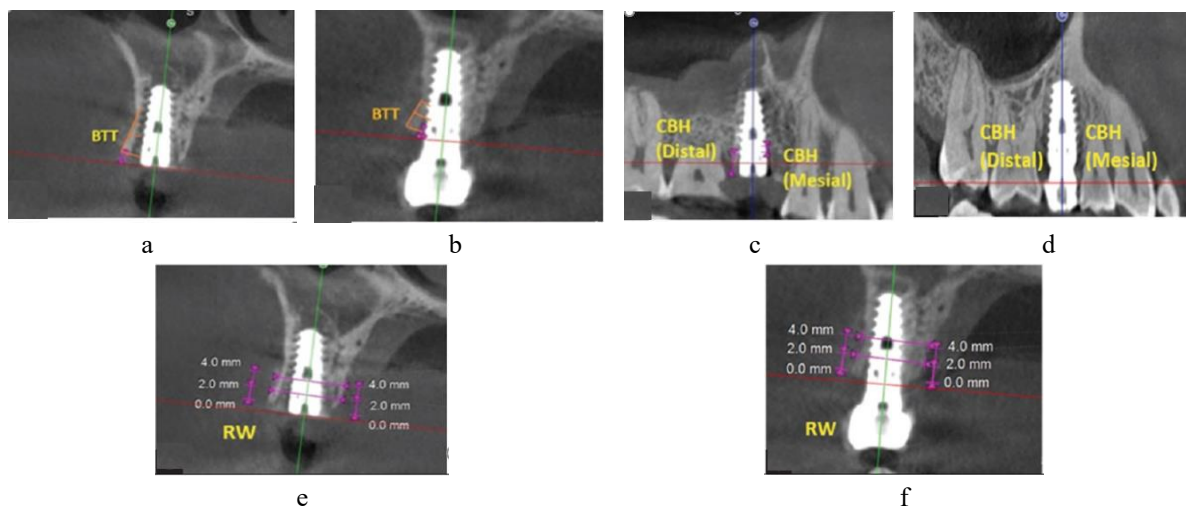
1. TS (a) Presence and stability of the mesiodistal papilla:
  - i. 0 = No papilla
  - ii. 1 = Papilla does not fill the entire space but esthetically acceptable in harmony with adjacent teeth
  - iii. 2 = Total fill of papilla.

The vertical distance between the apex of the mesial and distal papilla and an imaginary line connecting the cemento-enamel junction of the two adjacent teeth was used to measure the papilla's dimensional stability. The height of the mesial and distal papilla was periodically measured in relation to this line.

2. TS (b) Texture of the peri-implant soft tissue:
  - i. 0 = Complete loss of texture
  - ii. 1 = Does not look like healthy tissue, but some texture is still maintained
  - iii. 2 = Looks like healthy gingival tissue around the natural teeth.
3. TS (c) Color of the peri-implant soft tissue:
  - i. 0 = Completely different color from healthy tissue
  - ii. 1 = Does not look like healthy tissue but still esthetically acceptable
  - iii. 2 = Looks like healthy gingival tissue around the natural teeth.
4. TS (d) Gingival contour:
  - i. 0 = Evident asymmetry from the accepted parameters of scalloping
  - ii. 1 = Signs of asymmetry but esthetically acceptable
  - iii. 2 = Harmonious gingival contour.

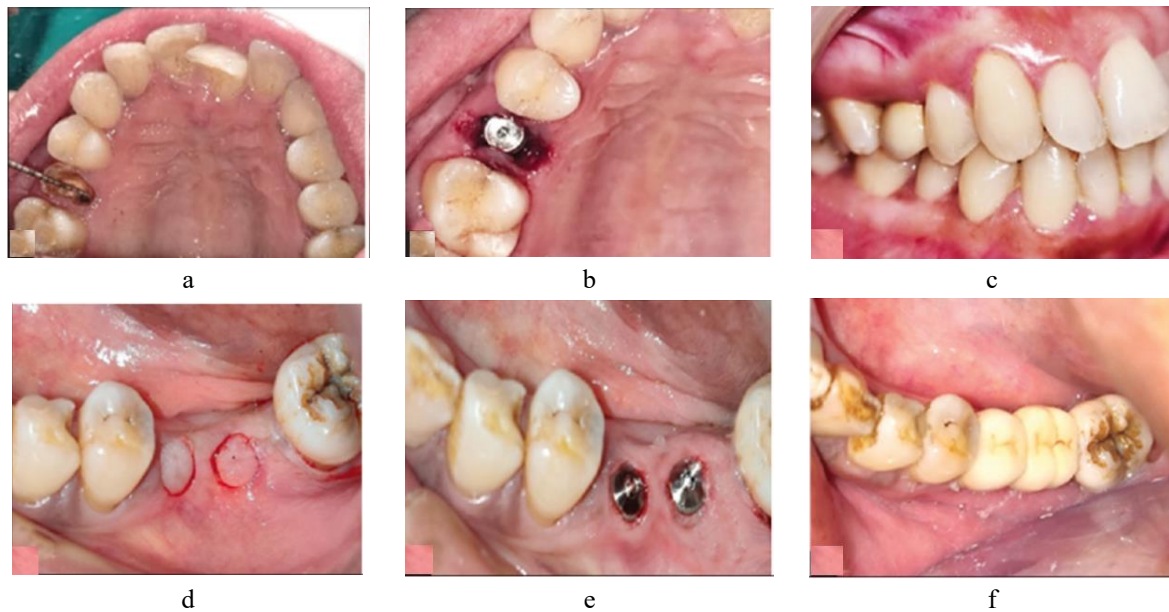
The following radiographic parameters were evaluated using CBCT at baseline and 12 months and using radiovisiography (RVG) at 3, 6, and 9 months (**Figure 1**).

1. Buccal bone thickness (BBT): At the crest, 2 mm from the crest, mid-tooth/implant level, apical level was assessed using CBCT at baseline and 12 months postoperatively
2. Crestal bone height (CBH): Distance between tooth cemento-enamel junction (CEJ)/implant shoulder to the most coronal point of interproximal CBH was assessed using CBCT at baseline and 12 months postoperatively and using RVG at 3, 6, and 9 months postoperatively
3. Ridge width (RW): Buccolingual dimension of osseous ridge was assessed using CBCT at baseline and 12 months and clinically using bone gauge at 3, 6, and 9 months postoperatively.



**Figure 1.** (a and b) Buccal bone thickness at baseline and 12 months; (c and d) Crestal bone height, mesial and distal at baseline and 12 months; (e and f) Ridge width at baseline and 12 months. BTT – Buccal bone thickness, CBH – Crestal bone height, RW – Ridge width; mm – Millimeter

The osteotomy and implant placement were performed using size-customized implant drill guides, according to the manufacturer's surgical protocol in both the groups (**Figure 2**). Patients were prescribed postoperative antibiotics and analgesics. The clinical results were evaluated at 3, 6, 9, and 12 months postoperatively, and radiographic evaluation was done using CBCT at baseline and 12 months postsurgery.



**Figure 2.** (a-c) Immediate implant placed using flapless approach (Group 1); (d-f) Delayed implant placed using flapless approach (Group 2)

Following the data collection, the statistical analysis was performed using SPSS version 26.0 (IBM Corp, USA) software. The demographic characteristics such as age and sex were summarized according to the scale of measurement. Numerical data were assessed for normality by examining their distribution and using the tests of normality (Shapiro-Wilk test). The mean age between the two treatment groups was compared using an independent samples *t*-test. The parameters PI, GI, mSBI, PD, TS, BBT, CBH, and RW were summarized in terms of mean and standard deviation. Each parameter was compared between the two groups using an independent samples *t*-test. For the parameters PI, GI, mSBI, PD, and TS, comparisons between time points were conducted using Friedman ANOVA. The statistical significance was evaluated at the 5% level.

## Results and Discussion

Out of a total of 46 patients, none were lost to follow-up and all the implants survived. Therefore, all 46 implants were considered for the statistical analysis. Descriptive statistics for the demographic characteristics demonstrated that the study participants had a mean age of  $41.33 \pm 11.6$  years in Group 1 and  $42.6 \pm 12.22$  years in Group 2. **Table 1** shows the intragroup comparison of PI, GI, mSBI, PD, and TS at different time points. The mean PI in Group 1 changed from  $1.45 \pm 0.52$  at baseline to  $0.14 \pm 0.50$  at 12 months, whereas in Group 2, it changed from  $1.08 \pm 0.00$  at baseline to  $0.55 \pm 0.52$  at 12 months. A significant difference was observed from baseline to 12 months in PI, GI, and PD in both Group 1 and Group 2. The soft-tissue changes were recorded using TS. The dimensional stability of the mesiodistal papilla assessed in both the groups exhibited highly significant differences ( $P = 0.000$ ) over time, whereas the texture and color of peri-implant soft tissues did not change significantly in either group and showed insignificant changes over the follow-up period. However, the mean score for gingival contour (TS [d]) was  $0.55 \pm 0.52$  at baseline and  $1.55 \pm 0.52$  after 12 months in Group 1 and  $0.00 \pm 0.00$  at baseline and  $1.45 \pm 0.52$  after 12 months in Group 2. These differences were highly significant ( $P = 0.000$ ) in both the groups.

**Table 1.** Intragroup comparison of PI, GI, mSBI, PD, and TS at different time points in Group 1 and Group 2

Intragroup comparison in Group 1						
	Baseline	3 months	6 months	9 months	12 months	P
PI	1.45±0.52	0.55±0.52	0.27±0.46	0.15±0.52	0.14±0.50	0.000**
GI	1.7±0.25	1.4±0.29	1.35±0.22	1.34±0.21	1.31±0.24	0.037*
mSBI	1.0±0.71	0.86±0.71	0.83±0.69	0.82±0.64	0.85±0.74	0.071
PD (mm)	2.78±0.50	2.25±0.52	2.35±0.52	2.15±0.52	2.05±0.5	0.000**
TS (a)	0.00±0.00	0.00±0.00	1.09±0.83	1.09±0.83	1.09±0.83	0.000**
TS (b)	1.55±0.52	1.55±0.52	1.82±0.40	1.82±0.40	1.55±0.52	0.381
TS (c)	1.55±0.52	1.55±0.52	1.64±0.50	1.64±0.50	1.55±0.52	0.981
TS (d)	0.55±0.52	0.55±0.52	1.75±0.46	1.82±0.40	1.55±0.52	0.000**
TS	0.90±0.16	0.90±0.16	1.81±0.40	1.59±0.45	1.43±0.38	0.000**
Intragroup comparison in Group 2						
	Baseline	3 months	6 months	9 months	12 months	P
PI	1.08±0.00	0.55±0.52	0.45±0.00	0.64±0.50	0.55±0.52	0.000**
GI	1.04±0.21	1.2±0.19	1.34±0.21	1.30±0.23	1.21±0.24	0.036*
mSBI	1.57±0.71	1.46±0.45	1.28±0.19	0.96±0.62	0.94±0.54	0.071
PD (mm)	0.00±0.00	2.18±0.60	2.18±0.60	2.18±0.60	2.18±0.60	0.000**
TS (a)	0.00±0.00	0.00±0.00	1.36±0.50	1.45±0.52	1.36±0.50	0.000**
TS (b)	1.45±0.52	1.45±0.52	1.82±0.40	1.82±0.40	1.64±5.0	0.186
TS (c)	1.73±0.46	1.73±0.46	1.91±0.30	1.91±0.30	1.82±0.405	0.678
TS (d)	0.00±0.00	0.00±0.00	1.82±0.16	2.00±0.00	1.45±0.52	0.000**
TS	<b>0.79±0.15</b>	<b>0.79±0.15</b>	<b>2.00±0.00</b>	<b>1.79±0.18</b>	<b>1.56±0.29</b>	<b>0.000**</b>

\*Significant ( $p<0.05$ ), \*\*Highly significant ( $p<0.001$ ). PI – Plaque index; GI – Gingival index; mSBI – Modified sulcus bleeding index; PD – Probing depth;

TS – Testori score; TS (a) – Presence and stability of the mesiodistal papilla; TS (b) – Score for texture of the peri-implant soft tissue; TS (c) – Score for color of the peri-implant soft tissue; TS (d) – Score for gingival score; P – Probability value; mm – Millimeter

**Table 2** shows the comparison of hard-tissue parameters, including CBH and RW, in both the groups over time. The measurements in Group 1 did not show statistically significant differences in terms of mesial and distal CBH. Similarly, RW seemed to be nearly maintained with no significant differences ( $P = 0.067$ ) at 2 mm from the crest and ( $P = 0.148$ ) at 4 mm from the crest throughout the follow-up period in Group 1. However, the picture appeared to be marginally altered in the case of Group 2. The mesial CBH showed highly significant changes ( $P = 0.000$ ) over time, while RW showed nonsignificant ( $P = 0.452$ ) alterations over time.

**Table 2.** Intragroup comparison of hard-tissue parameters at different time points in Group 1 and Group 2

Intragroup comparison of hard-tissue parameters in Group 1							
Parameter (mm)	Baseline	3 months	6 months	9 months	12 months	F	P
Mesial CBH	0.89±0.89	1.13±0.59	0.90±0.78	1.93±3.42	1.93±3.42	0.622	0.649
Distal CBH	0.83±0.85	0.80±0.68	0.73±0.78	0.63±0.71	0.63±0.71	0.170	0.953
RW 2 mm from crest	7.00±0.74	6.21±0.72	6.27±0.74	6.24±0.71	6.24±0.72	2.343	0.067
RW 4 mm from crest	9.27±0.97	8.69±0.78	8.73±0.71	8.62±0.65	8.46±0.62	1.778	0.148
Intragroup comparison of hard-tissue parameters in Group 2							
Parameter (mm)	Baseline	3 months	6 months	9 months	12 months	F	P

<b>Mesial CBH</b>	0.00±0.00	0.23±0.12	0.31±0.10	0.40±0.07	0.40±0.12	34.358	0.000**
<b>Distal CBH</b>	0.00±0.00	0.14±0.15	0.20±0.13	0.27±0.14	0.61±1.13	2.158	0.087
<b>RW 2 mm from crest</b>	6.54±0.49	6.16±0.53	6.10±0.56	6.08±0.53	5.87±0.43	2.496	0.054
<b>RW 4 mm from crest</b>	<b>9.06±0.71</b>	<b>8.94±0.66</b>	<b>8.80±0.62</b>	<b>8.80±0.62</b>	<b>8.55±0.62</b>	<b>0.934</b>	<b>0.452</b>

\*\*Highly significant ( $p<0.001$ ). Significant difference ( $P<0.05$ ). BBT – Buccal bone thickness; CBH – Crestal bone height; RW – Ridge width;  $P$  – Probability value;

$F$  –  $F$  value for analysis of variance; mm – Millimeter

**Tables 3 and 4** demonstrate the intragroup comparison of Group 1 and Group 2 between baseline and 12 months follow-up. Highly significant differences were observed in PI, GI, mSBI, PD, TS, and RW in both the groups ( $P < 0.05$ ).

**Table 3.** Intragroup comparison in Group I between baseline and 12 months

	<b>Baseline</b>	<b>12 months</b>	<b><math>t</math></b>	<b><math>P</math></b>
<b>PI</b>	1.45±0.52	0.14±0.50	0.830	0.000**
<b>GI</b>	1.7±0.25	1.31±0.24	0.713	0.000**
<b>mSBI</b>	1.0±0.71	0.85±0.74	2.563	0.000**
<b>PD (mm)</b>	2.78±0.50	2.45±0.5	-15.588	0.000**
<b>TS</b>				
<b>TS (a)</b>	0.00±0.00	1.09±0.83	-4.353	0.000**
<b>TS (b)</b>	1.55±0.52	1.55±0.52	0.000	1.000
<b>TS (c)</b>	1.55±0.52	1.55±0.52	0.000	1.000
<b>TS (d)</b>	0.55±0.52	1.55±0.52	-4.491	0.000**
<b>TS BBT (mm)</b>	0.90±0.16	1.43±0.38	-4.092	0.001*
<b>At crest</b>	1.67±0.55	1.47±0.48	0.901	0.378
<b>2 mm from crest</b>	1.58±0.35	1.60±0.30	-0.136	0.893
<b>Mid-implant level</b>	1.72±0.58	1.79±0.39	-0.301	0.767
<b>Apical level</b>	2.10±0.78	2.36±0.59	-0.853	0.404
<b>CBH (mm)</b>				
<b>Mesial</b>	0.89±0.89	1.93±3.42	-0.981	0.338
<b>Distal</b>	0.83±0.85	0.63±0.71	0.594	0.559
<b>RW (mm)</b>				
<b>2 mm from crest</b>	7.00±0.74	6.24±0.72	2.403	0.026*
<b>4 mm from crest</b>	<b>9.27±0.97</b>	<b>8.46±0.62</b>	<b>2.316</b>	<b>0.031*</b>

\*Significant ( $p<0.05$ ). \*\*Highly significant ( $p<0.001$ ). PI – Plaque index;

GI – Gingival index; mSBI – Modified sulcus bleeding index; PD – Probing depth; TS – Testori score; TS (a) – Presence and stability of the mesiodistal papilla; TS (b) – Score for texture of the peri-implant soft tissue; TS (c) – Score for color of the peri-implant soft tissue; TS (d) – Score for gingival score; BBT – Buccal bone thickness; CBH – Crestal bone height; RW – Ridge width;  $P$  – Probability value;  $t$  – Test statistic; mm – Millimeter

**Table 4.** Intragroup comparison in Group II between baseline and 12 months

	<b>Baseline</b>	<b>12 months</b>	<b><math>t</math></b>	<b><math>P</math></b>
<b>PI</b>	1.08±0.00	0.55±0.52	-3.464	0.002**

<b>GI</b>	1.7±0.25	1.31±0.24	2.341	0.001**
<b>mSBI</b>	1.0±0.71	0.85±0.74	1.765	0.000**
<b>PD (mm) Testori score</b>	0.00±0.00	2.18±0.60	-12.000	0.000**
<b>TS (a)</b>	0.00±0.00	1.36±0.50	-8.964	0.000**
<b>TS (b)</b>	1.45±0.52	1.64±5.0	-0.830	0.416
<b>TS (c)</b>	1.73±0.46	1.82±0.405	-0.488	0.631
<b>TS (d)</b>	0.00±0.00	1.45±0.52	-9.238	0.000**
<b>TS</b>	0.79±0.15	1.56±0.29	-7.680	0.000**
<b>BBT</b>				
<b>At crest (mm)</b>	1.02±0.32	1.76±0.24	-5.981	0.000**
<b>2 mm from crest (mm)</b>	1.77±0.46	1.91±0.38	-0.800	0.433
<b>Mid-implant level (mm)</b>	2.37±0.47	2.44±0.49	-0.351	0.729
<b>Apical level (mm)</b>	3.31±0.50	3.22±0.39	0.470	0.644
<b>CBH (mm)</b>				
<b>Mesial</b>	0.00±0.00	0.40±0.12	-11.112	0.000**
<b>Distal</b>	0.00±0.00	0.61±1.13	-1.807	0.086
<b>RW</b>				
<b>2 mm from crest (mm)</b>	6.54±0.49	5.87±0.43	3.368	0.003*
<b>4 mm from crest (mm)</b>	<b>9.06±0.71</b>	<b>8.55±0.62</b>	<b>1.784</b>	<b>0.090</b>

\*Significant (p<0.05). \*\*Highly significant (p<0.001). PI – Plaque index;

GI – Gingival index; mSBI – Modified sulcus bleeding index; PD – Probing depth; TS – Testori score; TS (a) – Presence and stability of the mesiodistal papilla; TS (b) – Score for texture of the peri-implant soft tissue; TS (c) – Score for color of the peri-implant soft tissue; TS (d) – Score for gingival score; BBT – Buccal bone thickness; CBH – Crestal bone height;

RW – Ridge width; P – Probability value; t – Test statistic; mm – Millimeter

The purpose of this clinical research was to examine the hard- and soft-tissue changes around immediate and delayed implants implanted with a flapless approach in the posterior segment. Soft and hard tissues are crucial in implant dentistry as they significantly influence the survival of dental implants. Preserving soft and hard tissues around the implant perimeter, as well as optimizing occlusion, can enhance the longevity of the implant. The flapless technique used in this study involved accessing the bone by punching out a small amount of soft tissue required for osteotomy preparation. Previous studies have reported that this technique helps to minimize interproximal crestal bone loss and possible loss of papillae [9-11]. The most distinctive feature of the present study is that it exclusively compares the individual Testori criteria assessing soft-tissue variations individually, as well as an overall score as TS.

In the present study, PI, GI, and mSBI significantly decreased with time in both the groups. This decrease was consistent with the studies of DeAngelo *et al.* [12] and Joly *et al.* [13] and can be attributed to satisfactory plaque control demonstrated by the patients due to repeated instructions in oral hygiene measures given at every recall visit.

The results of this study depict that the soft-tissue architecture, including the papillary fill and gingival contour of the peri-implant area, significantly improved after 12 months in both the groups. However, the papillary fill was better in the case of immediate implants compared to delayed ones. This may be attributed to the better CBH in immediate implant cases. There were no significant changes in the texture and color of peri-implant soft tissues in both the groups, implying that the immediate or delayed implant placement protocol does not really affect the soft-tissue quality. However, significant changes were observed in the gingival tissue contour, especially in Group 2. This indicates a more esthetic and harmonious gingival contour in immediate implant cases, unlike the delayed ones with more collapsed contours and lack of scalloping. The change in the magnitude of the BBT was significantly more in delayed implants compared to immediate ones.

The results of this study indicate that healing in Group 1 was significantly better than Group 2 in terms of preservation of crestal bone, which eventually prevented collapse of the gingival architecture. The treatment time,

preservation of esthetically acceptable gingiva, and enhanced patient comfort are among the other advantages achieved through immediate implants.

Strict guidelines, such as appropriate patient selection, atraumatic extraction, prophylactic antibiotic treatment, and sufficient osteotomy for primary stability, are necessary to promote osseointegration of rapid implant placement [14]. A buccolingual ridge decrease of around 50% of the initial RW during a 12-month period is often linked to delayed implant placement, with two-thirds of this bone remodeling occurring during the first 3 months of healing. Lekovic *et al.* [15] reported concomitant vertical bone remodeling of approximately 3–4 mm in at least 50% of the initial socket height at 6 months postextraction. As a result, late implant placement in healed sites is not usually advised, as it may demand sophisticated bone augmentation treatments in future. Delayed implant placement is an alternate therapeutic option that should be investigated, [16] which allows for the resolution of acute infection and increases the soft-tissue level. Such a protocol inhibits the extensive alveolar bone remodeling seen in completely healed areas. The evidence for predictability of immediate or early implant placement appears to be influenced in part by the variety of studies pertaining to the implant site, timing, implant position in the socket, bone wall abnormalities, and augmentation techniques.

The treatment outcomes demonstrated that healing in both the groups occurred as per the specified norms. Over the course of the investigation, no clinical variations in the results were noted. These results corroborate with recent studies that the healing of immediate and delayed implants does not vary clinically or radiographically.

Although Group 2 exhibited smaller RW at the first measurement, the pattern of coronal bone remodeling – a narrowing of the bucco-lingual width – was clinically similar for both the groups. This suggests that early remodeling may begin immediately following tooth extraction and continue, albeit unevenly, even after delayed implant placement. The CBH and RW alterations occurring in Group 2 were found to be similar when compared to the bone loss which occurred in Group 1. These results are consistent with the research conducted by Covani *et al.* [17] Since horizontal osseous formation in the excised socket is more significant than vertical osseous formation, the vertical dimension was not examined in this investigation.

It appeared from the present study that BBT in Group 1 implants hardly changed which was a very favorable outcome because it means that bone thickness achieved at placement of the final restoration remained stable [18]. Moreover, if future evaluation with longer follow-up evaluations confirms this finding, it would mean that after finishing treatment no major complications related to physiologic bone resorption should be expected. However, the BBT in case of Group 2 significantly changed after 12 months of follow-up. The initial BBT adjacent to implants may have a direct influence on both vertical and horizontal bone loss. However, no minimum threshold of facial bone thickness to an implant could be defined to prevent additional bone loss. No significant differences were found in BBT around Group 1 or Group 2 after 12 months. These findings are analogous to those of Chochlidakis *et al.* 2017 [19]. Arora and Ivanovski (2017) [20] examined the correlation between preoperative buccal cortical bone thickness and peri-implant tissue response following immediate placement and restoration of implants in the maxillary esthetic zone and demonstrated that no significant association could be established between preoperative buccal bone width, the soft tissue and esthetic outcome. Rathi *et al.* [21] assessed peri-implant tissue dimensions in dental implants with definitive abutment and repeated abutment replacements in 20 patients. They found that peri-implant marginal bone loss increased from baseline to 3 months in both the groups, and no significant differences were encountered.

The results also confirm previous findings that following immediate or delayed implant placement, bone remodeling occurs, leading to changes in the vertical and horizontal dimensions of peri-implant hard and soft tissues. These dimensional changes are more pronounced in cases of immediate implants due to higher bone remodeling after tooth extraction, which results in increased osteoclastic activity and greater bone resorption around the implant bed.

Several limitations, including a small sample size and a limited observation period, need to be addressed in future studies to assess soft- and hard-tissue health and validate the results. In addition, the type of abutment, implant length, and diameter may influence bone loss around implants, necessitating further evaluation considering different implant and abutment types, and implant-abutment connections.

## Conclusion

Within the limitations of the present study, it can be concluded that significant changes in the gingival contour and papillary fill were observed after 12 months in both Group 1 and Group 2 protocols. However, Group 1

showed greater gains in soft-tissue health and esthetics compared to Group 2. BBT and CBH showed nonsignificant changes after 12 months of implant placement when compared between both the groups. RW significantly changed in both the groups after 12 months of follow-up.

**Acknowledgments:** None

**Conflict of interest:** None

**Financial support:** None

**Ethics statement:** None

## References

1. Novaes AB Jr, Suaid F, Queiroz AC, Muglia VA, Souza SL, Palioto DB, et al. Buccal bone plate remodeling after immediate implant placement with and without synthetic bone grafting and flapless surgery: radiographic study in dogs. *J Oral Implantol*. 2012;38(6):687–98.
2. Kim JI, Choi BH, Li J, Xuan F, Jeong SM. Blood vessels of the peri-implant mucosa: a comparison between flap and flapless procedures. *Oral Surg Oral Med Oral Pathol Oral Radiol Endod*. 2009;107(4):508–12.
3. You TM, Choi BH, Li J, Xuan F, Jeong SM, Jang SO. Morphogenesis of the peri-implant mucosa: a comparison between flap and flapless procedures in the canine mandible. *Oral Surg Oral Med Oral Pathol Oral Radiol Endod*. 2009;107(1):66–70.
4. Edward J, George JM, Prakash DG. Evaluation of peri-implant soft tissues and hard tissues in titanium implants in immediate and delayed cases: a comparative study. *J Dent Implant*. 2017;7(1):3–10.
5. Silness J, Loe H. Periodontal disease in pregnancy. II. Correlation between oral hygiene and periodontal condition. *Acta Odontol Scand*. 1964;22:121–35.
6. Løe H. The gingival index, the plaque index and the retention index systems. *J Periodontol*. 1967;38(6):610–6.
7. Mombelli A, van Oosten MA, Schurch EJ Jr, Lang NP. The microbiota associated with successful or failing osseointegrated titanium implants. *Oral Microbiol Immunol*. 1987;2(3):145–51.
8. Testori T, Bianchi F, Del Fabbro M, Capelli M, Zuffetti F, Berlucchi I, et al. Implant aesthetic score for evaluating the outcome: immediate loading in the aesthetic zone. *Pract Proced Aesthet Dent*. 2005;17(2):123–30.
9. Divakar TK, Gidean Arularasan S, Baskaran M, Packiaraj I, Dhineksh Kumar N. Clinical evaluation of placement of implant by flapless technique over conventional flap technique. *J Maxillofac Oral Surg*. 2020;19(1):74–84.
10. Lahoti K, Dandekar S, Gade J, Agrawal M. Comparative evaluation of crestal bone level by flapless and flap techniques for implant placement: systematic review and meta-analysis. *J Indian Prosthodont Soc*. 2021;21(4):328–38.
11. Sunitha RV, Sapthagiri E. Flapless implant surgery: A 2-year follow-up study of 40 implants. *Oral Surg Oral Med Oral Pathol Oral Radiol*. 2013;116(3):e237–43.
12. DeAngelo SJ, Kumar PS, Beck FM, Tatakis DN, Leblebicioglu B. Early soft tissue healing around one-stage dental implants: clinical and microbiologic parameters. *J Periodontol*. 2007;78(10):1878–86.
13. Joly JC, de Lima AF, da Silva RC. Clinical and radiographic evaluation of soft and hard tissue changes around implants: A pilot study. *J Periodontol*. 2003;74(8):1097–103.
14. Narad C, Lingraj JB, Aulakh KK, Handa K, Kotrashetti SM, Pinto PX. Assessment of primary stability of the implant placed in prepared infected extraction sockets. *J Oral Biol Craniofac Res*. 2018;8(2):154–7.
15. Lekovic V, Kenney EB, Weinlaender M, Han T, Klokkevold P, Nedic M, et al. A bone regenerative approach to alveolar ridge maintenance following tooth extraction. Report of 10 cases. *J Periodontol*. 1997;68(6):563–70.
16. Schwartz-Arad D, Chaushu G. Immediate implant placement: A procedure without incisions. *J Periodontol*. 1998;69(7):743–50.

17. Covani U, Cornelini R, Barone A. Vertical crestal bone changes around implants placed into fresh extraction sockets. *J Periodontol.* 2007;78(5):810–15.
18. Meijer HJ, Slagter KW, Vissink A, Raghoobar GM. Buccal bone thickness at dental implants in the maxillary anterior region with large bony defects at time of immediate implant placement: A 1-year cohort study. *Clin Implant Dent Relat Res.* 2019;21(1):73-9.
19. Chochlidakis KM, Geminiani A, Papaspyridakos P, Singh N, Ercoli C, Chen CJ. Buccal bone thickness around single dental implants in the maxillary esthetic zone. *Quintessence Int.* 2017;48(4):295–308.
20. Arora H, Ivanovski S. Correlation between pre-operative buccal bone thickness and soft tissue changes around immediately placed and restored implants in the maxillary anterior region: A 2-year prospective study. *Clin Oral Implants Res.* 2017;28(9):1188–94.
21. Rathi PR, Kolte RA, Kolte AP. Comparative evaluation of peri-implant tissues in definitive and repeated abutment replacements: A randomized clinical trial. *J Indian Soc Periodontol.* 2022;26(1):44–50.