

## Long-Term Management Strategies for First Molar Agenesis: Space Closure Versus Implant Rehabilitation

Ethan Young<sup>1</sup>, Nathan R. Nelson<sup>1\*</sup>, Ethan Z. Hall<sup>1</sup>

<sup>1</sup>Department of Periodontology, Faculty of Health Sciences, University of Washington, Seattle, United States.

\*E-mail ✉ [nathan.nelson@outlook.com](mailto:nathan.nelson@outlook.com)

Received: 12 October 2021; Revised: 12 January 2022; Accepted: 15 January 2022

### ABSTRACT

This systematic review aimed to determine the effectiveness and success rates associated with the use of orthodontic closure and dental implants to replace missing first molars. The results of the research taken into consideration in this paper were presented using the Preferred Reporting Items of Systematic Reviews and Meta-Analyses (PRISMA) framework. 8 of the remaining papers were selected because they met the inclusion criteria after 32 articles were excluded due to duplication. The remaining articles were examined in both their abstracts and full texts to determine their eligibility for this systematic literature review. Five studies were considered to provide evidence for implants used to replace the lost first molar, while three studies were included to show support for orthodontic closure. Since dental implants do not involve the other teeth surrounding the missing tooth, unlike orthodontic closure, which involves the entire dentition, they appear to be a better option for therapy.

**Keywords:** Space closure, Implants, Orthodontics, First molar

**How to Cite This Article:** Young E, Nelson NR, Hall EZ. Long-Term Management Strategies for First Molar Agenesis: Space Closure Versus Implant Rehabilitation. *J Orthod Periodontal Biomater Res.* 2022;2(1):1-7. <https://doi.org/10.51847/9DX6wOBxlo>

### Introduction

One of the most significant teeth in the oral cavity is the first molar [1-3]. As one might expect, chewing food becomes more challenging when the first molar is lost. Eating meals like crisp fruits, veggies, and other tough foods can be challenging. You must have alternatives for replacements on hand when this occurs [4].

An infant's first molars, which erupt in the mouth between the ages of thirteen and fifteen months, are crucial for preserving the appropriate occlusal patterns and arch form. Adult patients typically need dental crowns to repair prior big restorations and preserve the integrity of their teeth because the anterior teeth typically decay earliest [5, 6].

Patients might get dental implants to replace their lost first molars. A dental implant is a tooth root that has been surgically placed into your mandible. When implanted, they function similarly to natural roots. Dental implants are capable of supporting complete dentures in addition to crowns and bridges.

In most cases, patients who have lost teeth will resume eating and have a more attractive grin. The complete procedure is anticipated to take many months since the dental implant must merge with the jawbone. The process of fusing the dental implant is called osseointegration. If some teeth are missing, an implant can assist replace several teeth in a row, such as molars and premolars. When a patient loses the majority of their teeth, a denture is typically the best alternative. During a consultation, we can discuss these choices in greater detail [7, 8].

Clinicians can better assess anchorage and treatment alternatives when they understand the biomechanical basis of space closure, which is one of the most complex orthodontic treatments because it requires a full grasp of biomechanics to prevent undesired outcomes.

Despite the wide range of appliance designs, space closure can be achieved by frictionless or friction-based mechanisms, each of which has pros and cons. The simplicity of sliding or friction mechanics makes them popular. Closing or opening up the space is one orthodontic treatment for missing molars. Before beginning therapy, a comprehensive evaluation of the case is necessary to be sure the advantages of the treatment will exceed any possible hazards [9, 10].

At times, space closure is still the best option, especially for children whose prosthetic rehabilitation is still problematic and should be postponed until the eruption and growth process is finished. To achieve the desired results, the biological and psychological characteristics of adult patients must be taken into consideration. Concomitant malocclusions, the growth of the third molar, and the presence or absence of additional teeth are some of the other elements that affect the decision-making process. The objective of orthodontic treatment is to meet the patient's expectations by using rational biomechanical principles [11, 12].

The uncompensated lack of molars is linked to several side effects, which often make treatment more difficult. Handling these cases can be difficult at times. Preventing these situations and treating them early with interdisciplinary therapy are crucial. When the first molars are lost too soon, it primarily depends on when they emerge in both arches [13].

A distal and lingual movement of anterior teeth towards the side where the initial primary molar teeth are lost may also impair the length of the mandibular arch in addition to the posterior consequences. To stabilize the position of the second primary molars and canines, it is recommended to use a space maintainer since the lack of a first primary molar in either arch approximates the eruption of the first molars.

The loss of the first permanent molars due to dental caries has a detrimental effect on both arches and occlusion, which is crucial for balanced occlusion [14].

It has been proposed that early excision of these teeth causes malocclusions of teeth, unilateral chewing, shifts in the midline, super-eruption of teeth on the opposite side of the mouth, and tilting of neighboring teeth. Periodontal issues are also brought on by the early loss of primary molars. Since this tooth is thought to be transitory, parental neglect of it is widespread. The first molar is thought to be the tooth in the permanent dentition most susceptible to decay because of its deep pits and fissures. If this tooth has rotted, it is crucial to try your hardest to save it. Preventive measures have no remedy! [15]

#### *Literature review*

The literature study offers a variety of treatment options for first molar loss. No artificial materials are required because an auto transplant can retain teeth and their periodontal genetic structure; nonetheless, the operation may expose the patient to surgical trauma, root resorption, infection, and ankylosis, with varying success rates. Many patients opt for dental implants, which are advised for patients with missing teeth or adequate bone density around the tooth loss area. Make sure they are in good health overall and will not have any serious health complications after oral surgery. These patients may also benefit from a fixed prosthetic solution, but there are some drawbacks, such as cost, partial abrasion of the basic tooth structure, secondary mechanics errors, and decay [16].

A single dental crown can be used to replace the tooth when only one first molar is lost. There are several choices to take into account in more complex scenarios [17].

An alternate method of treating the loss of first molars is orthodontic repositioning of nearby teeth, which does away with the necessity for implants or prosthetics and the expense and stress involved in their placement. Additionally, the treatment will require a minimal amount of extra time if additional orthodontic issues need to be fixed [18].

Orthodontic mechanics, including axial tipping and rotation, and anchorage units, depend heavily on precise control of orthodontic movement during extraction space closure. Depending on the clinical situation, the segmented arch approach can provide various moments that will produce the required force system. Positioning the T-loop in the center creates equal and opposing moments with little vertical force. While the distant component is tilted towards the extraction area, the segment near them experiences a higher root translation/movement due to decentralized T-loops [19].

In addition to closing the gap between the lower first molars, the second lower molar was extended into the region of the atrophic bone crest. The incisors and second lower molars were protracted simultaneously utilizing a modified helical loop in a continuous arch measuring 0.018 x 0.025 mm. Because the initial lower molars were lost so early, there was some vertical bone loss before tooth movement, but no areas of bone

dehiscence/fenestrations or root resorption were seen at the end of this orthodontic therapy. Similar findings have been made by other writers [20, 21].

It is important to see the ultimate placement of lower roots in this instance. The second molar's final position was not vertical due to minor tipping as the space was closed. Rather, the teeth were inclined in the direction of the safe spot. In orthodontic treatment, root parallelism is generally regarded as a crucial objective for long-term stability. The six-year follow-up record shows that, despite the nonparallel roots at the end of the treatment, the tooth placements stayed constant for six years [20, 22].

#### *Aims of the study*

The purpose of this systematic review was to determine the efficacy and success rates related to the use of orthodontic closure and dental implants to replace missing first molars.

### **Materials and Methods**

#### *Study selection*

The preferred reporting items of systematic reviews and meta-analyses (PRISMA) framework were used to present the findings of the studies considered in this paper. The articles reviewed in this paper were located online after performing a literature search through different electronic databases, including Cochrane Library, Web of Science, and PubMed. The search yielded a total of 112 relevant articles as shown in **Figure 1**. A keyword strategy was used to increase the chances of identifying the most relevant articles with studies linked to the topic. The most important keywords and phrases that were used include “Orthodontic space closure”, “Implant”, “missing the first molar”, and “replacing the first molar”. This was followed by a review of the titles of the identified articles to determine their relevance to the topic of the research. A total of 32 articles were excluded because of duplication as shown in **Figure 1**. The remaining articles were reviewed, including their abstracts as well as their full texts to determine their eligibility for this systematic literature review, whereby 8 of them were selected because they met the inclusion criteria as shown in **Figure 1**.

#### *Inclusion criteria*

Articles were selected if they met all of the following criteria. First, the article must be a Case-control or cohort or controlled or randomized control study. Secondly, it must be a study published between 2010 and 2020. Third, it must have been published in English. Fourth, participants must be humans.

#### *Exclusion criteria*

Articles were excluded from the systematic review based on the following criteria. First, participants were treated for missing teeth other than the first molar. Secondly, all non-English articles were excluded. Third, non-empirical publications (including expert opinions and narrative reviews) did not meet the threshold for inclusion in this systematic review. Fourth, articles publishing studies out of the specified time range. Finally, the articles involve animal studies or laboratory-based studies.

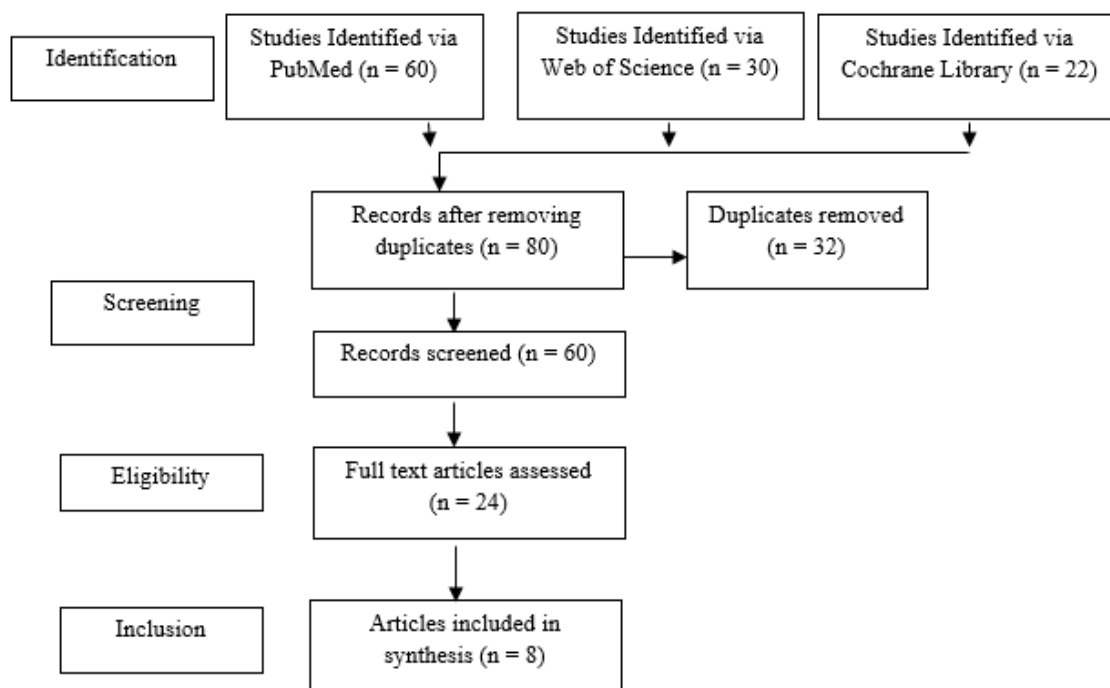


Figure 1. Flow diagram

*Risk of bias assessment*

All studies were evaluated for quality using the Cochrane risk of bias assessment tool (Table 1).

Table 1. Summary of Cochrane risk of bias assessment

Study	Selection bias/appropriate control selection/baseline characteristics similarity	Selection bias in randomization	Selection bias in allocation concealment	Performance-related bias in blinding	Reporting bias/selective reporting of outcomes	Detection bias Blinding outcome assessors	Accounting for confounding bias
Mazor <i>et al.</i> [14]	+	+	+	+	+	+	-
Anitua <i>et al.</i> [23]	+	+	+	-	-	-	-
Chhibber and Upadhyay [24]	+	+	+	+	+	-	-
Kumar <i>et al.</i> [25]	+	+	+	+	+	+	-
Raveli <i>et al.</i> [26]	+	+	+	-	+	+	+
Dhole and Maheshwari [27]	+	+	+	+	+	+	-
Meloni <i>et al.</i> [28]	+	+	+	+	+	+	-

**Results and Discussion**

*Orthodontic closure*

When the mandibular second molar was being protracted into the first molar extraction site, Chhibber and Upadhyay [24] demonstrated that a fixed functional device for anchoring reinforcement was advantageous. Dhole and Maheshwari [27] state that the initial setup and leveling phase of the orthodontic device should take the third molars into account. Molar teeth that have been tilted or inclined in extraction gaps may be straightened with the help of orthodontic auxiliaries. The goal of this gap closure technique is to guarantee that the premolar and second

molar roots are parallel. If they are motivated to do so, patients who have had their first molars extracted or who are in danger of losing them may still benefit from orthodontic space closure therapy.

Adult patients without implants or prostheses can have their edentulous space treated using a segmented arch technique based on differential moments of the T-loop, as proposed by Raveli *et al.* [26]. By extracting the upper bicuspids in conjunction with retraction, the early loss of the first lower permanent molars can be restored. No bone fenestrations, dehiscence, or root resorption were observed as a result of this operation. As a result, it provides a secure substitute for treatment.

#### *Implant placement*

One lost posterior tooth may be successfully restored with a distal offset from a single implant, per Anitua *et al.* [23]. The long-term effectiveness of implants with follow-up periods ranging from loading to about ten years, with an average of four years, was examined in terms of prosthetic problems, minimum bone loss, and survival. The findings of this study are consistent with replacing a single lost posterior tooth in an area of limited mesiodistal dimension using offset implant insertion. Kumar *et al.* [25] looked at whether using an implant to replace a single lost tooth enhances patient comfort and masticatory efficiency. The study's findings indicate that patients are more satisfied with implant restorations and favor shorter rehabilitation treatment durations.

The results of using two dental implants with a small diameter to restore a single molar region were given by Mazor *et al.* (2012). To restore the whole set of teeth, 33 patients had implants to replace their missing first molars, for 66 implants. In light of the data, replacing a single missing molar with two dental implants of narrow diameter might be an effective treatment option with satisfactory and predictable long-term outcomes. Meloni *et al.* [28] created a split-mouth design prospective randomized trial. To replace their lost mandibular first molars, 20 patients were randomized to receive either instantaneously loaded or conventionally loaded single implants. 40 implants were inserted successfully. The present results support the replacement of missing primary molars with implants, notwithstanding the limitations of the study.

Two common methods for losing a primary tooth were investigated in this systematic study. First, it's critical to recognize that a variety of variables contribute to the development of the mandible and the remainder of the nasomaxillary complex. The constant changes that take place from infancy and adolescence through young adulthood and adults may be explained by teeth and their supporting tissues' capacity to adapt to changing functional demands throughout life.

This complex site presents difficulties for orthodontic therapy (space closure), implant implantation, and other prosthodontic replacements. Evaluating the existing research from earlier studies demonstrates the advantages and disadvantages of both options [29].

Occlusal forces may cause the surrounding teeth to move, creating a gap where the two sets of teeth would typically meet if a missing first molar is not replaced. The health of teeth near the end of the distal teeth may be harmed by increased soft tissue pocketing brought on by pointed molars.

By extending the remaining teeth, these adverse effects can be avoided. According to scientific testimony, posterior mandibular gaps of 8 to 12 millimeters could be sealed by protracting the posterior teeth. During follow-ups, patients who underwent medialization and stabilization stated that their protruding posterior teeth continued to protrude without the edentulous gaps reopening or the depth of their pockets increasing. A long molar in an edentulous region with a thin resorbed ridge was formerly believed to have a worse prognosis. However, prior studies indicate that this might not be the case [30].

In the absence of skeletal anchorage in the anterior dentition/PM, it was demonstrated that the medialization of the second molars had a greater detrimental effect on the incisors integrated into the anterior anchoring unit. Soft tissues shift posteriorly and change profile as a result of these detrimental effects. This is crucial to keep in mind when applying this therapeutic approach [31]. One of the main problems with orthodontic closure is the length of the treatment time. An implant-supported mechanical approach was used to achieve bilateral maxillary orthodontic traction of the second and third upper molars into the missing maxillary first molar space without the need to retract or even use the front teeth [32]. Compared to the averages for molar mesialization described in the literature, a 12-month treatment duration is significantly shorter. Pursuing the intended facial aesthetics, functional occlusion, stability, and expression did not present any unforeseen challenges.

The dentist is ultimately in charge of determining which implant should be used in patients, even though regulatory bodies set the foundation for clinical acceptance. The clinical decision-making process should be evidence-based to deliver high-quality care and reduce the possibility of legal consequences for errors. This is particularly true

when beginning therapy in known high-risk groups. While information on the short- to medium-term success rates of various implant systems has been collected, it appears that there is a lack of long-term data comparing and evaluating the various advantages and disadvantages of different systems. Appropriate criteria pertinent to the collective clinical experience must be established. Expanding field use requires ongoing advancements in surgical technique and implant hardware [33].

## Conclusion

When choosing between orthodontic closure and dental implants to replace the lost first molar, time is a crucial consideration. Given that dental implants do not involve the surrounding teeth, unlike orthodontic closure, which involves the entire dentition, they appear to be a superior option for therapy than orthodontic closure.

**Acknowledgments:** We would like to acknowledge the help of Riyadh Elm University research center.

**Conflict of interest:** None

**Financial support:** None

**Ethics statement:** This study fulfills the ethical requirements of Riyadh Elm University.

## References

1. Jongjai S, Saising J, Charoensub R, Phuneerub P. Quality evaluation, GC/MS analysis and antimicrobial activities of morinda citrifolia against oral microorganisms. *J Adv Pharm Educ Res.* 2021;11(3):70-6.
2. Nguyen HC, Nguyen TT, Vo TH. Unlicensed and off-label utilization of oral drugs in pediatrics in a Vietnamese tertiary teaching hospital. *Arch Pharm Pract.* 2020;11(3):89-95.
3. Asgari I, Soltani S, Sadeghi SM. Effects of iron products on decay, tooth microhardness, and dental discoloration: a systematic review. *Arch Pharm Pract.* 2020;11(1):60-82.
4. Jetpurwala M, Sawant KR, Jain PS, Dedhia SP. Parental perception of the importance of the permanent first molar in their children. *J Dent Child.* 2020;87(1):26-30.
5. Ballullaya SV, Vemuri S, Kumar PR. Variable permanent mandibular first molar: review of literature. *J Conserv Dent.* 2013;16(2):99.
6. Seehra J, Al-Ali A, Pandis N, Cobourne MT. Space closure versus space opening for bilateral absent upper lateral incisors: what is the duration of orthodontic treatment? *Eur J Orthod.* 2020;42(4):460-5.
7. Alghamdi HS, Jansen JA. The development and future of dental implants. *Dent Mater J.* 2020:2019-140.
8. Chivte P, Asnani K, Basu B, Jadhav MN. Digital implantology full mouth reconstruction by complete 3D virtual workflow. *J Dent.* 2022;121:104023.
9. Smith TM, Machanda Z, Bernard AB, Donovan RM, Papakyrikos AM, Muller MN, et al. First molar eruption, weaning, and life history in living wild chimpanzees. *Proc Natl Acad Sci.* 2013;110(8):2787-91.
10. Sebastian B, Bhuvanaraghan A, Thiruvengkatachari B. Orthodontic space closure in sliding mechanics: a systematic review and meta-analysis. *Eur J Orthod.* 2022;44(2):210-25.
11. Mohammed H, Rizk MZ, Wafaie K, Almuzian M. Effectiveness of nickel-titanium springs vs elastomeric chains in orthodontic space closure: a systematic review and meta-analysis. *Orthod Craniofac Res.* 2018;21(1):12-9.
12. Aldosari MA, Alqasir AM, Alqahtani ND, Almosa NA, Almoammar KA, Albarakati SF. Evaluation of the airway space changes after extraction of four second premolars and orthodontic space closure in adult female patients with bimaxillary protrusion—a retrospective study. *Saudi Dent J.* 2020;32(3):142-7.
13. Ribeiro GL, Jacob HB. Understanding the basis of space closure in Orthodontics for a more efficient orthodontic treatment. *Dent Press J Orthod.* 2016;21:115-25.
14. Mazor Z, Lorean A, Mijiritsky E, Levin L. Replacement of a molar with 2 narrow diameter dental implants. *Implant Dent.* 2012;21(1):36-8.
15. Silveira GS, de Almeida NV, Pereira DM, Mattos CT, Mucha JN. Prosthetic replacement vs space closure for maxillary lateral incisor agenesis: a systematic review. *Am J Orthod Dentofacial Orthop.* 2016;150(2):228-37.

16. Li J, Jansen JA, Walboomers XF, van den Beucken JJ. Mechanical aspects of dental implants and osseointegration: a narrative review. *J Mech Behav Biomed Mater.* 2020;103:103574.
17. Panchal N, Mahmood L, Retana A, Emery R. Dynamic navigation for dental implant surgery. *Oral Maxillofac Surg Clin.* 2019;31(4):539-47.
18. Saga AY, Maruo IT, Maruo H, Guariza Filho O, Camargo ES, Tanaka OM. Treatment of an adult with several missing teeth and atrophic old mandibular first molar extraction sites. *Am J Orthod Dentofacial Orthop.* 2011;140(6):869-78.
19. Lombardo L, Latini MC, Siciliani G. Optimal parameters for final position of teeth in space closure in case of a missing upper lateral incisor. *Prog Orthod.* 2014;15(1):1-2.
20. Aghoutan H, Alami S, El Aouame A, El Quars F. Orthodontic management of residual spaces of missing molars: decision factors. In *Human Teeth-Key Skills and Clinical Illustrations 2019.* IntechOpen.
21. Naoum S, Allan Z, Yeap CK, Razza JM, Murray K, Turlach B, et al. Trends in orthodontic management strategies for patients with congenitally missing lateral incisors and premolars. *Angle Orthod.* 2021;91(4):477-83.
22. Nahm KY, Iskenderoglu NS, Lee JA, Lee JY, Chung KR, Kim SH, et al. Autotransplantation of premolars and space closure in a patient with inflamed sinuses. *Am J Orthod Dentofacial Orthop.* 2019;155(2):276-87.
23. Anitua E, Murias-Freijo A, Flores J, Alkhraisat MH. Replacement of missing posterior tooth with off-center placed single implant: long-term follow-up outcomes. *J Prosthet Dent.* 2015;114(1):27-33.
24. Chhibber A, Upadhyay M. Anchorage reinforcement with a fixed functional appliance during protraction of the mandibular second molars into the first molar extraction sites. *Am J Orthod Dentofacial Orthop.* 2015;148(1):165-73.
25. Kumar Y, Chand P, Arora V, Singh SV, Mishra N, Alvi HA, et al. Comparison of rehabilitating missing mandibular first molars with implant-or tooth-supported prostheses using masticatory efficiency and patient satisfaction outcomes. *J Prosthodont.* 2017;26(5):376-80.
26. Raveli TB, Shintcovsk RL, Knop LA, Sampaio LP, Raveli DB. Orthodontic replacement of lost permanent molar with neighbor molar: a six-year follow-up. *Case Rep Dent.* 2017;2017.
27. Dhole PM, Maheshwari DO. Orthodontic space closure using simple mechanics in compromised first molar extraction spaces: case series. *J Indian Orthod Soc.* 2018;52(1):51-9.
28. Meloni SM, Baldoni E, Duvina M, Pisano M, De Riu G, Tallarico M. Immediate non-occlusal versus delayed loading of mandibular first molars. Five-year results from a randomised controlled trial. *Eur J Oral Implantol.* 2018;11(4):409-18.
29. Thilander B. Orthodontic space closure versus implant placement in subjects with missing teeth. *J Oral Rehabil.* 2008;35:64-71.
30. Baik UB, Kim MR, Yoon KH, Kook YA, Park JH. Orthodontic uprighting of a horizontally impacted third molar and protraction of mandibular second and third molars into the missing first molar space for a patient with posterior crossbites. *Am J Orthod Dentofacial Orthop.* 2017;151(3):572-82.
31. Jacobs C, Jacobs-Müller C, Luley C, Erbe C, Wehrbein H. Orthodontic space closure after first molar extraction without skeletal anchorage. *J Orofac Orthop.* 2011;72(1):51-60.
32. Wilmes B, Vasudavan S, Drescher D. Maxillary molar mesialization with the use of palatal mini-implants for direct anchorage in an adolescent patient. *Am J Orthod Dentofacial Orthop.* 2019;155(5):725-32.
33. Henry PJ. Clinical experiences with dental implants. *Adv Dent Res.* 1999;13(1):147-52.