

Clinical Assessment of Platelet-Rich Fibrin as a Barrier Membrane in the Management of Grade II Furcation Defects

Khalid M. Saad¹, Rana K. Farouk¹, Fatima U. Rahman^{1*}, Mariam T. Al-Mutairi¹, Lina M. Saleh¹

¹Department of Dental Public Health, School of Dentistry, Sultan Qaboos University, Muscat, Jordan.

*E-mail ✉ fatima.rahman@hotmail.com

Received: 19 April 2022; Revised: 27 May 2023; Accepted: 02 June 2023

ABSTRACT

Various guided tissue regenerative procedures have been used in treatment of furcation defects. A combination of various graft materials and barrier membranes have been used over a period of time. The present study was designed to test whether autologous platelet-rich fibrin (PRF) can be effectively used as a barrier membrane along with porous hydroxyapatite (HA) bone graft in the treatment of Grade II furcation defects. The present study was a split-mouth design, in which a total of thirty patients with bilateral grade II furcation defects in the mandibular molars were selected. On the control side, the furcation defect was treated using only HA bone graft and in the test side, the furcation defect was treated using a combination of HA bone graft and PRF as barrier membrane. The clinical and radiological parameters were recorded presurgically, postsurgical at 3 and 6 months, respectively, and the results were statistically analyzed and compared. The furcation defects treated in the test side showed better healing and bone fill when compared to control side. The clinical parameters of the test and control sides when compared were found to be statistically significant. PRF can be effectively used as barrier membrane along with a graft material thus enhancing the regenerative potential of the graft material while regenerating the lost periodontal tissue in Grade II furcation defects.

Keywords: Barrier membrane, Furcation defects, Guided tissue regeneration, Platelet-rich fibrin

How to Cite This Article: Saad KM, Farouk RK, Rahman FU, Al-Mutairi MT, Saleh LM. Clinical Assessment of Platelet-Rich Fibrin as a Barrier Membrane in the Management of Grade II Furcation Defects. *J Orthod Periodontal Biomater Res.* 2023;3(1):81-9. <https://doi.org/10.51847/GQnHLqAYvo>

Introduction

Periodontal disease is a highly complex disease characterized by connective tissue attachment loss leading to destruction of supporting periodontal tissues.[1, 2] The treatment protocol for periodontitis mainly aims at reducing the inflammation resulting in stoppage of the disease progression. It also aims to regenerate the lost supporting tissues by surgical process.[3] Over the years, it has been a challenge for the periodontists to regenerate these lost tissues especially in the furcation areas. To achieve this goal, multiple regenerative approaches involving autografts, allografts and xenografts have been successfully used.[3, 4] However, the use of guided tissue regeneration (GTR), in which barrier membranes are placed over bone grafts at the furcation defect site, is the most preferred treatment.[4–7] Research is being done on the use of growth factors in barrier membranes to regulate the healing process for regeneration of lost periodontal tissues.

Various studies of treatment of furcation defects using the principle of GTR have been carried out till date.[3, 4] A resorbable collagen membrane is the ideal barrier membrane used till date, but because of its certain drawbacks, newer materials are being tried out as barrier membranes. The latest material being tried out for a barrier membrane is platelet-rich fibrin (PRF) generated out of the patients own blood. PRF is a second-generation

barrier membrane which consists of a combination of growth factors, cytokines, glycan chains, and glycoproteins encompassed within a network of polymerized fibrin leading to more synergetic effects on the healing process.[8] PRF membranes have been successfully used in maxillofacial surgeries during sinus augmentation procedures.[9, 10] Since, PRF had already been successfully used as barrier membrane in the treatment of angular bone defects, it was conceptualized to use the same PRF as a barrier membrane in management of Grade II furcation defects. Considering all these facts, the present split mouth study was planned and designed to evaluate the effectiveness of autologous PRF as a barrier membrane in the treatment of human mandibular Grade II furcation defects. The study protocol was approved by the Institutional Ethical committee and the study was conducted in accordance with the Helsinki Declaration of 1975, as revised in 2000.

Materials and Methods

A total of 30 patients between the age groups of 18 and 55 years having Grade II furcation defects bilaterally in mandibular first/second molars were selected randomly, with no discrimination on the basis of gender or socioeconomic status. Patients with medical problems that would contraindicate routine periodontal surgery, patients with known systemic diseases such as diabetes and/or drug therapy known to interfere with soft tissue and bone healing, patients who had taken antibiotics during the last 6 months of initial examination, pregnant or lactating female patients, smokers and those with known allergic responses to hydroxyapatite (HA) graft material were excluded from the study. In addition, teeth with interproximal intrabony defects, endodontic involvement and mobility were also excluded. Informed consent to be a part of the study was obtained from all the selected patients. Presurgically, oral hygiene parameters which consisted of plaque index (PI),[11] bleeding index (BI),[12] and gingival index (GI),[13] clinical parameters consisting of vertical probing depth (VPD), horizontal probing depth (HPD), vertical clinical attachment level (VAL) and horizontal clinical attachment level (HAL) for the selected mandibular molars on both the sides were recorded by an independent examiner for all the patients. Both VPD (measured using Williams periodontal probe) and HPD (measured using a Naber's probe) were calculated (in mm) as the depth of the probe which penetrated the gingival sulcus from the gingival margin in vertical and horizontal directions respectively. Both VAL and HAL were measured (in mm) from the cemento-enamel junction to the depth of penetration of the probes.[2]

Intraoral periapical (IOPA) radiographs were also recorded for the selected mandibular molars. Initial therapy was performed on all patients which consisted of full mouth scaling and root planing. This preparatory phase was continued for 4 weeks till the patient showed satisfactory plaque control. Presurgical hematological investigations were carried out for all the patients. One side of the mouth having one of the selected mandibular tooth with furcation defect was assigned to the control side and the contralateral side selected mandibular molar tooth was assigned to the test side by the flip of a coin.

Once the clinical and radiological parameters were recorded (**Figure 1**), the patients were taken up for the surgical procedures. For surgery on the control side, intraoral antiseptics was performed with 0.12% chlorhexidine gluconate rinse. Extraoral scrubbing with iodine solution was done to achieve extraoral antiseptics. After anaesthetizing the control side molar with local anesthesia, an intrasulcular incision was made in the buccal aspect of the selected mandibular molar extending to the distobuccal line angle of the adjacent front tooth and mesiobuccal line angle of the adjacent back tooth, and a full-thickness mucoperiosteal flap was reflected to exposure of the furcation defect. The area was degranulated using area specific gracey curettes followed by thorough scaling and root planing to clearly expose and measure the furcation defect (**Figure 2a**). The HA bone graft material was mixed with saline to form a homogenous mass and was packed into the furcation defect (**Figure 2b**). The flap was replaced back in position and sutured by interrupted suturing using 3/0 silk sutures (**Figure 2c**). A periodontal pack (Coe Pack) was placed postoperatively for protection against mechanical trauma as well as for stability of surgical site (**Figure 2d**) and the patient was prescribed antibiotics and analgesics. Postoperatively, the sutures were removed after 7 days.

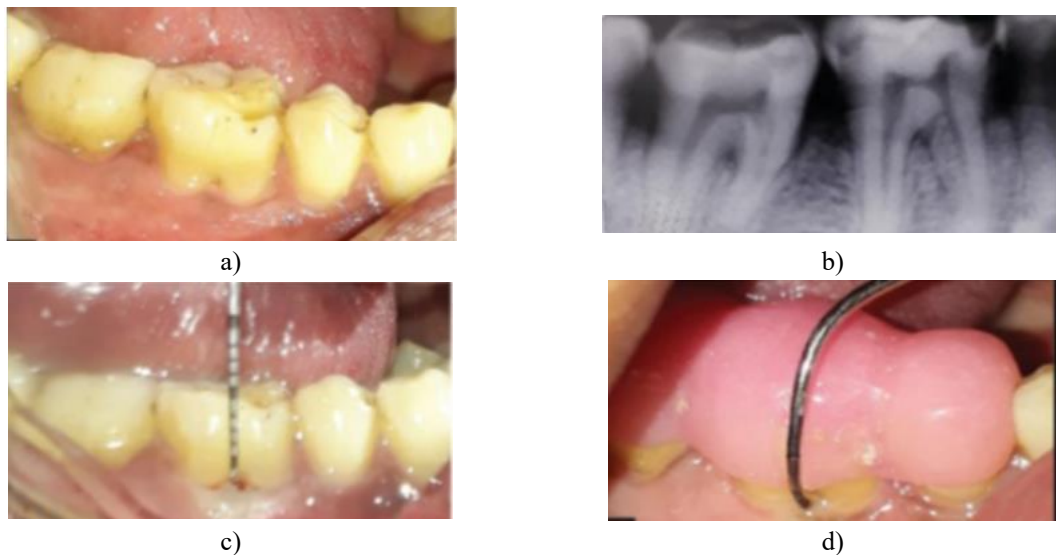

Figure 1: (a) Pre-operative image of control site, (b) Pre-operative intraoral periapical radiograph of the tooth with grade II furcation, (c) Presurgical vertical probing depth measurements, (d) Presurgical horizontal probing depth measurements

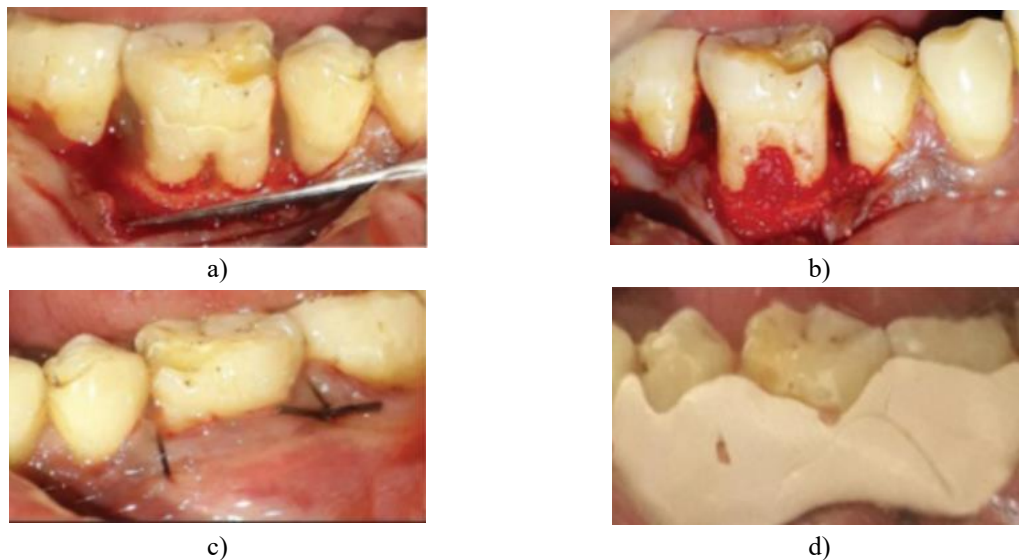


Figure 2: (a) Full thickness flap reflection, (b) Packing of the furcation defect with porous hydroxyapatite bone graft, (c) Interrupted sutures given, (d) Periodontal dressing placed over the treated area

For surgery on the test side, just before the surgery once the clinical and radiological parameters were recorded (**Figure 3**), intravenous blood (by venipuncturing of the antecubital vein) was collected in 10 ml sterile vacutainer tube without anticoagulant and immediately centrifuged in a centrifugation machine at 3,000 revolutions per minute for 12 min. PRF was obtained after separating the PRF component from the Plasma and red blood cells. This PRF was then converted into PRF membrane using a PRF box. The surgical procedure similar to that of the control side was performed on the tooth of the test side (**Figures 4a , 4b**). The only difference was that, after filling the furcation defect with HA bone graft (**Figure 4c**), PRF membrane was placed on the defect as a barrier membrane so that the coronal aspect of the membrane did not extend beyond the cemento enamel junction (**Figure 4**).

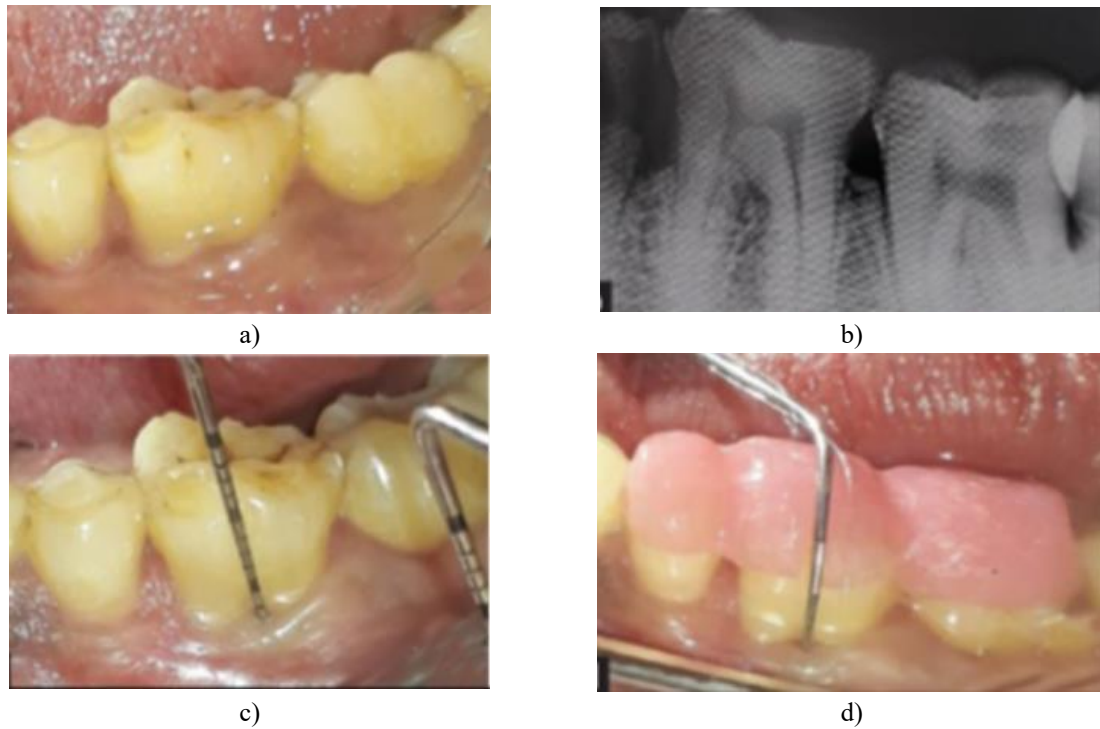


Figure 3: (a) Pre-operative image of test site, (b) Pre-operative intraoral periapical radiograph of the tooth with grade II furcation, (c) Presurgical measurements of vertical probing depth, (d) Presurgical measurements of horizontal probing depth

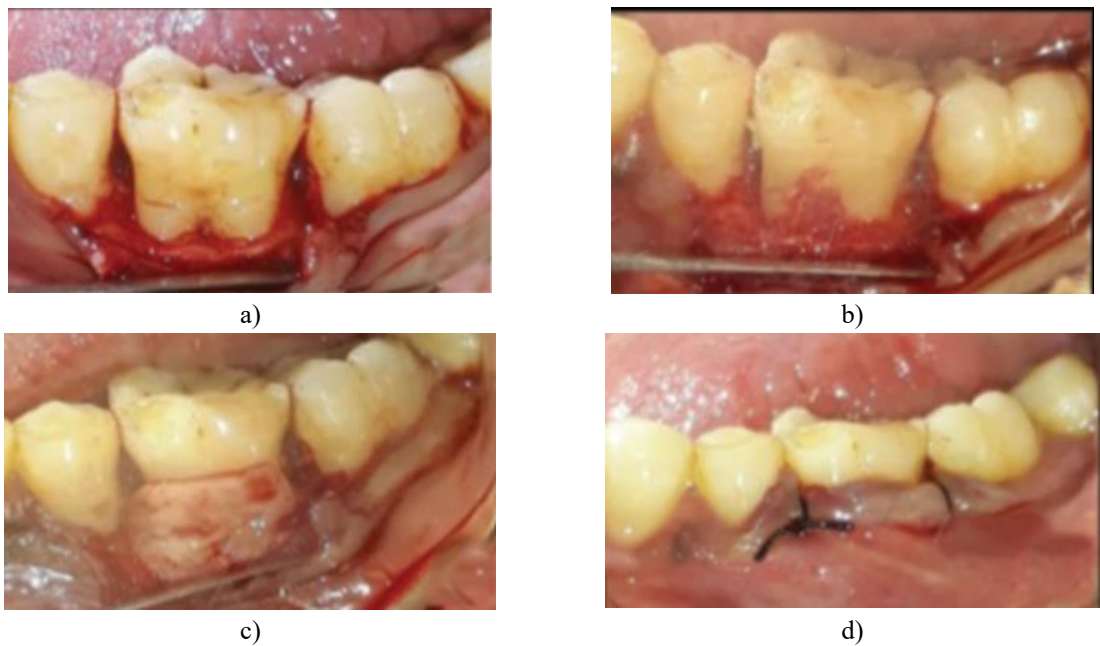


Figure 4: (a) Full thickness flap reflection, (b) Packing of the furcation defect with porous hydroxyapatite bone graft, (c) Placement of PRF over the packed bone graft, (d) Interrupted sutures given

After the removal of sutures 7 days postoperatively, the patients were put on regular follow up every month. The oral hygiene, clinical and radiological parameters were recorded at postoperative 3 and 6 months respectively for both the control sides (**Figure 5**) as well as the test sides (**Figure 6**). The results obtained were tabulated formulated and then were statistically analyzed.

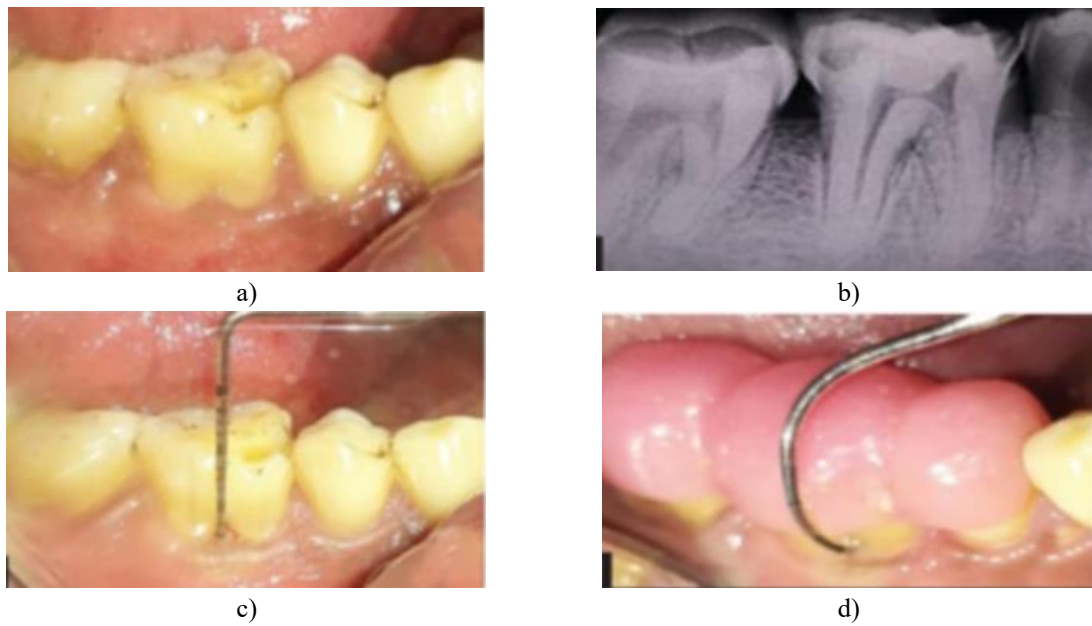


Figure 5: (a) Post-operative image of control site, (b) Post-operative intraoral periapical radiograph of the tooth with grade II furcation, (c) Postsurgical measurements of vertical probing depth, (d) Postsurgical measurements of horizontal probing depth

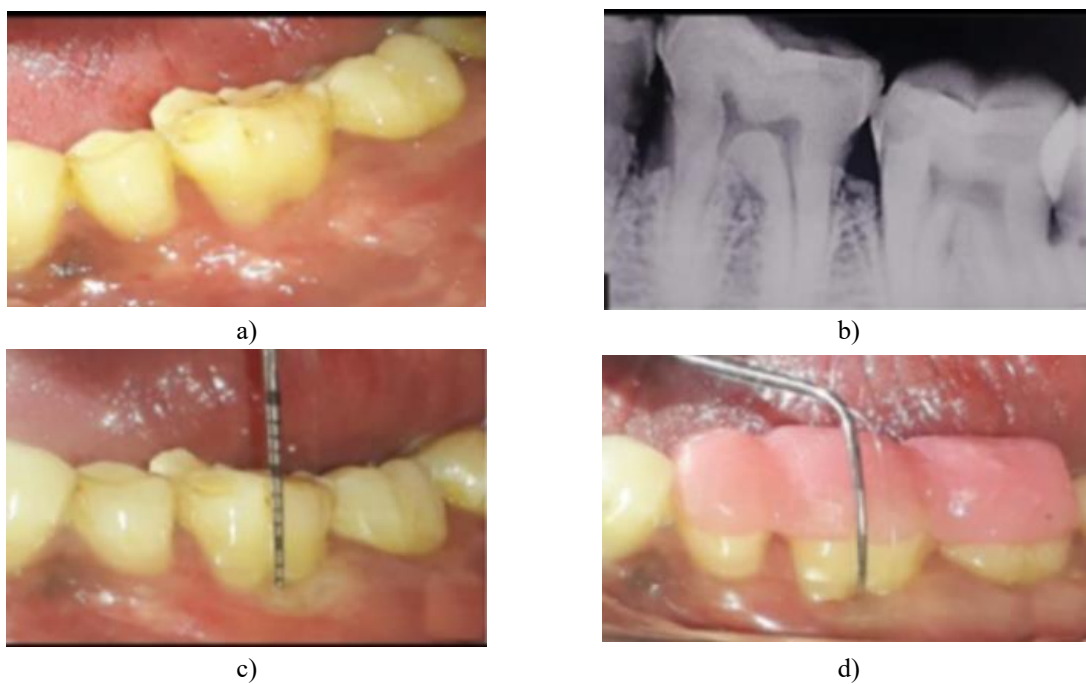


Figure 6: (a) Post-operative image of test site, (b) Post-operative intraoral periapical radiograph of the tooth with grade II furcation, (c) Postsurgical measurements of vertical probing depth, (d) Postsurgical measurements of horizontal probing depth

Results and Discussion

The statistical analysis was done through SPSS for Windows Version 14.0 Evaluation version (SPSS, 2005. SPSS Inc., New York, NY, USA). “*P*” value was set at 0.05 for the statistical significance. Normality assumption of the data was tested using Shapiro–Wilk *W* test. Paired *t*-test and unpaired *t*-test were used subsequently for intragroup and intergroup comparisons’ respectively.

Of the 30 patients included for the study, 17 (56.6%) were males and 13 (43.4%) were females. The mean age of males was 43.41 ± 6.95 years and the mean age of females was 39.69 ± 8.99 years.

Wound healing was uneventful for all treated cases. No significant visual differences were noted between the treatment of test and control sides. There was a significant reduction in the PI, BI and GI on both the test and the control sides. The mean PI for the control side reduced from presurgical 3.08 ± 0.743 – 1.25 ± 0.568 post surgically and on test side from 3.03 ± 0.642 pre surgically to 1.21 ± 0.448 post surgically (**Table 1**). All oral hygiene parameters in both test and control sides improved post surgically (**Table 2**). However, the improvements post 3 months were not so significant (**Table 1**).

Table 1: Inter group comparison of clinical parameters

Parameter	Control group (mean)	Test group (mean)	Intergroup comparison (P)
Plaque index-baseline	3.08±0.743	3.03±0.642	0.557
Plaque index-3 months	1.30±0.714	1.23±0.583	0.693
Plaque index-6 months	1.25±0.568	1.21±0.448	0.801
Gingival index-baseline	2.51±0.371	2.56±0.314	0.575
Gingival index-3 months	0.81±0.495	0.70±0.390	0.315
Gingival index-6 months	0.91±0.379	0.83±0.257	0.323
Bleeding index-baseline	2.60±0.271	2.57±0.323	0.672
Bleeding index-3 months	0.47±0.311	0.35±0.220	0.083
Bleeding index-6 months	0.67±0.251	0.59±0.237	0.199
VPD-baseline	4.73±1.639	4.86±1.634	0.753
VPD-3 months	2.26±0.784	1.86±0.628	0.033
VPD-6 months	1.83±0.592	1.36±0.490	0.001
HPD-baseline	5.53±1.717	5.40±1.734	0.765
HPD-3 months	3.56±1.331	2.76±1.006	0.011
HPD-6 months	3.26±1.230	2.46±0.819	0.004
VAL-baseline	5.30±0.794	5.43±0.727	0.500
VAL-3 months	3.46±0.730	2.93±0.739	0.006
VAL-6 months	3.13±0.730	2.46±0.571	0.000
HAL-baseline	7.03±1.217	7.16±1.053	0.651
HAL-3 months	5.10±1.155	3.86±0.730	0.000
HAL-6 months	4.86±0.937	3.56±0.568	0.000

VPD – Vertical probing depth; HPD – Horizontal probing depth; VAL – Vertical attachment loss; HAL – Horizontal attachment loss; P – Probability value

Table 2: Intra group comparison of clinical parameters

Parameter	Baseline versus 3 months	Baseline versus 6 months	3 months versus 6 months
Plaque index-control	0.000	0.000	0.572
Plaque index-test	0.000	0.000	0.856
Gingival index-control	0.000	0.000	0.089
Gingival index-test	0.000	0.000	0.020
Bleeding index-control	0.000	0.000	0.000
Bleeding index-test	0.000	0.000	0.000
VPD-control	0.000	0.000	0.004
VPD-test	0.000	0.000	0.000
HPD-control	0.000	0.000	0.036
HPD-test	0.000	0.000	0.001
VAL-control	0.000	0.000	0.009
VAL-test	0.000	0.000	0.001
HAL-control	0.000	0.000	0.005
HAL-test	0.000	0.000	0.001

VPD – Vertical probing depth; HPD – Horizontal probing depth; VAL – Vertical attachment loss; HAL – Horizontal attachment loss

Both the VPD and HPD for both the test and the control sides were found to be improved post surgically. The mean VPD for the control side reduced from pre surgical 4.73 ± 1.639 mm to 1.83 ± 0.592 post surgically and on the test side from presurgical 4.86 ± 1.634 mm to 1.36 ± 0.490 mm post surgically (**Table 1**). Similarly, the HPD reduced to 3.26 ± 1.230 mm from 5.53 ± 1.717 mm on control side and to 2.46 ± 0.819 mm from 5.40 ± 1.734 mm on the test side (**Table 1**). The intergroup comparisons post surgically for both VPD and HPD were all statistically significant (**Table 1**)

The statistical intergroup comparisons of HAL and VAL were identical in the lines of intergroup comparison of VPD and HPD. For the control side the HAL reduced from 7.03 ± 1.217 mm to 4.86 ± 0.937 mm and VAL reduced from 5.30 ± 0.794 mm pre surgically to 3.13 ± 0.730 mm 6 months post surgically (**Table 1**). Similar readings were obtained on test side wherein the 6 months postsurgical measurements of HAL and VAL were 3.56 ± 0.568 mm and 2.46 ± 0.571 respectively (**Table 1**).

Discussion

One of the most potent challenges faced in management of periodontal disease is the management of furcation defects factored by both the diagnostic and therapeutic dilemmas. Several treatment approaches for management of Grade II furcation defects have been used with varying success.[14–16] Various studies over the years have evaluated regenerative therapies of furcation defects ranging from open flap debridement, placing only bone grafts all the way to use of GTR principles.[17] Kenney *et al.* in their study of Grade II furcation defects management proved that better results were obtained when HA was used as a grafting material.[18] Following the principles of GTR, various barrier membranes are being developed for being used in regenerative surgeries. Most of the studies so far have generally used collagen as a barrier membrane while treating furcation defects successfully.[14–16] However, keeping in view of certain complications encountered by the use of collagen membranes, search is on for newer materials to be used as barrier membranes. Among the latest materials being tried, PRF has all the ideal properties of being a good barrier membrane.

Even though PRF was successfully being used as membranes in various periodontal treatment procedures like gingival recession coverage, intrabony three walled defects, studies undertaken to assess the efficacy of using PRF as a GTR membrane in furcation defects are very few. This study was conducted based on the hypothesis that PRF when used as a barrier membrane along with the bone graft accentuates the regenerative potential at the surgical site. The objective was to find out the effectiveness PRF is an ideal barrier membrane and also to see if the PRF membrane really accentuated the regenerative healing capacity at the furcation defect. This study was conducted among a well-defined population and all patients consented to participate in the study. The subjects were randomly selected after assessing their systemic and periodontal condition. Patients with exposure to established risk factors like hypertension, smoking, systemic diseases and pregnant/lactating mothers were excluded thus eliminating any selection bias. To our knowledge, there is only one study reporting the successful use of autologous PRF as barrier membrane in the treatment of Grade II furcation defects.[19]

In this study, the PI, BI and GI reduced drastically post surgically and the intra group comparisons between pre surgical, 3 and 6 months postsurgical showed the parameters to be highly significant. These oral hygiene parameter results were expected as any periodontal treatment would reduce the load of local factors like plaque and calculus. The inter group comparisons for the same oral hygiene parameters were statistically insignificant at all the stages thus proving that the periodontal treatment provided on both the sides were effective in reducing the local factor load. The mean reduction in the clinical parameters during intragroup comparisons were noted to be highly significant for both the sides. These findings are in accordance with the results of the studies by Mehta[19] and Lekovic *et al.*[20], but the study conducted by Tsao *et al.*[4] which compared mineralized human cancellous bone allograft with and without collagen membrane, showed a higher vertical bone fill in the group treated with graft alone compared with the group treated using the combination. The intergroup comparison between the groups for clinical parameters at all the postsurgical stages were statistically significant thus giving us a clear picture that the treatment performed on the test side using a barrier membrane yielded much better results than the control side.

Regarding the use of IOPA radiographs, in some of the images it was not possible to detect significant radiographic changes in the furcation area as it was a two dimensional representation of a three dimensional object. However, in some of the test and control sites, mild radio opacity was seen at 6 months, which could be compatible with new bone growth. However, it is difficult to ascertain if regeneration or new bone growth has occurred, as it would require surgical reentry or histological evaluation. Thus in this study, keeping in mind all these limitations,

radiographic parameters will be considered only as an additional parameter. In this study no postoperative complications were noted. Post surgically, there was no recurrence of any features of periodontitis in any of our treated teeth, be it from the test group or the control side.

Conclusion

PRF membranes has been routinely used during sinus lift procedures. But, the ability of the PRF membrane to serve as an ideal GTR membrane especially in Grade II furcation is matter which needed investigation. It is in this context that the present study was undertaken.

Grade II furcation's were successfully managed in both the test and control groups resulting in improvement of oral hygiene parameters like GI, BI and PI as well as reduction in clinical parameters like VPD and HPD and improvement in HAL and VAL. However, treatment of Grade II furcations by using bone graft along with PRF membrane gave better results than by using the graft alone. Based on our observations in this study we can suggest that PRF has a good potential to be established as an ideal GTR membrane. Hence, this study recommends PRF to be used as a barrier membrane along with a graft material in management of Grade II furcations. Further studies are required to compare the PRF membrane with other resorbable membranes like collagen in order to evaluate whether the PRF barrier membrane is either inferior or superior to them. Even animal studies are also required for histological evaluation of periodontal regeneration after using PRF as a barrier membrane.

Acknowledgments: None

Conflict of interest: None

Financial support: Indian Army.

Ethics statement: None

References

1. Preeja C, Arun S. Platelet-rich fibrin: Its role in periodontal regeneration. *Saudi Dent J.* 2014;5 (2):117-22.
2. Sharma A, Pradeep AR. Autologous platelet-rich fibrin in the treatment of mandibular degree II furcation defects: A randomized clinical trial. *J Periodontol.* 2011;82 (10):1396-403.
3. Greenwell H, Committee on Research, Science and Therapy American Academy of Periodontology. Position paper: Guidelines for periodontal therapy. *J Periodontol.* 2001;72 (11):1624-8.
4. Tsao YP, Neiva R, Al-Shammari K, Oh TJ, Wang HL. Effects of a mineralized human cancellous bone allograft in regeneration of mandibular Class II furcation defects. *J Periodontol.* 2006;77 (3):416-25.
5. Lekovic V, Kenney EB, Carranza FA, Martignoni M. The use of autogenous periosteal grafts as barriers for the treatment of Class II furcation involvements in lower molars. *J Periodontol.* 1991;62 (12):775-80.
6. Lamb JW 3rd, Greenwell H, Drisko C, Henderson RD, Scheetz JP, Rebitski G. A comparison of porous and non-porous Teflon membranes plus demineralized freeze-dried bone allograft in the treatment of Class II buccal/lingual furcation defects: A clinical reentry study. *J Periodontol.* 2001;72 (11):1580-7.
7. Simionpietri JJ, Novaes AB Jr., Batista EL Jr., Filho EJ. Guided tissue regeneration associated with bovine-derived anorganic bone in mandibular Class II furcation defects. 6-month results at re-entry. *J Periodontol.* 2000;71 (6):904-11.
8. Choukroun J, Diss A, Simonpieri A, Girard MO, Schoeffler C, Dohan SL, et al. Platelet-rich fibrin (PRF): A second-generation platelet concentrate. Part IV: Clinical effects on tissue healing. *Oral Surg Oral Med Oral Pathol Oral Radiol Endod.* 2006;101 (3):e56-60.
9. Mazor Z, Horowitz RA, Del Corso M, Prasad HS, Rohrer MD, Dohan Ehrenfest DM. Sinus floor augmentation with simultaneous implant placement using Choukroun's platelet-rich fibrin as the sole grafting material: A radiologic and histologic study at 6 months. *J Periodontol.* 2009;80 (12):2056-64.
10. Simonpieri A, Del Corso M, Sammartino G, Dohan Ehrenfest DM. The relevance of Choukroun's platelet-rich fibrin and metronidazole during complex maxillary rehabilitations using bone allograft. Part I: A new grafting protocol. *Implant Dent.* 2009;18 (3):102-11.

11. Silness J, Loe H. Periodontal disease in pregnancy. II. Correlation between oral hygiene and periodontal condition. *Acta Odontol Scand.* 1964;22 (1):121-35.
12. Mühlemann HR, Son S. Gingival sulcus bleeding – A leading symptom in initial gingivitis. *Helv Odontol Acta.* 1971;15:107-13.
13. Loe H. The gingival index, the plaque index and the retention index systems. *J Periodontol.* 1967;38 (6):610-6.
14. Gantes B, Martin M, Garrett S, Egelberg J. Treatment of periodontal furcation defects. (II). Bone regeneration in mandibular Class II defects. *J Clin Periodontol.* 1988;15 (4):232-9.
15. Eto AL, Joly JC, Jeffcoat M, de Araújo NS, de Araújo VC, Cury PR. Use of anorganic bovine-derived hydroxyapatite matrix/cell-binding peptide (P-15) in the treatment of Class II furcation defects: A clinical and radiographic study in humans. *J Periodontol.* 2007;78 (12):2277-83.
16. Nyman S, Lindhe J, Karring T, Rylander H. New attachment following surgical treatment of human periodontal disease. *J Clin Periodontol.* 1982;9 (4):290-6.
17. Avila-Ortiz G, De Buitrago JG, Reddy MS. Periodontal regeneration – Furcation defects: A systematic review from the AAP regeneration workshop. *J Periodontol.* 2015;86:S108-30.
18. Kenney EB, Lekovic V, Elbaz JJ, Kovacic K, Carranza FA Jr., Takei HH. The use of a porous hydroxylapatite implant in periodontal defects. II. Treatment of Class II furcation lesions in lower molars. *J Periodontol.* 1988;59 (2):67-72.
19. Mehta DB, Deshpande NC, Dandekar SA. Comparative evaluation of platelet-rich fibrin membrane and collagen membrane along with demineralized freeze-dried bone allograft in Grade II furcation defects: A randomized controlled study. *J Indian Soc Periodontol.* 2018;22 (4):322-7.
20. Lekovic V, Kenney EB, Carranza FA Jr., Danilovic V. Treatment of Class II furcation defects using porous hydroxylapatite in conjunction with a polytetrafluoroethylene membrane. *J Periodontol.* 1990;61(9):575-8.