

CBCT-Based Comparison of Immediately Loaded Implants Placed in Immediate and Delayed Protocols

Erik M. Lund^{1*}, Jonas Lund¹, Karin W. Larsson¹

¹Department of Oral and Maxillofacial Sciences, School of Medicine and Dentistry, University of Copenhagen, Copenhagen, Sweden.

*E-mail ✉ erik.lund.implant@gmail.com

Received: 28 May 2023; Revised: 18 October 2023; Accepted: 24 October 2023

ABSTRACT

Conventionally, dental implants were placed several months after tooth extraction. Immediate implants were placed on the same day of extraction along with the conservation of the crestal bone. Immediate loading of implant facilitates immediate prosthetic reconstruction within 48 h of implant placement. In this study, both immediate and delayed implants were loaded immediately and their peri-implant bone loss, implant stability, and the soft-tissue outcomes around the implant were evaluated. Fourteen patients were included in this study, of which seven patients were under Group A (delayed) and seven patients were under Group B (immediate). The clinical evaluation was done at baseline, 3 months, and 6 months which includes plaque scores, bleeding on probing, and probing depth. Implant stability was tested by resonance frequency analyzer (implant stability quotient), and radiological evaluation of crestal bone loss was done by cone-beam computed tomography preoperatively and after 6 months. In this study, there was no statistically significant difference ($P > 0.05$) in the clinical parameters (plaque index, bleeding on probing, and probing depth) and radiological outcomes within the groups at baseline, 3 months, and 6 months. The implant stability quotient and crestal bone loss between Groups A and B showed a statistically significant difference at baseline and 6 months, wherein there were higher implant stability and decreased crestal bone loss in Group A when compared to Group B. Delayed implants with immediate loading were superior to immediate implants with immediate loading.

Keywords: Delayed implants, Immediate implants, Immediate loading, Implant stability quotient

How to Cite This Article: Lund EM, Lund J, Larsson KW. CBCT-Based Comparison of Immediately Loaded Implants Placed in Immediate and Delayed Protocols. *J Orthod Periodontal Biomater Res.* 2023;3(2):92-100. <https://doi.org/10.51847/Qz3z6T05Va>

Introduction

Tooth loss is one of the momentous concerns that disturbs the oral health of an individual. Dental implants contribute a contemporary role in replacing missing tooth in partially or completely edentulous area with discrete time of placement and loading protocols. In 1952, Branemark introduced the term osseointegration by placing titanium implants in bone. The authentic protocol proposed by Branemark for healing of implants was 6–8 months, which ensures a longer treatment period.

In general, after the extraction of tooth, alveolar bone loss occurs. Considerable animal and human studies have reported unavoidable occurrence of alveolar bone loss after tooth extraction [1]. To overcome this drawback, an immediate implant came into existence. In 1976, Schulte and Heimke explained the placement of immediate dental implants. Merits of immediate implant include simultaneous placement of an implant at the time of tooth extraction, elimination of surgical intercession, preservation of crestal bone loss and overall bone height, reduced alveolar bone resorption, and soft-tissue esthetics [2].

The time of implant loading is one of the important factors for implant success and survival. Archetypal implant loading protocols in the literature include 6–8 months in the maxilla and 3–4 months in the mandible [3]. Recently, various loading protocols have been included by shortening of the healing period that includes immediate loading (within 1 week of implant placement), early loading (1 week to 2 months), and conventional loading (after 2 months of implant placement) [4].

One more prime factor for long-term success of implant is the maintenance of healthy tissues around the implants. Subgingival plaque accumulation around the implant harbors pathogenic microorganisms and results in delayed soft-tissue healing and alveolar bone loss. If plaque accumulation persists, it can lead to bleeding on probing, increased peri-implant probing depth, peri-implantitis, and finally ends in failure of the implant. Possible causes of crestal bone loss around implants are local soft-tissue inflammation and mechanical stress acting on the crestal bone around the implant collar that often leads to increased chances of implant failure. However, one of the major disadvantages of immediate loading of the implant is the stress acting on the implant during healing, which may delay osseointegration.

Additional key factor in accomplishment of implant osseointegration is implant stability and it is measured in two stages: one at the time of implant placement (primary stability) due to the mechanical locking of implant with surrounding bone and another one (secondary stability) after the bone and tissue remodeling around the implant. The motive of this study is to evaluate the clinical outcomes of peri-implant soft tissues in terms of plaque scores, bleeding on probing and peri-implant probing depth, and primary and secondary stability in terms of implant stability quotient and radiographic outcomes of alveolar crestal bone loss (under cone-beam computed tomography [CBCT]) in delayed and immediate implant placement both under immediate loading.

Materials and Methods

The present study was approved by the institutional ethical review board of a public teaching hospital, and the study was conducted in accordance with the Helsinki Declaration of 1975, as revised in 2000. Fourteen patients were divided into two equal groups by simple randomization method (seven patients in Group A and seven patients in Group B) and were enrolled for the study. The sample size was calculated using G*Power software version 3.1.9.4. Assuming effect size of 1.7, $\alpha = 0.05$, and power = 0.80, a total of 14 participants (7 per group) were required to achieve a clinically meaningful difference between the groups. Systemically and periodontally healthy individuals from 18 years to 60 years in both the genders with single unit edentulous space were selected for the study. Vertical root fracture, endodontic failure, and nonrestorable caries were selected for placement of immediate implants after tooth extraction, and at least 4 mm of bone apical to the extraction socket should present. Systemically (diabetes mellitus/pregnancy) and periodontally (periodontitis/interproximal bone loss/narrow alveolar ridges/absence of buccal wall/periapical pathology) unhealthy individuals and patients with the habit of smoking were excluded from the study.

The clinical parameters such as plaque index, bleeding on probing, and probing pocket depth (millimeter) were evaluated at the time of placement, 3 and 6 months. Implant stability quotient (resonance frequency analyzer) and crestal bone loss (CBCT) were evaluated at the time of placement and after 6 months. An acrylic stent was specially prepared for the evaluation of crestal bone loss. To have a fixed reference point, 2 gutta-percha markers were incorporated into the acrylic stent. The gutta-percha markers are placed one at the mesial end and the other at the distal end in relation to the area of interest, to measure the distance from the base of the marker to the crest using CBCT at baseline and at 6 months after loading. Differences in these values will give the changes in bone level.

After preoperative clinical assessment and case selection, written informed consent regarding planned treatment was obtained from all the patients. The patients were advised to start antibiotics (amoxicillin – 500 mg thrice daily) 1 day before surgery and analgesic (ibuprofen 400 mg 1 h) preoperatively.

The surgical procedure for delayed implant placement (Group A) included the following. Under local anesthesia, after reflection of the mucoperiosteal flap, round bur was used to mark the osteotomy site using a surgical guide. Sequential drilling was done, and implant with desired diameter and length was placed. Care was taken to maintain a distance of approximately 2–3 mm between the implant shoulder and the adjacent teeth, and the implant was positioned 1 mm subcrestally. Subsequently, a compatible smart peg was placed on the implant, and using a resonance frequency analyzer, the implant stability quotient values were recorded- **Figure 1** (Group A) was

selected and adjusted onto the implant, the wound was closed by 4-0 black silk, and an impression was made for the fabrication of temporary restoration, which was delivered within 48 h.

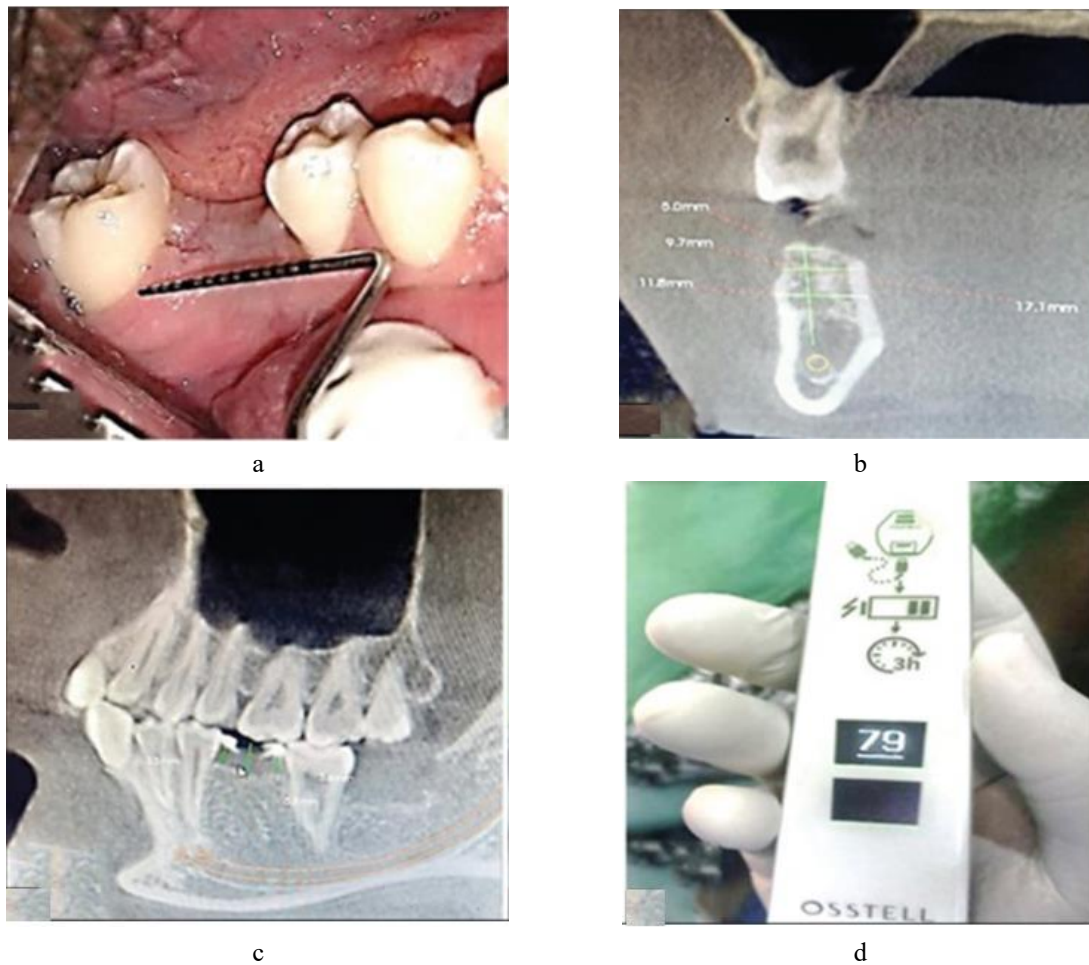


Figure 1: Group A – Preoperative: (a) Clinical photograph; (b) Cone-beam computed tomography (baseline); (c) Stent placement; (d) Implant stability quotient (baseline)

The surgical procedure for immediate implant placement (Group B) included the following. Under local anesthesia, atraumatic extraction of the tooth was done using peristomes to avoid damage to the surrounding alveolar bone. Once the tooth was removed, the socket was carefully debrided with curette and irrigated with saline. The socket wall was examined with a blunt instrument for any fenestration or fracture. Then, the drilling sequence was carried out in a sequential manner and the desired implant was placed (without a surgical guide). Care was taken to position the drill along the palatal or lingual wall of the extraction socket, with implant placement performed in the same manner as in Group A. Primary stability was achieved by placing the implant beyond the root apex to engage the socket wall, and subsequently, an appropriate smart peg was screwed onto the implant and stability was measured and recorded using a resonance frequency analyzer (**Figure 2**). A straight abutment was placed onto the implant, and the jumping space was filled with bone graft material if present. Suturing was done with 5-0 absorbable sutures, and temporary crown was placed over the abutment.

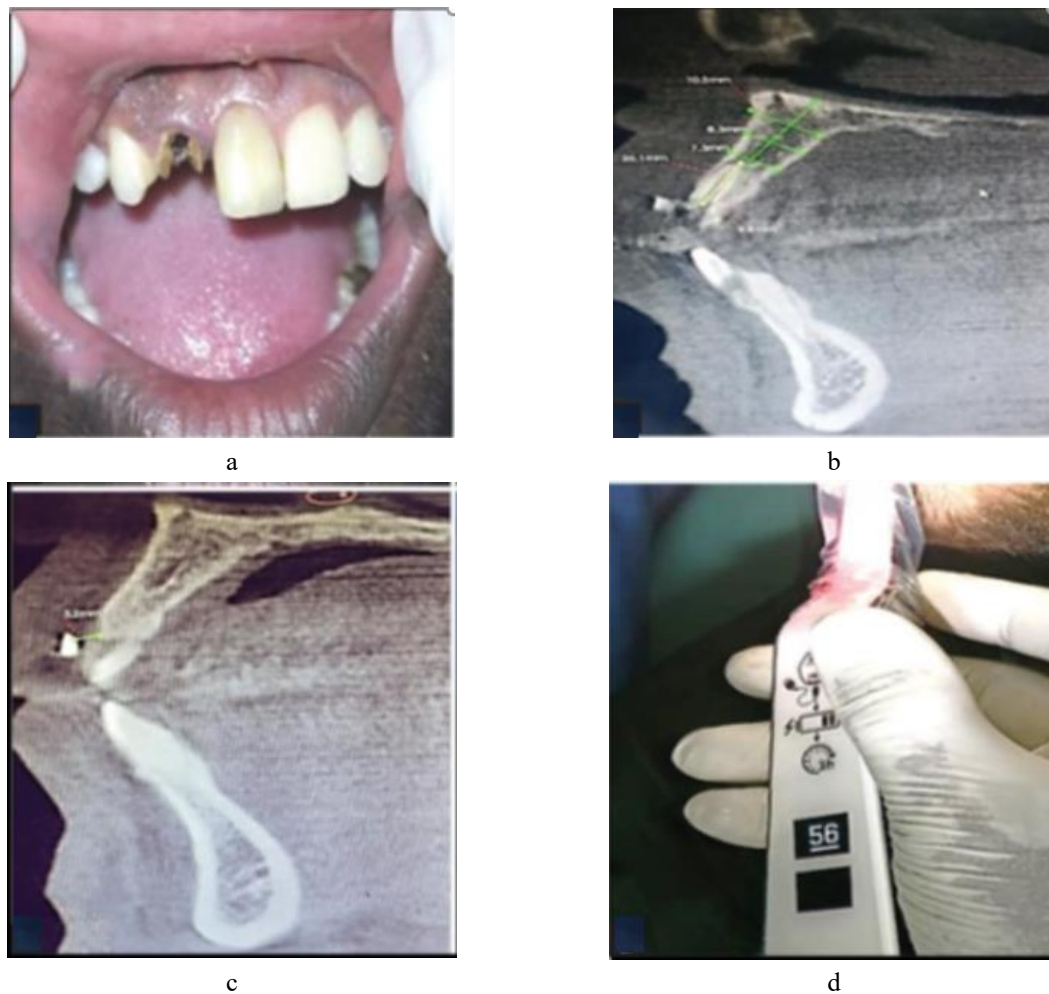

Figure 2: Group B – Preoperative: (a) Clinical photograph; (b) Cone-beam computed tomography (baseline); (c) Stent placement; (d) Implant stability quotient values (baseline)

Results and Discussion

Differential and inferential statistics were analyzed by IBM SPSS Ver 27.0 IBM Corp Released 2020. IBM SPSS Statistics for windows, Armonk, NY: IBM Corp). In the present study, all the 14 implants were osseointegrated. No early failures and complications were noted. The healing was uneventful. The patients showed good compliance and satisfaction as the tooth was replaced on the same day of surgery.

In plaque index, the intergroup values for mean plaque index score at 3 months for Group A and Group B were 0.714 ± 0.1345 and 0.729 ± 0.0951 , respectively. At 6 months, the mean plaque scores for Group A and Group B were 0.614 ± 0.1345 and 0.614 ± 0.0976 , respectively. The intergroup comparison showed that there is no significant difference in plaque index between the groups at 3 months and 6 months (**Table 1**).

Table 1: Intergroup comparison of plaque score, bleeding on probing, and probing pocket depth between Groups A and B

| Parameters | Timeline | Group A | Group B | t-test | P |
|--------------|----------|--------------------|----------------------|--------|-------|
| Plaque score | Baseline | 0.814 ± 0.1069 | 0.843 ± 0.0976 | -0.522 | 0.611 |
| | 3 months | 0.714 ± 0.1345 | 0.729 ± 0.0951 | -0.229 | 0.822 |
| | 6 months | 0.614 ± 0.1345 | 0.614 ± 0.0976 | 0.000 | 1.000 |
| Bleeding on | Baseline | 0 | 35.7143 ± 13.363 | -7.071 | 0.000 |

| | | | | | |
|---------------------|-----------------|---------------------|---------------------|---------------|--------------|
| probing | 3 months | 21.428±17.2516 | 10.7143±13.3630 | 1.299 | 0.218 |
| | 6 months | 14.2857±13.3630 | 7.1429±12.19875 | 1.044 | 0.317 |
| Probing | Baseline | 0 | 1.657±0.0976 | -44.927 | 0.000 |
| pocket depth | 3 months | 1.5514±0.21874 | 1.5857±0.10690 | -0.373 | 0.716 |
| | 6 months | 1.443±0.1397 | 1.543±0.1512 | -1.285 | 0.223 |

*Independent *t*-test; $P \leq 0.05$ is considered statistically significant, *P*-level of significance. Inference: There is no statistically significant difference

In terms of bleeding on probing, the intergroup values for mean bleeding on probing at 3 months for Group A and Group B were 21.428 ± 17.2516 and 10.7143 ± 13.3630 , respectively. At 6 months, the mean bleeding on probing for Group A and Group B was 14.2857 ± 13.3630 and 7.1429 ± 12.19875 , respectively. The intergroup comparison showed that there is no significant difference in bleeding on probing between the groups at 3 months and 6 months (**Table 1**).

Similarly, the intergroup values for mean implant probing depth at 3 months for Group A and Group B were 1.5514 ± 0.21874 and 1.5857 ± 0.10690 , respectively. At 6 months, the mean probing depth for Group A and Group B was 1.443 ± 0.1397 and 1.543 ± 0.1512 , respectively. The intergroup comparison showed that there is no significant difference in implant probing depth between the groups at 3 months and 6 months (**Table 1**).

In implant stability (implant stability quotient), the intergroup comparison test showed that there exists a high statistically significant difference ($P < 0.000$) between Groups A and B in both mesiodistal and buccolingual recordings at baseline and 6 months and demonstrated that Group A had better implant stability quotient values than Group B (**Table 2**). Changes in crestal bone loss are depicted by the intergroup comparison, which showed that there exists a high statistically significant difference ($P < 0.000$) between Groups A and B in relation to both mesial and distal markers at baseline and 6 months and demonstrated that Group A had lesser crestal bone loss than Group B (**Table 3**).

Table 2: Intergroup assessment of implant stability quotient between Groups A and B

| Parameters | Timeline | Group A (mean±SD) | Group B (mean±SD) | <i>t</i> -test | <i>P</i> |
|---------------------|-----------------|--------------------|--------------------|----------------|--------------|
| ISQ | Baseline | 75.57±3.259 | 60.14±8.971 | 4.277 | 0.001 |
| mesiodistal | 6 months | 76.43±3.552 | 65.71±7.064 | 2.328 | 0.041 |
| ISQ | Baseline | 72.00±6.298 | 62.14±9.263 | 3.585 | 0.006 |
| buccolingual | 6 months | 77.43±2.370 | 68.57±5.473 | 3.929 | 0.004 |

*Independent *t*-test; $P \leq 0.05$ is considered statistically significant; *P*-level of significance. Inference: There exists a statistically significant difference between Groups A and B in both mesiodistal and buccolingual sites at baseline and 6 months, which shows that Group A demonstrates better implant stability quotient values than Group B. SD – Standard deviation; ISQ – Implant stability quotient

Table 3: Intergroup assessment of crestal bone levels between Groups A and B

| Parameters | Timeline | Group A, (mean±SD) | Group B, (mean±SD) | <i>t</i> -test | <i>P</i> |
|----------------------|----------|--------------------|--------------------|----------------|----------|
| Mesial marker | Baseline | 2.514±0.8783 | 3.400±0.5802 | -2.226 | 0.049 |
| | 6 months | 3.571±0.8341 | 6.500±0.6928 | -0.876 | <0.001 |
| Distal marker | Baseline | 2.886±1.2747 | 3.371±0.7274 | -7.146 | 0.000 |
| | 6 months | 3.871±1.1221 | 6.429±0.9928 | -4.516 | 0.001 |

*Independent *t*-test; $P \leq 0.05$ is considered statistically significant, *P*-level of significance. Inference: There exists a statistically significant difference between Groups A and B in both mesial marker and distal marker at baseline and 6 months, which shows that Group A demonstrates lesser crestal bone loss than Group B. SD – Standard deviation

There was no statistically significant difference ($P > 0.05$) in the clinical and radiological outcomes within the groups at baseline, 3 months, and 6 months.

Current dental conventions place a strong emphasis on different implant-rehabilitation regimens to meet patients' ever-increasing demands for treatment duration, convenience, and esthetics. According to conventional procedures, implants were supposed to osseointegrate for 3–8 months without any loading [3-6]. Updated protocols stress that implants could be loaded early, perhaps immediately, prior to full osseointegration, to minimize the healing period.

When an implant can be placed with a torque value of 30–40 Ncm or more and the computerized tomography properly measures the quality of the bone at the implant site, implants can be loaded immediately. Resonance frequency analysis can be used to determine the implant's stability in terms of the implant stability quotient, which measures the implant's firmness within the bone [7, 8]. Implant success can be achieved with implant stability quotient levels between 55 and 80 [9].

The goal of the current study was to assess the initial loading of implants placed using two different techniques over a 6-month period. While the second approach (Group B) involves immediate loading of implants in a new extraction socket (immediate implants), the first method (Group A) involves immediate loading of implants in healed sites (traditional delayed implants).

At baseline, 3 months, and 6 months into the trial, there was no statistically significant difference ($P > 0.05$) in the mean plaque scores between the two groups. This demonstrated the patients' continued practice of proper dental hygiene. The results of Weber *et al.* [10] Renvert *et al.* [11] and Parvini *et al.* (2023) were consistent with this outcome [12].

In addition, from baseline to 6 months, this study demonstrated a considerable reduction in bleeding on probing in Group B. Probing revealed no discernible difference in bleeding between the two groups. These results were in line with the findings of Cosyn *et al.* [13] who conducted a 3-year study examining the hard- and soft-tissue response in immediate implants and found that bleeding on probing decreased significantly from 41% to 24% over the course of the study. These outcomes also lined up with the findings of Bhutani *et al.* (2021) [14].

From baseline to 6 months, Group A's peri-implant probing depth significantly decreased. Peri-implant probing depth did not significantly differ between the two groups. The results of this investigation were in line with those of DeAngelo *et al.* [15] who demonstrated statistically significant mean probing depth in delayed implants throughout a range of time periods. Conversely, Schou *et al.* [16] and Al-Ahmari [17] did not discover any appreciable decrease in the depth of peri-implant probing in delayed implants.

Regarding the implant stability quotient values between Groups A and B at baseline (primary stability) and 6 months later (secondary stability), statistically significant results ($P < 0.000$) (**Figures 3 and 4**) were achieved. As a result, compared to immediate implants with immediate loading, delayed implants with immediate loading demonstrated superior primary and secondary stability. The results of Cannizzaro *et al.* [18] and Stanley *et al.* [19] who discovered improved primary and secondary stability in delayed implants with immediate loading, are consistent with the current investigation. These results contrasted with those of Naeem and Al-Jumaily, [20] who discovered that immediate implants with immediate loading had improved primary and secondary stability.

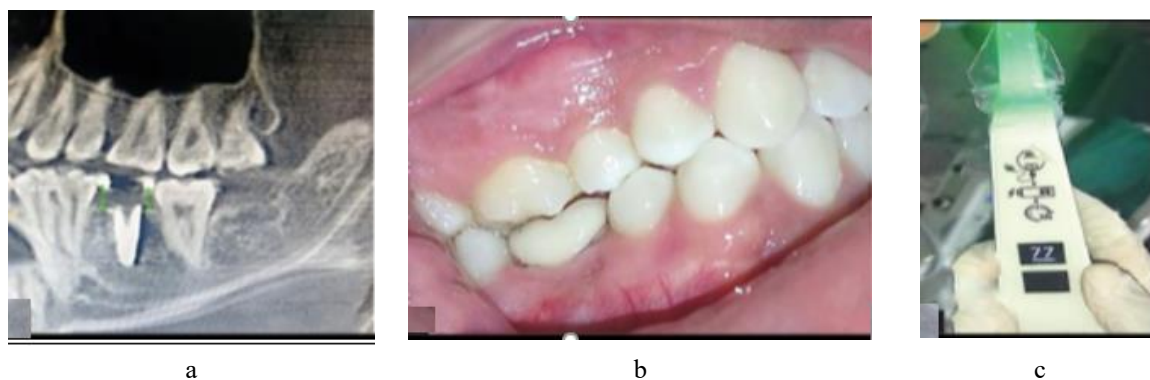


Figure 3: Group A – Postoperative: (a) Cone-beam computed tomography (after 6 months); (b) Clinical photograph; (c) Implant stability quotient (after 6 months)

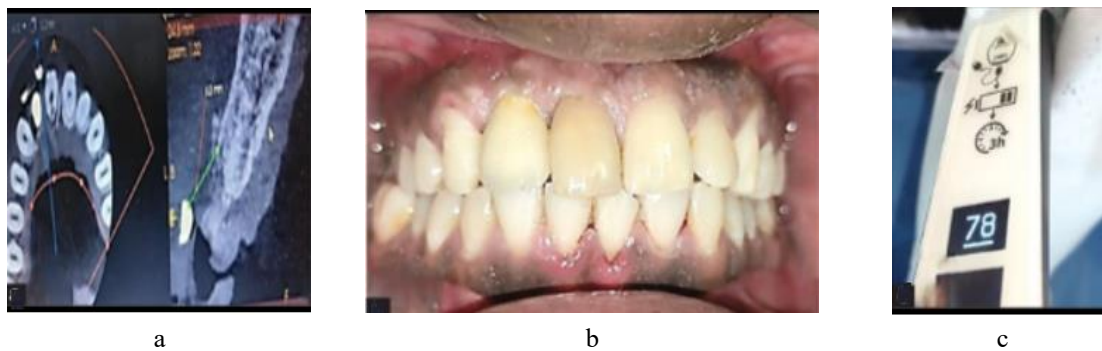

Figure 4: Group B – Postoperative: (a) Cone-beam computed tomography (after 6 months); (b) Clinical photograph; (c) Implant stability quotient (after 6 months)

From baseline to 6 months, the mean values of crestal bone loss (both mesial and distal markers) were significant and showed that delayed implants under immediate loading experienced less crestal bone loss than instantaneous implants under immediate loading. These findings were consistent with those of Chaushu *et al.* [21] who examined the clinical effectiveness of loading implants right away in newly extracted sites versus healed sites and found that doing so exhibited a 20% chance of implant failure. This study coincided with the findings of den Hartog *et al.* [22] Mangano *et al.* [23] and Keshari *et al.* [24] which supported quick loading of a single implant as a successful and safe operation and reported less marginal bone loss. These results contrast with those of Pitman *et al.* [25] who discovered no discernible variation in crestal bone loss between immediate implant loading and traditional loading.

Conclusion

During 6 months, the current study assessed and contrasted the clinical and radiological results of immediate and delayed implants that were both loaded immediately. At baseline, 3 months, and 6 months, clinical measures such as the plaque index, bleeding on probing, and probing pocket depth surrounding the implant were assessed. Using a resonance frequency analyzer, the primary and secondary stability of the implants was evaluated both at the beginning of the surgical process and 6 months later. CBCT was used to assess changes in the crestal bone at baseline and 6 months afterward.

In contrast, the clinical and radiological results of the delayed implants with immediate loading were superior. When an implant was delayed and loaded immediately, primary and secondary stability was significantly higher than when an implant was loaded immediately. Compared to an immediate implant with immediate loading, there was less crestal bone loss in the delayed implant. After 6 months, the final restoration was completed with appropriate assessments of several hard- and soft-tissue parameters for increased success.

Within the constraints of this investigation, immediate loading on delayed implants was found to be superior to immediate loading on immediate implants. For long-term success, careful preparation along with the best surgical regimen is advised. For more verified results, more research with a sizable sample size and extended follow-up is advised.

Acknowledgments: The authors appreciate the clinical contribution from Dr. A. J. Anand, Dr. P. R. Ganesh, Dr. D. Jayanthi, and Dr. P. Sivasankar. The authors appreciate the research analysis from Dr. Nandhini. The authors have no conflict of interest in this study.

Conflict of interest: None

Financial support: None

Ethics statement: None

References

1. Araújo MG, Lindhe J. Dimensional ridge alterations following tooth extraction. An experimental study in the dog. *J Clin Periodontol.* 2005;32(3):212–18.
2. Chen ST, Wilson TG Jr., Hämmerle CH. Immediate or early placement of implants following tooth extraction: Review of biologic basis, clinical procedures, and outcomes. *Int J Oral Maxillofac Implants.* 2004;19(Suppl):12–25.
3. Brånemark PI. Osseointegration and its experimental background. *J Prosthet Dent.* 1983;50(3):399–410.
4. Esposito M, Grusovin MG, Willings M, Coulthard P, Worthington HV. The effectiveness of immediate, early, and conventional loading of dental implants: A Cochrane systematic review of randomized controlled clinical trials. *Int J Oral Maxillofac Implants.* 2007;22(6):893–904.
5. Albrektsson T, Brånemark PI, Hansson HA, Lindström J. Osseointegrated titanium implants. Requirements for ensuring a long-lasting, direct bone-to-implant anchorage in man. *Acta Orthop Scand.* 1981;52(2):155–70.
6. Milillo L, Fiandaca C, Giannoulis F, Ottria L, Lucchese A, Silvestre F, et al. Immediate versus non-immediate loading post-extractive implants: A comparative study of implant stability quotient (ISQ). *Oral Implantol (Rome).* 2016;9(3):123–31.
7. Hui E, Chow J, Li D, Liu J, Wat P, Law H. Immediate provisional for single-tooth implant replacement with Brånemark system: Preliminary report. *Clin Implant Dent Relat Res.* 2001;3(2):79–86.
8. Ertugrul AS, Tekin Y, Alpaslan NZ, Bozoglan A, Sahin H, Dikilitas A. Comparison of peri-implant crevicular fluid levels of adrenomedullin and human beta defensins 1 and 2 from mandibular implants with different implant stability quotient levels in nonsmoker patients. *J Periodontol Res.* 2014;49(4):480–88.
9. Ramakrishna R, Nayar S. Clinical assessment of primary stability of endosseous implants placed in the incisor region, using resonance frequency analysis methodology: An in vivo study. *Indian J Dent Res.* 2007;18(4):168–72.
10. Weber HP, Crohin CC, Fiorellini JP. A 5-year prospective clinical and radiographic study of non-submerged dental implants. *Clin Oral Implants Res.* 2000;11(2):144–53.
11. Renvert S, Samuelsson E, Lindahl C, Persson GR. Mechanical non-surgical treatment of peri-implantitis: A double-blind randomized longitudinal clinical study. I: Clinical results. *J Clin Periodontol.* 2009;36(7):604–09.
12. Parvini P, Trimou G, Begic A, Cafferata EA, Petsos H, Müller KM, et al. Esthetic and clinical outcomes after immediate placement and restoration: Comparison of two implant systems in the anterior maxilla—A cross-sectional study. *Clin Implant Dent Relat Res.* 2023;25(2):252–60.
13. Cosyn J, Eghbali A, De Bruyn H, Collys K, Cleymaet R, De Rouck T. Immediate single-tooth implants in the anterior maxilla: 3-year results of a case series on hard and soft tissue response and aesthetics. *J Clin Periodontol.* 2011;38(8):746–53.
14. Bhutani N, Fatima G, Rampure N, Tapashetti R, Prabhu SS, Rahman F. Esthetic evaluation of maxillary anterior immediate implant with provisionalization with or without bone grafting. *J Contemp Dent Pract.* 2021;22(10):1105–12.
15. DeAngelo SJ, Kumar PS, Beck FM, Tatakis DN, Leblebicioglu B. Early soft tissue healing around one-stage dental implants: clinical and microbiologic parameters. *J Periodontol.* 2007;78(10):1878–86.
16. Schou S, Holmstrup P, Stoltze K, Hjørting-Hansen E, Fiehn NE, Skovgaard LT. Probing around implants and teeth with healthy or inflamed peri-implant mucosa/gingiva: A histologic comparison in cynomolgus monkeys. *Clin Oral Implants Res.* 2002;13(2):113–26.
17. Al-Ahmari MM. Estimation of soft and hard tissue revolutionization surrounding dental implant: A 2-year retrospective study. *J Healthc Eng.* 2022;2022:1540668.
18. Cannizzaro G, Leone M, Consolo U, Ferri V, Esposito M. Immediate functional loading of implants placed with flapless surgery versus conventional implants in partially edentulous patients: A 3-year randomized controlled clinical trial. *Int J Oral Maxillofac Implants.* 2008;23(4):867–75.
19. Stanley M, Braga FC, Jordao BM. Immediate loading of single implants in the anterior maxilla: A 1-year prospective clinical study on 34 patients. *Int J Dent.* 2017;2017:1–11.
20. Naeem DM, Al-Jumaily HA. Can immediate implantation with immediate loading achieve an acceptable esthetic outcome? A prospective observational clinical study. *J Craniofac Surg.* 2023;34(1):e79–84.

21. Chaushu G, Chaushu S, Tzohar A, Dayan D. Immediate loading of single-tooth implants: immediate versus non-immediate implantation. *Int J Oral Maxillofac Implants.* 2001;16(2):267–72.
22. den Hartog L, Raghoobar GM, Stellingsma K, Vissink A, Meijer HJ. Immediate loading of anterior single-tooth implants placed in healed sites: five-year results of a randomized clinical trial. *Int J Prosthodont.* 2016;29(6):584–91.
23. Mangano C, Raes F, Lenzi C, Eccellente T, Ortolani M, Luongo G, et al. Immediate loading of single implants: A 2-year prospective multicenter study. *Int J Periodontics Restorative Dent.* 2017;37(1):69–78.
24. Keshari R, Chand P, Singh BP, Jurel SK, Singh R, Singh PK, et al. Comparison of crestal bone loss and osteocalcin release kinetics in immediately and delayed loaded implants: A randomized controlled trial. *J Prosthodont.* 2022;31(6):579–84.
25. Pitman J, Seyssens L, Christiaens V, Cosyn J. Immediate implant placement with or without immediate provisionalization: A systematic review and meta-analysis. *J Clin Periodontol.* 2022;49(10):1012–23.